

CASE REPORT

Mediastinal lymphoma-induced superior vena cava syndrome and chylopericardium in a pregnant lady: a case report

Omar S. Obeidat¹, Bayan A. Baniissa², Zakaria W. Shkoukani³, Abdullah N. Alhour³

¹Division of Cardiology, Department of Internal Medicine, Jordan University Hospital, ²Department of Internal Medicine, University of Jordan Hospital, ³Department of Internal Medicine, University of Jordan, Amman, Jordan

Access this article online

Website: www.avicennajmed.com

DOI: 10.4103/ajm.ajm_51_19

Quick Response Code:



ABSTRACT

Mediastinal malignancies are a commonly identified etiology in superior vena cava syndrome (SVCS), and despite the known management of chemotherapy, radiotherapy, or a combination of both, this can prove to be a dilemma during pregnancy. Reported cases of SVCS management during pregnancy are scarce. Chylopericardium is a rare entity with a myriad of causes, the most common of which is a primary idiopathic origin. Initial management depends on the presence or absence of cardiac tamponade. Long-term therapy is a matter of serious debate, with some opting for conservative treatment, and others favoring a more invasive surgical approach. Cases reporting the occurrence of chylopericardium in association with pregnancy are also limited. In this report, we discuss the case of a 28-year-old pregnant woman who had both SVCS and chylopericardium as a result of a mediastinal lymphoma.

Key words: Chyle, chylopericardium, lymphoma, mediastinum, pregnancy, superior vena cava syndrome, tamponade

INTRODUCTION

Superior vena cava syndrome (SVCS) is a condition characterized by compression of the superior vena cava (SVC) causing a constellation of classical signs and symptoms.^[1] Chylopericardium is a rare condition first reported by Hasebroek in 1888, whereby the pericardial sac is filled with considerable quantities of chylous fluid. It can be of primary (idiopathic) or secondary etiology.^[2] To the best of our knowledge and after extensive literature review, we found that cases reporting SVCS and chylopericardium during pregnancy are scarce. We herein report a case of a 28-year-old pregnant woman who presented with both conditions during her peripartum period, secondary to a mediastinal lymphoma.

CASE PRESENTATION

A 28-year-old, 31-week pregnant woman, G3P1 + 1 miscarriage, presented to the obstetrics clinic. She

complained of swelling of the neck, face, chest, and upper limbs; shortness of breath; dizziness; headache; and coughing. Physical examination revealed edema of the face, neck, and upper limbs, and large distended veins across the chest. She was found to have cervical, supraclavicular, and bilateral axillary lymph node enlargements, and decreased air entry bilaterally. Pemberton's sign was positive. She was admitted for evaluation. Her chest radiograph revealed a large ill-defined mediastinal mass inseparable from the cardiac silhouette [Figure 1]. Urgent computed tomography (CT) of chest showed extensively enlarged, matted mediastinal, bilateral hilar, and supraclavicular

This is an open access journal, and articles are distributed under the terms of the Creative Commons Attribution-NonCommercial-ShareAlike 4.0 License, which allows others to remix, tweak, and build upon the work non-commercially, as long as appropriate credit is given and the new creations are licensed under the identical terms.

For reprints contact: reprints@medknow.com

Cite this article as: Obeidat OS, Baniissa BA, Shkoukani ZW, Alhour AN. Mediastinal lymphoma-induced superior vena cava syndrome and chylopericardium in a pregnant lady: A case report. *Avicenna J Med* 2020;10:89-92.

Address for correspondence: Dr. Abdullah N. Alhour, Dawoud Alqura'an Street, Amman, Jordan.
E-mail: abdallahouri1995@hotmail.com

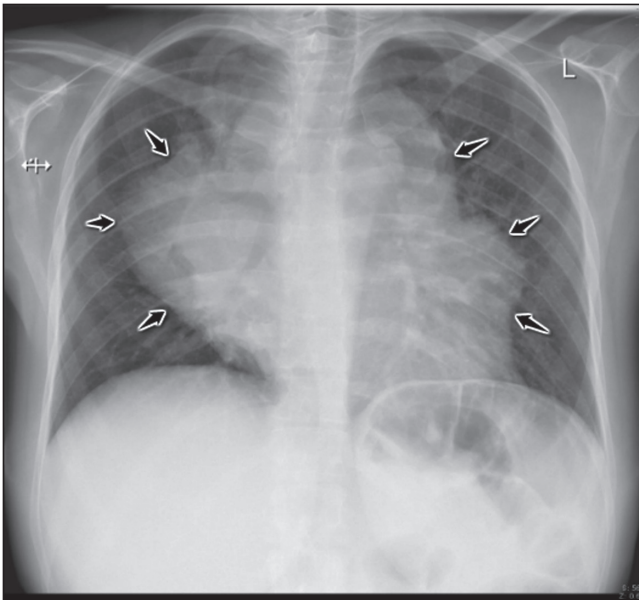


Figure 1: Chest radiographs showing a large ill-defined mediastinal mass inseparable from the cardiac silhouette (black arrows), posteroanterior view

lymph nodes with necrotic centers [Figure 2A–E]. These enlarged lymph nodes were exerting pressure on the carina, proximal main bronchi, and the SVC.

After evaluation by hematology, a preliminary diagnosis of SVCS due to suspected lymphoma was made, and the patient was treated with empirical chemotherapy (vincristine 2 mg intravenous over 24 h) to help relieve symptoms. Tru-cut biopsy of the mediastinal lymph nodes was then performed. Another dose of chemotherapy was administered the following week, and the patient dramatically improved. Following symptom resolution, she underwent C-section delivery during her 33rd week. The patient and the newborn had an uncomplicated delivery and postpartum course. She was discharged 4 days later awaiting biopsy results, which later confirmed the diagnosis of large B cell lymphoma (non-germinal center subtype). Staging then followed.

Two days following diagnosis, the patient returned to the emergency department (ED) with the classical Beck's triad: low blood pressure, muffled heart sounds, and elevated jugular venous pressure (JVP). Emergent pericardiocentesis was performed for cardiac tamponade, and a milky effusion was aspirated. Fluid analysis was found to be of chylous origin: triglycerides (782 mg/dL), negative fluid cultures, and lymphocytic predominance confirmed the diagnosis of chylopericardium (white blood cell [WBC]: 1280 cell/ μ L [polymorphonuclear leukocyte: 25%, lymphocyte: 75%], red blood cell [RBC]: 1600 cell/ μ L, protein: 3.3 g/dL, and glucose: 81 mg/dL). Aspiration of the pericardial fluid instantly stabilized the patient's condition. Two days after discharge, she returned to the ED with a similar complaint, this time

undergoing surgical pericardial window. Pericardial biopsy showed no malignant invasion. The patient was discharged and treatment for lymphoma was commenced. Most recent follow-up with her cardiologist revealed no new fluid accumulations or signs of constrictive pericarditis.

DISCUSSION

The SVC directs blood from the head, neck, chest, and upper extremities toward the heart, representing one-third of the total venous return. Any cause of compression to this vessel will lead to a decrease in cardiac output and venous congestion leading to the symptoms and signs of SVCS.^[1] In the past, the most common cause of SVCS was infection (e.g., syphilis and tuberculosis). However, nowadays, mediastinal malignancies account for over 60% of all SVCS cases.^[1] Other less common causes of SVCS include thrombosis associated with different intravascular devices (catheters, pacemakers, etc.), fibrosing mediastinitis, postradiation fibrosis, and vasculitic disorders such as Behçet disease.^[1] The disease commonly manifests as swelling of the head, neck, eyelids, torso, arms, visibly dilated veins, cyanosis, plethora, hoarseness of voice, coughing, and difficulty breathing and swallowing, and in severe cases dizziness and coma due to cerebral edema.^[3] Diagnosis of the condition is clinical, although CT imaging is frequently used. Treatment is tailored to the etiology; in case of mediastinal tumors, most patients respond to radiotherapy, chemotherapy, or a combination of both.^[1] As the patient in this report was having SVCS due to compression by a mediastinal lymphoma, chemotherapy proved to be effective in treating her condition. Despite the dilemma of the ethical use of chemotherapy during pregnancy, various studies have shown success in using chemotherapy intrapartum with no reports of postpartum complications for neither infant nor mother, hence warranting our chosen method of management.^[4-7]

Normally, the pericardium contains up to 50 mL serous fluid, which circulates by being drained into the left subclavian vein through the mediastinal lymphatic vessels, nodes, and thoracic duct.^[2] If for any reason, obstruction occurs at any of the aforementioned levels, fluid will begin to accumulate around the heart leading to chylopericardium.^[8] It is a very rare condition where only 104 cases have been reported worldwide as per a review conducted by Yu *et al.* in 2018.^[9] The condition can be of either primary (idiopathic) or secondary origin, with the former being the most common (56%).^[2] Secondary causes include iatrogenic after cardiac surgery, gastric signet cell carcinoma, Gorham's syndrome, malignancies, blunt and/or penetrating trauma, and infections.^[10] The accumulation of chylous fluid around the heart causes compression, impacting the normal pumping function of the heart and leading to

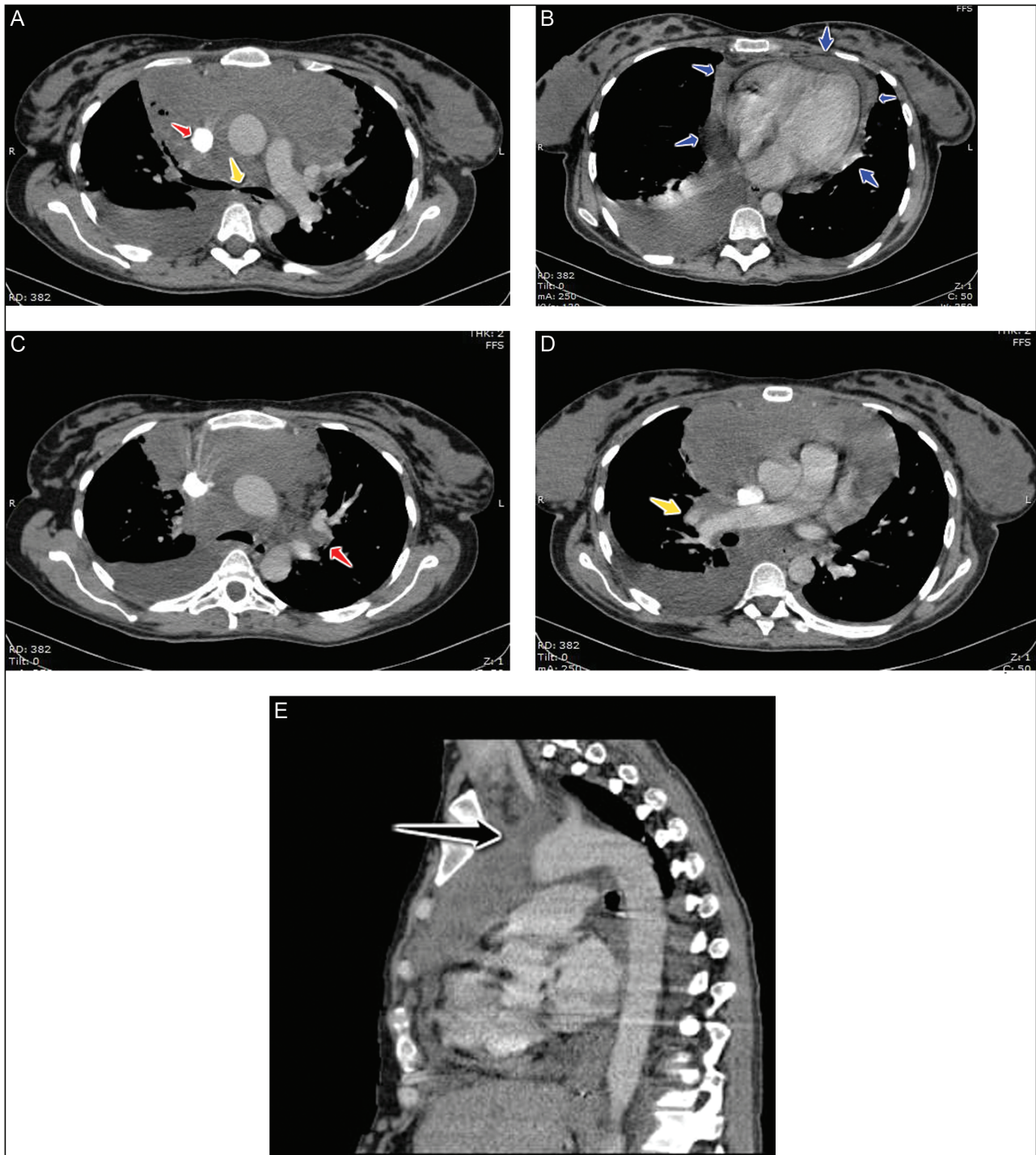


Figure 2: (A) Axial view of computed tomography showing extensively enlarged lymph nodes exerting pressure on the carina (yellow arrow) and the superior vena cava (red arrow). (B) Axial view of computed tomography showing a large pericardial effusion (blue arrows). (C) Axial view of computed tomography showing enlarged left (red arrow) hilar lymph nodes, which appear matted together. (D) Axial view of computed tomography showing enlarged right (yellow arrow) hilar lymph nodes, which appear matted together. (E) Sagittal view of computed tomography showing extensively enlarged matted superior mediastinal lymph nodes (black arrow)

cardiac tamponade. This is reflected clinically by Beck's triad: hypotension, distant heart sounds, and elevated JVP. However, it is important to note that this triad is only reported to be present in approximately 22%–32% of patients, with the most common presenting symptom being the shortness of

breath (44.2%). A significant number (39.4%) of patients were asymptomatic on diagnosis.^[9] Diagnosis of chylopericardium generally involves clinical suspicion along with a chest radiograph, chest CT, and a diagnostic pericardiocentesis with fluid analysis.^[9]

Management of the condition involves aspiration of fluid for symptomatic relief, followed by either conservative or surgical approaches. Conservative management encompasses total parenteral nutrition, low-fat diet, and medium-chain triglycerides. Yu *et al.*^[9] stated that 58% of the cases in their review treated with conservative management did not improve and were followed by surgery. Surgical management, on the contrary, pericardial windowing with ligation of the thoracic duct in approximation to the diaphragm preventing reflux through collaterals, was successful in all cases. Other less common treatment modalities include octreotide administration and thoracic duct embolization, among others.^[8] In this report, pericardiocentesis with subsequent pericardial windowing was sufficient to treat the patient's condition. The most feared long-term complication of chylopericardium is constrictive pericarditis, warranting close follow-up.^[2]

CONCLUSION

SVCS due to lymphoma during pregnancy is a rare entity. It can be treated urgently with certain chemotherapy, if required. Chylopericardium is also a rare entity, even more so in the peripartum period, with only few previous reports of a similar presentation. However, if the diagnosis is made early and managed correctly, fatal complications can be avoided.

Financial support and sponsorship

Nil.

Conflicts of interest

There are no conflicts of interest.

REFERENCES

1. Lepper PM, Ott SR, Hoppe H, Schumann C, Stammberger U, Bugalho A, *et al.* Superior vena cava syndrome in thoracic malignancies. *Respir Care* 2011;56:653-66.
2. Dib C, Tajik AJ, Park S, Kheir ME, Khandieria B, Mookadam F. Chylopericardium in adults: A literature review over the past decade (1996–2006). *J Thorac Cardiovasc Surg* 2008;136:650-6.
3. Landy HJ, Nguyen M, Tsou E. Superior vena cava syndrome in pregnancy. A case report. *J Reprod Med* 2003;48:299-301.
4. Goldwasser F, Pico JL, Cerrina J, Fernandez H, Pons JC, Cosset JM, *et al.* Successful chemotherapy including epirubicin in a pregnant non-Hodgkin's lymphoma patient. *Leuk Lymphoma* 1995;20:173-6.
5. Djakovic A, Ott G, Zollner U, Vordermark D, Dietl J. [Mediastinal large B-cell lymphoma with symptomatic superior vena cava syndrome in a patient with bichorial twin pregnancy in the 26th week of gestation: Peri- and postpartal management—A case report]. *Zentralbl Gynakol* 2005;127:248-51.
6. Vandembriele C, Dierickx D, Amant F, Delforge M. The treatment of hematologic malignancies in pregnancy. *Facts Views Vis Obgyn* 2010;2:74-87.
7. Framarino-Dei-Malatesta M, Sammartino P, Napoli A. Does anthracycline-based chemotherapy in pregnant women with cancer offer safe cardiac and neurodevelopmental outcomes for the developing fetus? *BMC Cancer* 2017;17:777.
8. Rafiq MU, Ali J, Saad H, Wilson S, Van Tornout F. Management of idiopathic chylopericardium in pregnant patient. *Asian Cardiovasc Thorac Ann* 2016;24:798-800.
9. Yu X, Jia N, Ye S, Zhou M, Liu D. Primary chylopericardium: A case report and literature review. *Exp Ther Med* 2018;15:419-25.
10. Tan JX, Fu Y, Chen J. Primary idiopathic chylopericardium: A case report. *Cardiol Young* 2013;23:773-5.