

Intravascular lithotripsy to treat an underexpanded coronary stent during index procedure: A case report study

Sherif Seif^{1,2}, Abhishek Kumar², Sanjay Arya², Vellore J. Karthikeyan²

¹Cardiology Department, Faculty of Medicine, Tanta University, Tanta, Egypt, ²Cardiology Department, Royal Albert Edward Infirmary, Warrington, Wigan and Leigh NHS Foundation Trust, Wigan, United Kingdom

Access this article online

Website: www.avicennajmed.com

DOI: 10.4103/ajm.ajm_200_20

Quick Response Code:



ABSTRACT

Management of heavily calcified lesions during percutaneous coronary intervention (PCI) is often associated with high incidence of complications and long-term adverse outcomes. There is growing evidence of the efficacy of intravascular lithotripsy (IVL) in de novo coronary lesion preparation; however, little experience has been documented within freshly deployed stent underexpansion. We report a 66-year-old male with a marked stent underexpansion despite extensive lesion preparation due to severe underlying calcification. The stent was resistant to balloon postdilatation; therefore, IVL was applied, resulting in excellent stent expansion. IVL could be considered for treating acute stent underexpansion caused by severe underlying calcification.

Key Words: Calcified coronary lesions, complication, coronary artery disease, intravascular lithotripsy, percutaneous coronary intervention, stent underexpansion, stents

INTRODUCTION

Management of heavily calcified lesions during percutaneous coronary intervention (PCI) is often associated with a high incidence of complications and long-term adverse outcomes.^[1] IVL is a novel promising technique for management of intracoronary calcification by using high-energy sonic waves to modify calcified lesions.^[2] However, little experience has been documented within stent underexpansion. We present a case of severe stent underexpansion due to tight underlying calcifications that was successfully managed on the same session by IVL.

CASE REPORT

A 66-year-old male patient presented to our Cath Lab for coronary angiography after having a positive dobutamine stress ECHO scan (large area of ischemia on the left anterior

descending (LAD) artery territory with underlying good left ventricular systolic function). He had a past history of hypertension and hypercholesterolemia.

Coronary angiography [Figure 1] showed a severe lesion in the proximal LAD artery with mild plaques in other coronaries. Therefore, a decision was made to proceed with stenting of the proximal LAD.

Using a right radial approach, the left main stem was cannulated by using a 6F Q4 guide catheter and an ASAHI SION blue guidewire was advanced into the distal LAD. The lesion was predilated with 2.5-mm and 3.0-mm noncompliant (NC) balloons; then, it was stented with a

This is an open access journal, and articles are distributed under the terms of the Creative Commons Attribution-NonCommercial-ShareAlike 4.0 License, which allows others to remix, tweak, and build upon the work non-commercially, as long as appropriate credit is given and the new creations are licensed under the identical terms.

For reprints contact: reprints@medknow.com

Cite this article as: Seif S, Kumar A, Arya S, Karthikeyan VJ. intravascular lithotripsy to treat an underexpanded coronary stent during index procedure: A case report study. *Avicenna J Med* 2021;11:54-7.

*Case was performed at Royal Albert Edward infirmary

Address for correspondence: Dr. Sherif Seif,
Royal Albert Edward Infirmary, Wigan Lane,
Wigan WN1 2NN, United Kingdom.
E-mail: Sherif.Seif@med.tanta.edu.eg

3.5 × 20 mm Supraflex Cruz stent [Figure 1]. However, during stent optimization, there was an initial difficulty to cross through the middle portion of the stent with a 3.75 × 10 mm NC balloon, but after several attempts and with the help of a balance heavy weight guidewire the balloon was placed in the middle of the stent and inflated multiple times up to 18 atmospheres (ATM). Despite repeated postdilations of this mid-stent segment [Figure 1], there was a persistent waist of the balloon and the CLEARstent tool illustrated a severely underexpanded stent. Optical coherence tomography (OCT) revealed a marked stent

underexpansion (minimal luminal area (MLA) 1.0 mm²) due to a thick circumferential layer of calcium just deep to the stent [Figure 1].

Super high-pressure non-compliant balloon (OPN NC) was initially considered for further postdilation, but due to high risk of perforation a decision was to try an alternative method. Despite the little documented experience regarding the use of IVL within stent underexpansion as well as the concerns about a potential adverse interaction between IVL and recently implanted stents, we decided to proceed

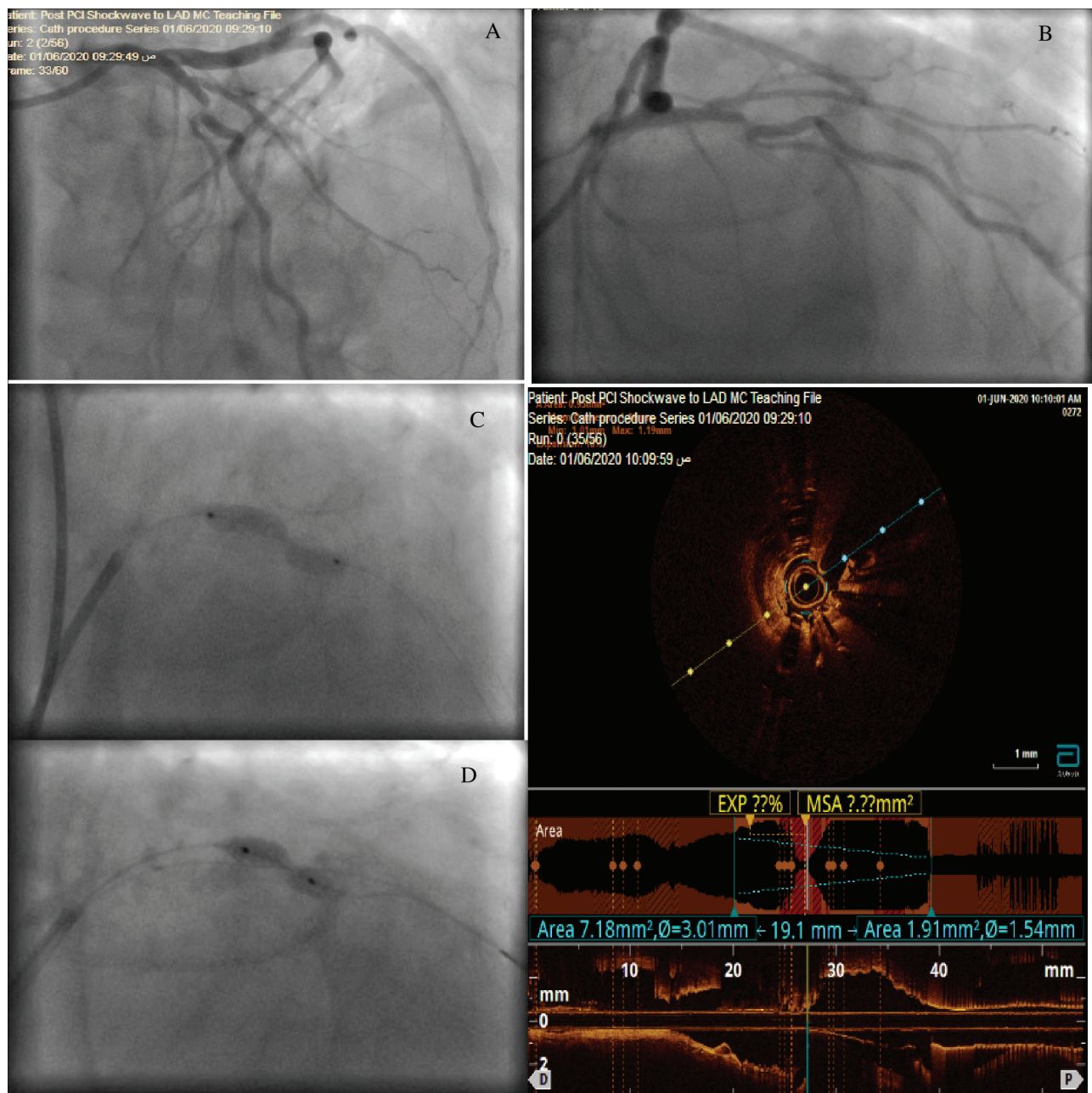


Figure 1: (A,B) Baseline angiographic views of LAD showing a severe proximal LAD lesion. (C) Stent inflation showing mid-portion severe underexpansion. (D) Stent postdilatation showing “dog-boning” effect of balloon. (E) Optical coherence tomography run showing a severe underexpanded stent with circumferential calcification. LAD, left anterior descending

with IVL as it seemed to be the safest approach within this scenario.

Although the guidelines for IVL suggest vessel size: balloon ratio of 1:1, we decided to use a smaller sized balloon based on the very small MLA, at the underexpanded segment, measured by OCT as well as the fact that IVL is a slightly bulky balloon and we had concerns that it might be difficult for a 3.5 IVL balloon to cross such tight stenosis. Therefore, a 2.5 x12 mm lithotripsy balloon (Shockwave Medical, Fremont, CA) was positioned across the underexpanded segment of the stent and inflated to 4 ATM; then, 10 shockwave pulses were delivered at a rate of 1 pulse per second, after which the balloon was inflated further to 6 ATM for 5–10 s [Figure 2]. This was repeated five times, thus delivering a total of 50 pulses. Of note, initially there was a waist within the lithotripsy balloon, but surprisingly after only four pulses the balloon suddenly expanded and was no longer waisted. Repeated angiography showed better stent expansion, and further postdilatation was performed with a 4.0-mm NC balloon [Figure 2]. Complete stent expansion was confirmed

by repeat OCT [Figure 2]. The patient was doing well at the three-month follow-up in the cardiology clinic.

DISCUSSION

This case report highlights a case when IVL was successfully used to treat a severely underexpanded freshly deployed coronary stent due to marked circumferential calcification, as was shown by OCT. The lesion was properly prepared with multiple-balloon predilatation; however, the stent remained underexpanded. Fortunately, applying shockwave lithotripsy resulted in uniform proper stent expansion.

Even though a few reports have been recently documented about the use of IVL to treat coronary stent underexpansion,^[2] we assume this case is unique because, to our knowledge, there are only a few reports about the use of IVL for the treatment of freshly deployed underexpanded coronary stents.^[3-5] Further, it illustrates an alternative safe and effective approach to deal with tight calcified lesions when there is a high risk of perforation.^[6]

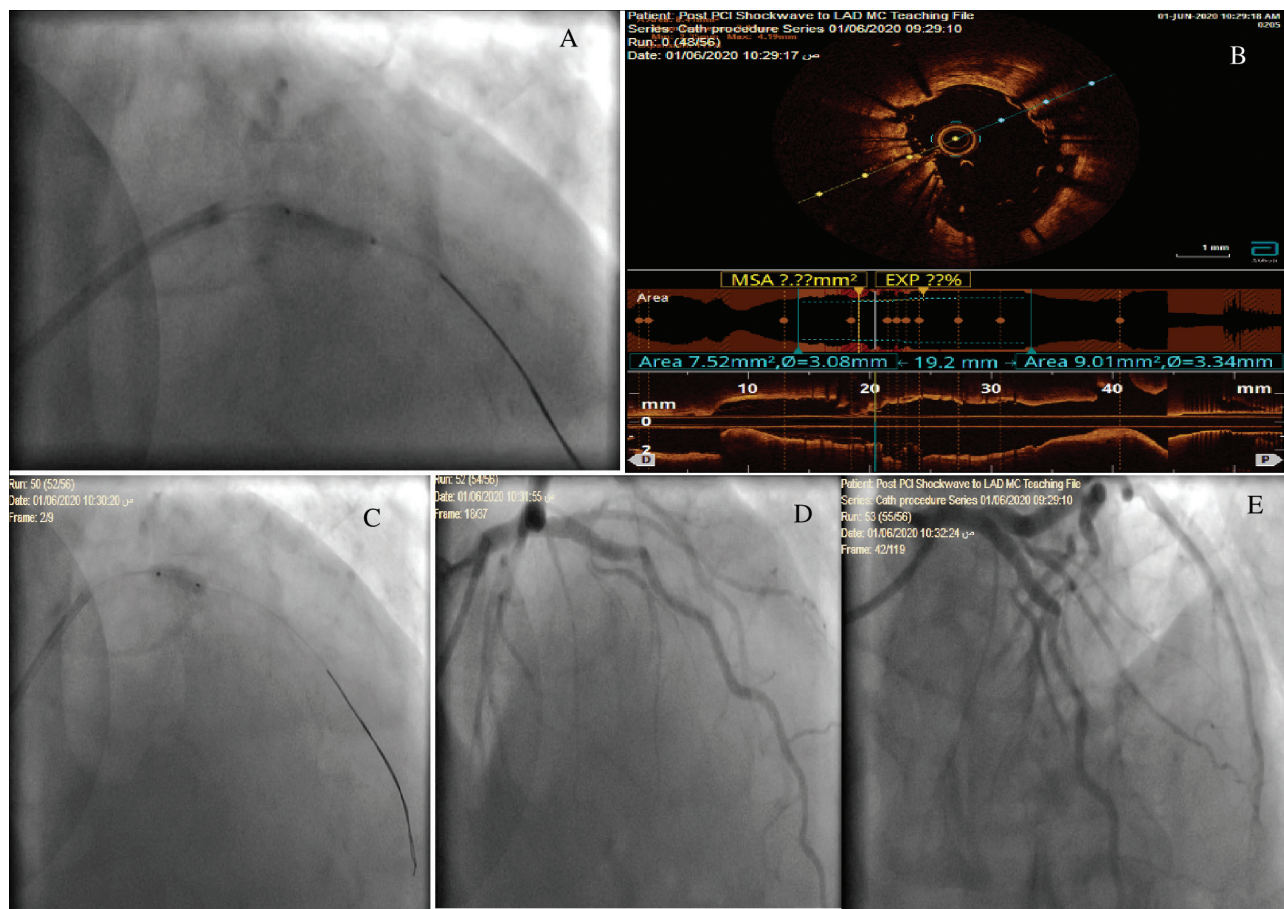


Figure 2: (A) IVL balloon showing absence of “dog-boning” effect. (B) Optical coherence tomography post-IVL showing good stent expansion. (C) Stent postdilatation after IVL. (D,E) Final angiographic views with fully expanded stent. IVL, intravascular lithotripsy

Calcified coronary lesions have been always a challenge for interventional cardiologists, as in many cases they may hinder the equipment's passage and may resist adequate modification both before and after stent implantation. In real practice, there are only limited treatment options for persistent stent underexpansion and most of the time they carry high risk. For instance, scoring or cutting balloons can alter the integrity of the stents, whereas using higher pressure inflations with an NC/OPN balloon predisposes one to strut fracture, stent deformation, or vessel perforation. Although excimer laser and rotational atherectomy can achieve successful results, unfortunately, they are not available in all centers and also carry a few risks, for instance, high target lesion revascularization rate, strut embolization, and burr entrapment.^[7,8] The IVL acts by modifying intimal and medial calcifications through sending acoustic pressure pulses that crackle calcium, thus easing stent expansion.^[9]

Although applying IVL for de novo calcified coronary lesions has been proved to be safe and effective, its use in freshly deployed non-endothelialized stents is still under investigations. Issues such as peeling off the stent's polymer coat as well as indenting its metal—predisposing corrosion—have been documented with bench testing studies; however, a recent case report showed favorable OCT findings at four months post-IVL for a stent that was deployed one month before IVL.^[10]

Finally, although our case offers a potential safe and highly effective tool for the management of acute stent underexpansion, we must mention that IVL should only be used on bail-out situations, and priority should always go for lesion preparation before stent implantation to avoid such complications. Moreover, operators should have a low threshold of using intra-coronary imaging (e.g. IVUS or OCT) in suspected highly calcified coronary lesions and never underestimate a lesion's severity.

In conclusion, IVL may be considered a safe, feasible, and effective alternative approach to deal with acute stent

underexpansion caused by severe calcification. Of note, we recommend further investigations to confirm this proposed approach, particularly investigating its long-term outcomes.

Financial support and sponsorship

Nil.

Conflicts of interest

There are no conflicts of interest.

REFERENCES

1. Barbato E, Shlofmitz E, Milkas A, Shlofmitz R, Azzalini L, Colombo A. State of the art: Evolving concepts in the treatment of heavily calcified and undilatable coronary stenoses—from debulking to plaque modification, a 40-year-long journey. *Eurointervention* 2017;13:696-705.
2. Watkins S, Good R, Hill J, Brinton TJ, Oldroyd KG. Intravascular lithotripsy to treat a severely underexpanded coronary stent. *Eurointervention* 2019;15:124-5.
3. Morabito G, Tripolino C, Tassone EJ, Grillo P, Missiroli B. A case of stent under-expansion due to calcified plaque treated with shockwave lithoplasty. *Cardiology* 2018;141:75-7.
4. Tumminello G, Cavallino C, Demarchi A, Rametta F. Bail-out unexpanded stent implantation in acute left main dissection treated with intra coronary lithotripsy: A case report. *Eur Heart J Case Rep* 2019;3:1-5.
5. Yeoh J, Cottens D, Cosgrove C, Mallek K, Strange J, Anderson R, *et al.* Management of stent underexpansion using intravascular lithotripsy—Defining the utility of a novel device. *Catheter Cardiovasc Interv* 2020;1-8.
6. Kobayashi Y, Okura H, Kume T, Yamada R, Kobayashi Y, Fukuhara K, *et al.* Impact of target lesion coronary calcification on stent expansion. *Circ J* 2014;78:2209-14.
7. Topaz O, Ebersole D, Das T, Alderman EL, Madyoon H, Vora K, *et al.* Excimer laser angioplasty in acute myocardial infarction (The CARMEL Multicenter Trial). *Am J Cardiol* 2004;93:694-701.
8. Ferri LA, Jabbour RJ, Giannini F, Benincasa S, Ancona M, Regazzoli D, *et al.* Safety and efficacy of rotational atherectomy for the treatment of undilatable underexpanded stents implanted in calcific lesions. *Catheter Cardiovasc Interv* 2017;90:E19-24.
9. Serruys PW, Katagiri Y, Onuma Y. Shaking and breaking calcified plaque: Lithoplasty, a breakthrough in interventional armamentarium? *JACC: Cardiovasc Imaging* 2017;10:907-11.
10. Alawami M, Thirunavukarasu S, Ahmed J, El-Omar M. Intravascular lithotripsy to treat an underexpanded coronary stent: 4-Month angiographic and OCT follow-up. *Catheter Cardiovasc Interv* 2020;1-7.