

## CASE REPORT

# Ileal volvulus secondary to cystic lymphangioma: a rare case report with a literature review

Shoog F. Alfadhel, Abdulmajeed A. Alghamdi<sup>1</sup>, Saif A. Alzahrani<sup>2</sup>

Medical Student, Faculty of Medicine, King Saud Bin Abdulaziz University for Health Sciences KSAU-HS, Riyadh, <sup>1</sup>Medical Intern, Faculty of Medicine, Al-Baha University, Kingdom of Saudi Arabia

## Access this article online

Website: [www.avicennajmed.com](http://www.avicennajmed.com)

DOI: 10.4103/ajm.AJM\_203\_18

## Quick Response Code:



## ABSTRACT

Lymphangioma is a benign malformation of the lymphatic system. It usually affects the neck, head, and rarely, the abdomen. Volvulus is a serious condition, which occurs as a result of bowel twisting around itself or around the mesentery leading to severe consequences such as obstruction. The most common cause of volvulus in children is malrotation. We report a rare case of a 2-year-old boy who was brought by his parents to the emergency room with the complaint of constipation for 5 days and vomiting for the last 4 days. Examination and plain abdominal X-ray suggested intestinal obstruction. Furthermore, ultrasonography indicated the presence of a cyst and dilatation of the bowel. On exploratory laparotomy, an ileal volvulus caused by cystic lymphangioma developed on the mesenteric wall and associated with ileal and jejunal dilatation was observed. The diseased segments were resected in addition to 5 cm before and after the cystic lymphangioma to prevent recurrence.

**Key words:** Lymphangioma, obstruction, volvulus

## INTRODUCTION

Lymphangiomas are benign tumors thought to be a result of congenital malformation in the lymphatic tissue. They are common among children and infants and usually found in the neck and head but they rarely present in the abdomen. Volvulus occurs when any part of bowel twists around itself or its mesentery, which causes an obstruction of its lumen and blockage of blood supply. Lymphangiomas are also considered as a rare cause of volvulus in children, with malrotation being the most common cause of volvulus among children. Cystic lymphangiomas, when present intra-abdominally, can cause obstruction due to large size or as consequence of a volvulus. Hereby we report a rare case of cystic lymphangioma developed on mesenteric and antimesenteric ileal wall and associated with ileal and jejunal dilatation, resulting in a volvulus and intestinal obstruction in a 2-year-old boy.

**Address for correspondence:** Ms. Shoog F. Alfadhel, Medical Student, Faculty of Medicine, King Saud Bin Abdulaziz University for Health Sciences KSAU-HS, Riyadh, Kingdom of Saudi Arabia.  
E-mail: [shoogalfadhel@gmail.com](mailto:shoogalfadhel@gmail.com)

## CASE HISTORY

A 2-year-old boy was brought by his parents to the emergency room with the complaint of constipation for 5 days and vomiting for the last 4 days. No associated fever was reported.

Previously, the parents took their child to two private hospitals, where he was given intravenous fluids without making any improvement. The patient has had the same symptoms three times in last few months. He had never undergone a surgery and no similar case was reported in the family. On examination, the patient looked unwell, tired, pale, and dehydrated. He was not jaundiced nor febrile. Local abdominal examination revealed absent bowel sounds

This is an open access journal, and articles are distributed under the terms of the Creative Commons Attribution-NonCommercial-ShareAlike 4.0 License, which allows others to remix, tweak, and build upon the work non-commercially, as long as appropriate credit is given and the new creations are licensed under the identical terms.

**For reprints contact:** [reprints@medknow.com](mailto:reprints@medknow.com)

**Cite this article as:** Alfadhel SF, Alghamdi AA, Alzahrani SA. Ileal volvulus secondary to cystic lymphangioma: A rare case report with a literature review. *Avicenna J Med* 2019;9:82-5.

with mild distention. However, no tenderness, rigidity, or mass on palpation was observed. He had a blood pressure of 109/72 mm Hg and a normal pulse rate of 114/min. The initial venous blood gas test indicated the presence of acidosis with the following values: pH = 7.28, PCO<sup>2</sup> = 9.8 mm Hg, PO<sup>2</sup> = 50.7 mm Hg, and HCO<sup>3</sup> = 6.8 mmol/L. The serum creatinine level was 15.13 umol/L, albumin was 32.7 g/L, alanine aminotransferase was 25 IU/L, and potassium was

3.4 mmol/L. All were considered to be below normal levels for age and gender. Other lab tests were unremarkable.

On abdominal X-ray, multiple air fluid levels were noticed [Figure 1]. Ultrasonography of the abdomen showed a large cyst size of 3.41 cm [Figure 2A], dilatation of bowel loops, and wall thickening to approximately 3.5 mm, and free fluid [Figure 2B]. On the basis of radiological findings, an exploratory laparotomy was planned. On exploration, an ileal volvulus secondary to cystic lymphangioma developed on the mesenteric and antimesenteric ileal wall and associated with ileal and jejunal dilation was observed. The diseased segment was resected plus 5 cm proximal and distal to the cystic lymphangioma [Figure 3]. Ileal to ileal anastomosis was performed after resection. The condition of the patient improved and he was discharged 4 days after surgery.

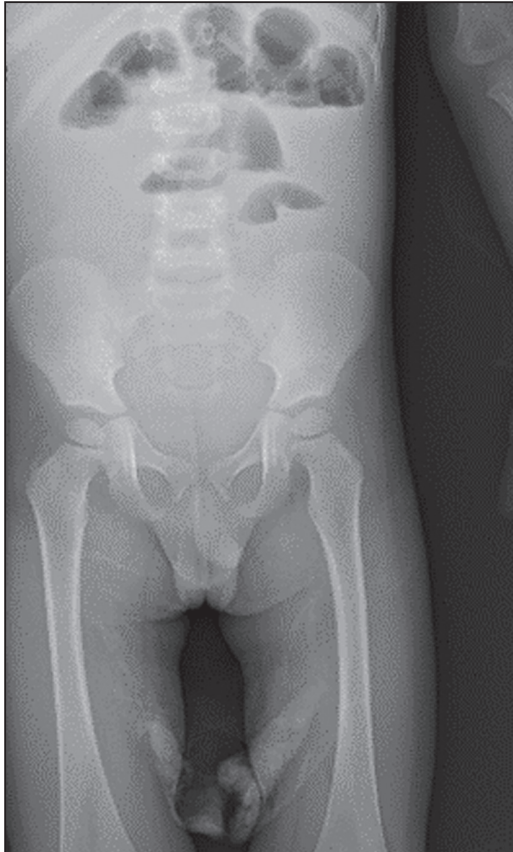


Figure 1: Plain abdominal X-ray showing multiple air fluid levels

## DISCUSSION

Lymphangiomas are rare congenital malformations of the lymphatic system occurring mostly in skin and subcutaneous tissues of the head and neck. We report the unique case of a 2-year-old boy with ileal cystic lymphangioma diagnosed via ultrasound causing volvulus and obstruction managed with emergent laparotomy and resection. In rare occasions, cystic type can be found in the abdomen, causing intestinal obstruction.<sup>[1]</sup> Volvulus on the other hand is caused by an axial twist in the gastrointestinal tract. They are frequently found in the colon and rarely occur in the small bowel.<sup>[2]</sup> Although the well-known cause of volvulus in children is malrotation, intestinal lymphangioma is considered as a rare cause, precipitating small intestinal obstruction.<sup>[3]</sup>

Clinically, the condition commonly presents with severe abdominal pain along with the symptoms of intestinal

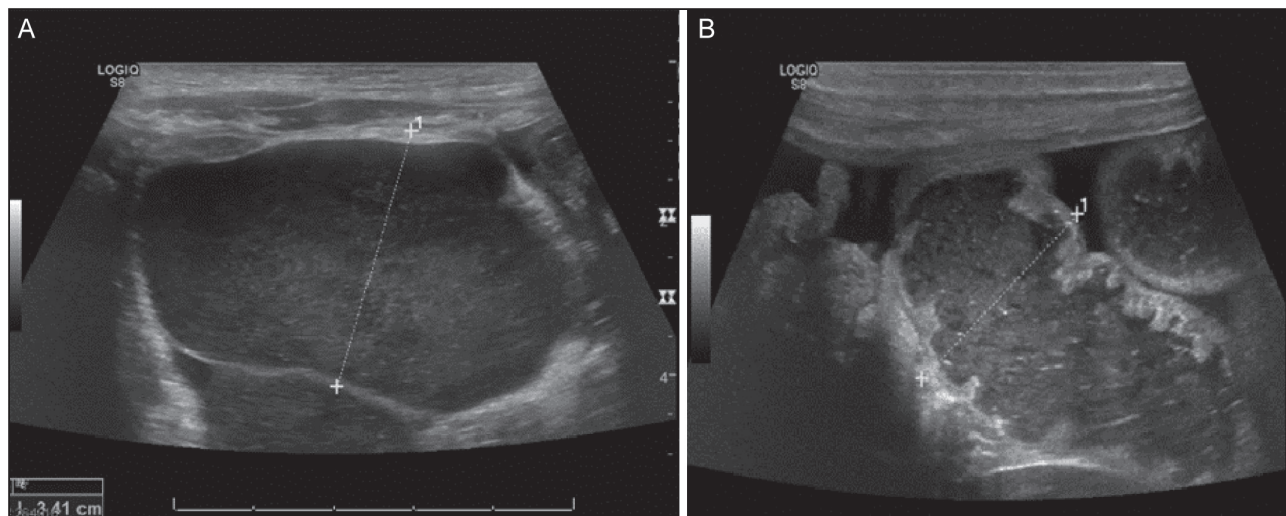


Figure 2: (A) Ultrasonography showing large cyst. (B) Ultrasonography showing dilatation of the bowel loops associated with thickening of its wall

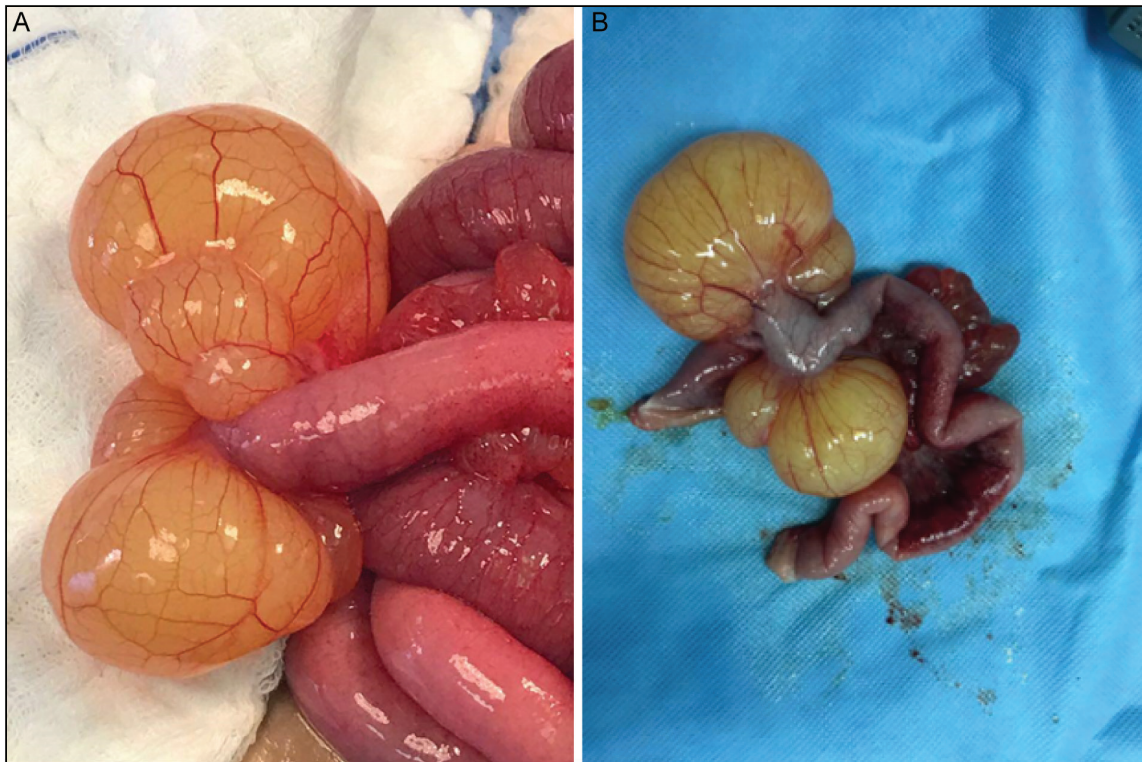

Figure 3: (A) Photo showing the cystic lymphangioma causing the volvulus. (B) Photo showing the lymphangioma and the affected bowel after resection

Variable	Cardella et al. <sup>[5]</sup>	Prehal and Hagerb <sup>[7]</sup>	Prehal and Hagerb <sup>[7]</sup>	Sham et al. <sup>[9]</sup>	Mabrouk et al. <sup>[10]</sup>
Age	7 years	13 months	28 months	2 months	4 years
Gender	F	F	M	F	M
Symptoms	Abdominal pain	Constipation	Vomiting	Vomiting	Abdominal pain
Investigations	CT	US	US and MRI	X-ray, US, CT	US
Diagnosis	Mesenteric lymphangioma	Mesenteric lymphangioma	Mesenteric lymphangioma	Mesenteric lymphangioma	Mesenteric lymphangioma
Procedure	Laparotomy	Laparotomy	Laparotomy	Laparotomy	Laparotomy
Prognosis	Uneventful	Uneventful	-	Uneventful	Uneventful

F = female, M = male, CT = computed tomography, US = ultrasound, MRI = magnetic resonance imaging

obstruction. Fortunately, most children have acute persistent symptoms, which lead physicians to investigate all possible differentials.<sup>[4]</sup> Our patient has had an acute presentation of constipation and persistent vomiting for 4 days.

Imaging is of great importance in diagnosing the condition preoperatively. Relying on clinical findings alone cannot confirm the diagnosis.<sup>[5]</sup> Although a plain X-ray maybe normal, it can show the presence of an obstruction and dilated bowel loops as well.<sup>[2]</sup> On ultrasonography, the tumor appears as a well-defined cystic mass.<sup>[6]</sup> In our case, the X-ray showed air fluid level, which is consistent with intestinal obstruction, in addition to dilated bowel loops.

The definitive treatment of volvulus lymphangioma is surgical resection. In many cases, such as the presented one, cysts develop on the mesenteric wall. They need resection of the adjacent bowel to ensure complete removal of the

cyst.<sup>[5]</sup> In case of bowel strangulation, resection is required as well.<sup>[3]</sup> The purpose of radical resection is to prevent the relapse phase, in which the cyst grows again, requiring additional resection of bowel and organs if any is involved.<sup>[7]</sup> The use of laparoscopy is considered superior to laparotomy. Noticeably, laparotomy has been associated with adhesions and longer hospital stay.<sup>[8]</sup> Although, in many reports, the surgeons have preferred laparotomy. This can be due to unclear diagnosis before performing the surgery.

The prognosis is usually good once the condition is recognized early. Generally, reported cases indicated a good prognosis and minimum hospital stay of less than 7 days.<sup>[3,5,7]</sup>

The literature has similar reported cases with variable presenting symptoms, imaging studies, and definitive diagnoses [Table 1].

## CONCLUSION

Lymphangiomas are uncommon benign tumors that can rarely cause volvulus in the small intestines. Presenting symptoms reported in the literature are abdominal pain, vomiting, and constipation. Diagnosis can be suggested by radiological studies, whereas the definitive diagnosis and management is usually reached through laparotomy. We reported a rare case of a 2-year-old boy who presented with constipation and vomiting for 5 days. Radiological studies suggested an intestinal obstruction caused by a cyst. Laparotomy was performed successfully, the condition of the patient improved and he was discharged 4 days after surgery.

### Financial support and sponsorship

Nil.

### Conflicts of interest

There are no conflicts of interest.

## REFERENCES

1. Jain S, Jain M, Meena L, Bansal S. Lymphangioma of small bowel wall: A rare case report. *SEAJCRR* 2014;3:811-6.
2. Islam S, Hosein D, Dan D, Naraynsingh V. Volvulus of ileum: A rare cause of small bowel obstruction. *BMJ Case Reports* 2016;2016:bcr2016216159.
3. Kim Y, Moon S. Segmental volvulus of the ileum without malrotation in an infant: A case report. *J Paediatr Surg Case Reports* 2015;3:397-9.
4. Day W, MY Kan D. A small bowel lymphangioma presenting as a volvulus. *Hong Kong Med J* 2010;16:233-4.
5. Cardella L, Carman T, Ponsky T. Giant jejunal mesenteric lymphangioma causing acute small bowel volvulus. *J Pediatr Surg Case Reports* 2018;28:77-80.
6. Kim Y, Jung Y, Im M, Choi S, Kim E, Choi Y. CT findings of ileal cystic lymphangioma: A case report. *J Korean Society Radiol* 2012;66:283.
7. Prehal M, Hagerb J. Intraabdominal cystic lymphangiomas in children: A single center experience. *Int J Clin Pediatr* 2014;3:89-93.
8. Ooms N, Matthyssens LE, Draaisma JM, de Blaauw I, Wijnen MH. Laparoscopic treatment of intestinal malrotation in children. *Eur J Pediatr Surg* 2016;26:376-81.
9. Sham M, Kudrimoti J. Rare location of mesenteric cystic lymphangioma in an infant. *J Clin Neonatol* 2014;3:164-6.
10. Mabrouk M, Barka M, Farhat W, Harrabi F, Azzaza M Abdennaceur N, *et al.* Intra-abdominal cystic lymphangioma: Report of 21 cases. *J Cancer Therapy* 2015;6:572-8.