

Effect of Diabetes on Central Macular Thickness Quantitatively Measured using Optical Coherence Tomography at Sidi-Hussein Health Center, Benghazi, Libya

Mervat A. Omear, Samar A. Bukhatwa¹, Fatma Saleh Benkhaial²

Department of Ophthalmology, Sidi Hussein Health Center, ¹Department of Ophthalmology, Faculty of Medicine, University of Benghazi, ²Department of Family and Community Medicine, Faculty of Medicine, University of Benghazi, Benghazi, Libya

Abstract

Introduction: Diabetic macular edema (DME) is the most common cause of decreased vision in diabetic retinopathy (DR) and its detection needs equipment and skills. Optical coherence tomography (OCT) is an objective technique that can measure retinal morphologic characteristic which help improving diagnosis and treatment. **Aims:** This study was conducted to evaluate the role of OCT macula in the screening for DME in patients with diabetes by comparing it to clinical funduscopy in addition to assessing the relationship between central macular thickness (CMT) as measured by OCT macula and the visual acuity of patient. **Settings and Design:** A retrospective study was done at Sidi Hussein Health center/Benghazi in the period between 2014 and 2017. **Subjects and Methods:** The data of 393 (786 eyes) patients with diabetes (type II) were reviewed. Cases characteristics records were extracted in addition to fundus examination records (done by noncontact +90-diopter lens). The records of OCT (CMT) were evaluated for agreement with the subjective fundus examination and in relation to other measures. Data were presented as frequencies and the statistical analyses were performed using Statistical Package for the Social Science (Windows version 17.0; SPSS Inc., USA). **Results:** Around 537 eyes (82%) of eyes with mild DME as diagnosed by OCT were having no DR when examined subjectively. With OCT, it was found that 555 eyes (85%) with mild DME were having good visual acuity (logarithm of the minimum angle of resolution 0.3 and less). About 10 eyes (71%) having severe DME were having duration of diabetes of 10–20 years. **Conclusions:** OCT is a noninvasive method that can objectively detect and quantify early DME before it affects the vision of patients and it is strongly recommended that this should be the technique of choice for detecting and screening of DME in Libyan patients.

Keywords: Benghazi, central macular thickness, diabetic retinopathy, Libya, optical coherence tomography

INTRODUCTION

The prevalence of diabetes in Middle East and North Africa is 9.1% and this is expected to reach 11.4% by the year 2040.^[1] Benghazi is the second-largest city in Libya with 541,104 inhabitants according to the Bureau of Statistics and Census Libya on 2012,^[2] and with a prevalence of diabetes mellitus (DM) equal to 14.1%.^[3] Diabetic retinopathy (DR) is a major cause of vision loss in working-age group with a global prevalence of 35%.^[4] Roaeid and Kadiki,^[5] reported a prevalence of 30.6% of DR among patients with diabetes attending Benghazi Diabetic Centre that in their opinion was underestimated because it was based only on the fundus examination using direct ophthalmoscopy.

Diabetic macular edema (DME) is the most common cause of decreased vision in DR.^[6]

Detecting DME with a slit-lamp biomicroscopic examination needs equipment and skills; and the use of fluorescein angiography (FA) is considered effective, but it is an invasive method for diagnosis.^[7] Optical coherence tomography (OCT)

Address for correspondence: Dr. Samar A. Bukhatwa, Department of Ophthalmology, Faculty of Medicine, University of Benghazi, Benghazi, Libya.
E-mail: samar.bukhatwa@uob.edu.ly

This is an open access journal, and articles are distributed under the terms of the Creative Commons Attribution-NonCommercial-ShareAlike 4.0 License, which allows others to remix, tweak, and build upon the work non-commercially, as long as appropriate credit is given and the new creations are licensed under the identical terms.

For reprints contact: reprints@medknow.com

How to cite this article: Omear MA, Bukhatwa SA, Benkhaial FS. Effect of diabetes on central macular thickness quantitatively measured using optical coherence tomography at Sidi-Hussein Health Center, Benghazi, Libya. *Libyan Int Med Univ J* 2019;4:49-55.

Received: 27-09-2019 **Accepted:** 02-11-2019

Published Online: 30-12-2019

Access this article online

Quick Response Code:



Website:
journal.limu.edu.ly

DOI:
10.4103/LIUJ.LIUJ_22_19

is an objective technique that can measure retinal morphologic characteristic which help improving diagnosis, treatment and the ultimate visual outcomes in patients with diabetes.^[8]

The aim of this study was to evaluate the role of OCT macula in the screening for DME in patients with diabetes by comparing it to clinical funduscopy in addition to assessing the relationship between central macular thickness (CMT) as measured by OCT macula and the visual acuity of patient.

SUBJECTS AND METHODS

A retrospective study was used. The records of ophthalmology patients attended Sidi Hussein Health Center, Benghazi, Libya, between January 2014 and December 2017 were reviewed.

Most of the patients were diabetics referred by the physicians in Sidi Hussein Health Center for an ophthalmological check-up at the outpatient department (OPD) of the center as a routine examination for diabetics attending the center, and fewer numbers of patients were known cases of DR attending the OPD for follow-up.

Inclusion criteria

Patients with an established diagnosis of type 2 DM with or without DR.

Exclusion criteria

Exclusion criteria were eyes with significant media opacities that can result in poor OCT signal, high refractive errors, vascular or pathological changes other than DR and patients with previous intravitreal injection or any retinal surgery or laser photocoagulation.

Data collection tools

A complete data record was extracted including age, gender, duration of DM (from the time of diagnosis to the time of examination), their glycosylated hemoglobin level, anti-diabetic treatment used, presence or absence of systemic hypertension, best-corrected Snellen visual acuity recorded as logarithm of the minimum angle of resolution (log MAR), and slit-lamp biomicroscopy fundus examination record of the stage of DR by the same experienced ophthalmologist.

Fundus examination was done through dilated Pupil using 1% tropicamide with the help of noncontact fundus lens (+90-diopter lens) and classified according to the criteria of the Early Treatment Diabetic Retinopathy Study (ETDRS) Research Group protocol^[9] as follow:

No diabetic retinopathy (NDR), nonproliferative diabetic retinopathy with clinically significant macular edema (NPDR with CSME), NPDR without CSME, PDR without CSME and CSME.

Macular edema was considered to be clinically significant as defined by the ETDRS protocol.^[10]

Although the use of contact lens biomicroscopic examination is considered more accurate in evaluation of DR in clinical practice, the noncontact +90 diopter lens was chosen here because it is used more often in most of the OPDs.^[11]

OCT scans images were performed by (RS-3000 Advance–NIDEK); which is a spectral-domain (SD) OCT; in a spoke-like pattern through a dilated pupil (1% tropicamide eye drops), OCT setting:

MACULA RADIAL 12 (6.0 mm [1024]) according to the manufacturer's protocol as described in the user's manual.^[12]

CMT/foveal thickness was defined as the retinal thickness in central 1 mm area of the ETDRS layout and it was automatically calculated by the instrument software. Therefore, we reviewed the existing literature in which foveal thickness was measured by OCT in healthy controls without diabetes,^[13-16] and analysis suggested that 200 μm cutoff for the upper level of normal foveal thickness in healthy nondiabetic adults; and so, an OCT foveal thickness of 200 μm or less was defined as normal, 201–300 μm as mild thickening, 301–400 μm as moderate thickening, and >400 μm as severe thickening.^[8]

Ethical issues

The study was conducted according to the principles of the World Medical Association Declaration of Helsinki. A formal approval was obtained from the Department of Health Services Benghazi authorities.

Statistical analysis

Data were presented as frequencies and mean \pm standard deviation (SD). Statistical analyses were performed using Statistical Package for the Social Science (Windows version 17.0; SPSS Inc., Chicago, IL, USA).

Chi-square test was used to analyze the statistical differences between two categorical variables. $P \leq 0.05$ was considered statistically significant.

RESULTS

The records of 558 patients attended the ophthalmology clinic of Sidi Hussein Health center, Benghazi, between January 2014 and December 2017 were reviewed.

Only 393 patients (786 eyes) fulfill the criteria's and were included in this study. Patients excluded were about 165, out of them 89 patients (54%) were having media opacity, 21 patients (13%) with another eye pathology (e.g., glaucoma, high refractive errors, and age-related macular degeneration) and 55 patients (33%) were having previous intravitreal injection, retinal surgery, or laser photocoagulation.

Table 1 shows the categorical variable presentation, while Table 2 shows statistical presentation of the cases with mean \pm SD.

Subjective examination by slit-lamp biomicroscopic fundus examination with +90 D lens showed that 619 eyes (80%) were having NDR changes and the remaining 167 eyes (20%) were having different levels of DR [Table 1].

On the other hand, OCT measurement showed that 537 eyes (82%) out of 653 eyes with mild macular edema (CMT = 201–300 μm) were diagnosed as NDR when examined biomicroscopically, this disagreement between the subjective fundus examination and OCT measurements was statistically significant ($P < 0.0001$) [Figure 1].

About 555 eyes (85%) out of 653 eyes with mild macular edema (CMT = 201–300 μm), were having good visual

acuity (log MAR 0.3 and less), which was highly significant ($P = 0.0001$) [Figure 2].

Nearly 10 eyes (71%) out of 14 eyes with severe macular edema (CMT >400 μm) were having the duration of diabetes of 10–20 years, and this was statistically significant ($P = 0.027$) [Figure 3].

Table 1: Categorical variable case characteristics in 786 eyes

Characteristic	n (percentage of eyes)
Gender	
Male	278 (35)
Female	508 (65)
Treatment	
Oral	392 (50)
Insulin	330 (42)
Mixed	64 (8)
Duration of DM (years)	
<10	426 (54)
10-20	306 (39)
More than 20	54 (7)
Type of diabetic retinopathy	
NDR	619 (80)
NPDR with CSME	39 (5)
NPDR without CSME	82 (10)
PDR without CSME	21 (2)
CSME	25 (3)
HbA1c	
6.5% and less	196 (25)
More than 6.5%	590 (75)
Hypertension	
Yes	270 (35)
No	516 (65)
Visual acuity (log MAR)	
0.3 and less	650 (83)
More than 0.3	136 (17)
Central macular thickness interval (μm)	
0-200	60 (7.6)
201-300	653 (83)
301-400	59 (7.4)
More than 400	14 (2)

NDR: No diabetic retinopathy, NPDR: Nonproliferative diabetic retinopathy, PDR: Proliferative diabetic retinopathy, CSME: Clinically significant macular edema, HbA1c: Glycosylated hemoglobin level, Log MAR: Logarithm of the minimum angle of resolution

Table 2: Continuous case characteristics in 786 eyes

Characteristic	Minimum	Maximum	Mean \pm SD
Age (years)	41	82	56 \pm 8.3
Duration of DM (years)	1	35	9.8 \pm 7.6
HbA1c (%)	4	15	7.9 \pm 1.8
Visual acuity (log MAR) (Snellen equivalent)	1.0 (6/60)	0.0 (6/6)	0.18 \pm 0.22 (6/9 \pm 1)
Central macular thickness (μm)	100	653	258 \pm 51

DM: Diabetes mellitus, HbA1c: Glycosylated hemoglobin level, Log MAR: Logarithm of the minimum angle of resolution, SD: Standard deviation

There was a significant difference regarding CMT between males and females, 11 eyes (78.5%) out of 14 eyes with severe macular edema (CMT > 400 μm) were male whereas 45 eyes (75%) out of 60 eyes with normal macular thickness (CMT = 0–200 μm) were females ($P = 0.002$) [Figure 4].

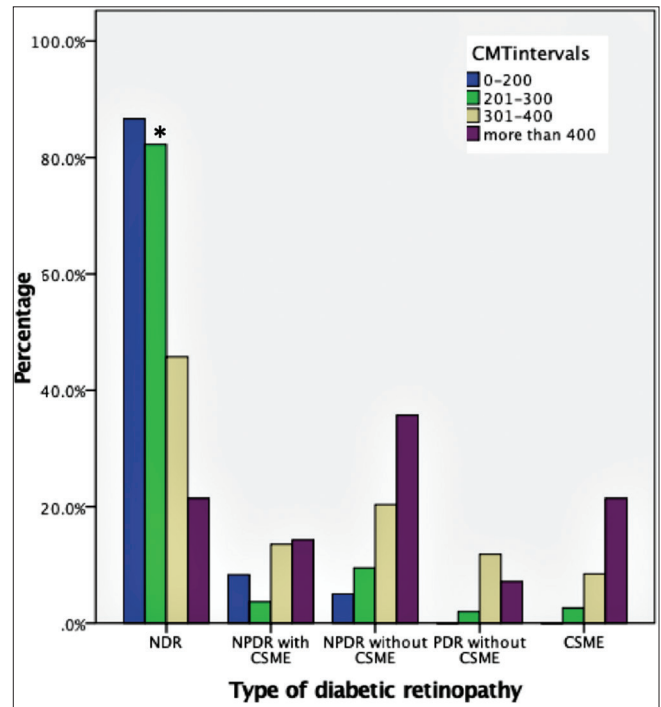


Figure 1: Central macular thickness interval in μm measured by optical coherence tomography in relation to type of diabetic retinopathy. * $P < 0.0001$ NDR: No diabetic retinopathy, NPDR: Nonproliferative diabetic retinopathy, PDR: Proliferative diabetic retinopathy, CSME: Clinically significant macular edema

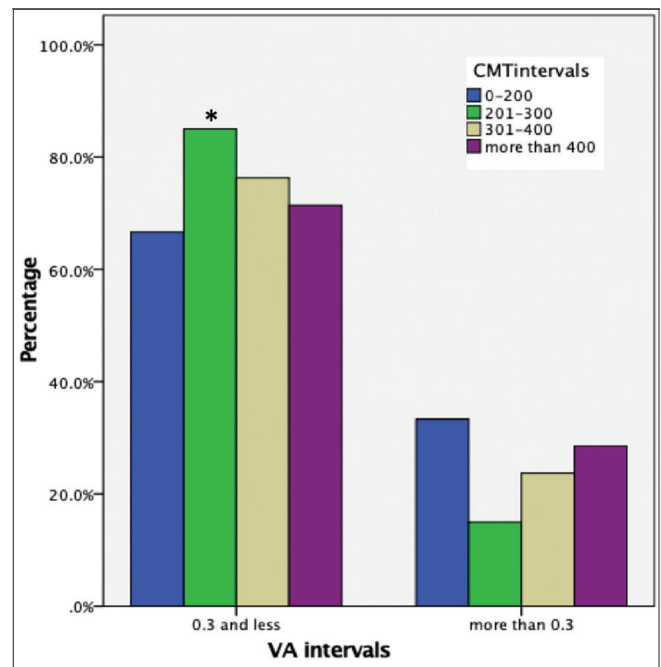


Figure 2: Central macular thickness interval in μm measured by optical coherence tomography in relation to VA (visual acuity) intervals. * $P = 0.0001$

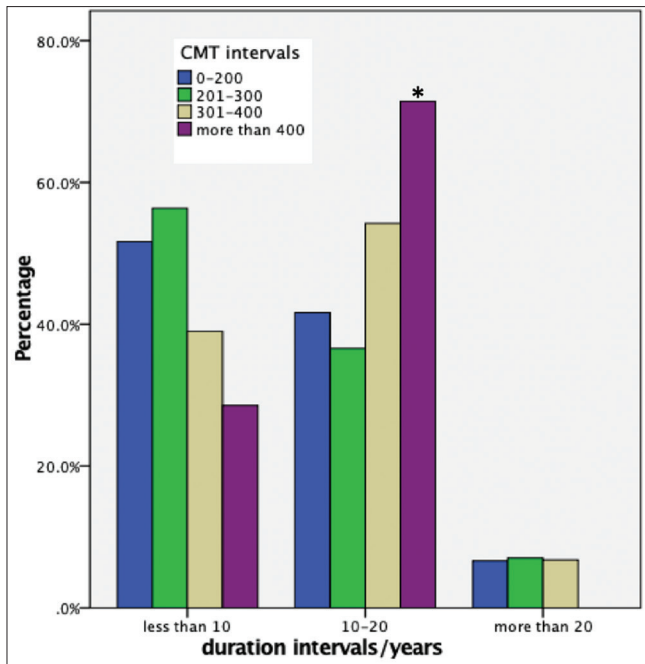


Figure 3: Central macular thickness interval in μm measured by optical coherence tomography in relation to duration intervals in years $*P = 0.027$

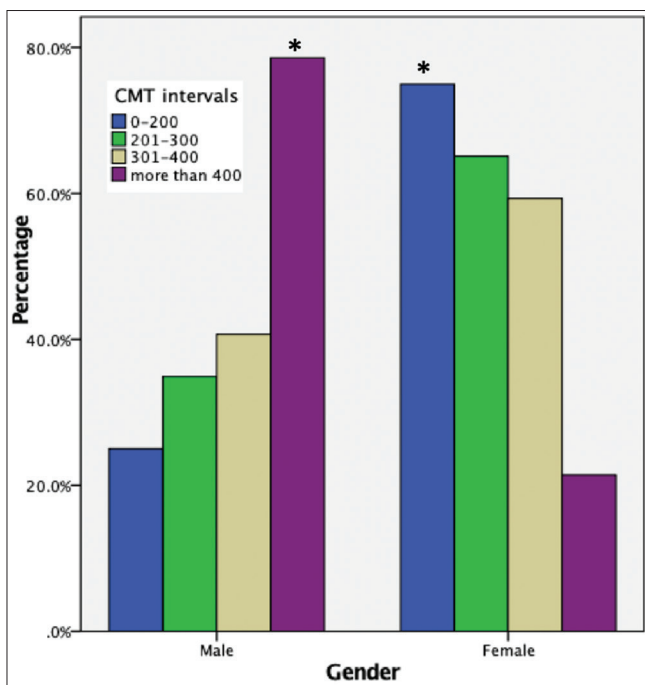


Figure 4: Central macular thickness interval in μm measured by optical coherence tomography in relation to gender $*P = 0.002$

DISCUSSION

DR is one of the main causes of visual impairment and blindness.^[17]

Macular edema is the most important sign of visual loss in type 2 diabetes if undetected or untreated.^[18,19] Moreover, it can affect visual acuity at any stage of DR.^[1]

OCT is believed to be superior to other diagnostic methods such as biomicroscopy, FA, ultrasound, and retinal thickness analysis in the way that it quantifies, has a higher sensitivity and resolution in the discovery of macular edema and subretinal fluid and its ability to quantitatively monitor responses to various types of the treatment of DME.^[20-25]

In the current study, there was disagreement between OCT measures and subjective fundus examination; while objectively there were 537 eyes (82%) with mild macular edema (CMT = 201–300 μm) measured by OCT; these were diagnosed by noncontact lens fundus examination as NDR. Hence, the increased macular thickness was not detected in a large number of cases when done subjectively. Many investigators reported similar results, Brown *et al.* found that there was a poor agreement between contact lens fundus examination and OCT when foveal thickness was mildly increased (201–300 μm).^[8] Shahidi *et al.* in a study done by the retinal thickness analyzer, reported that noncontact slit-lamp biomicroscopy could not detect the increase in retinal thickness when it was 1.5 times the normal thickness.^[26] Abrar *et al.* reported the increase in macular thickening with progressing stages of DR without evidence of any CSME.^[27] Oshima *et al.* in their study showed that the retinal thickness in patients with diabetes without CSME was significantly greater than nondiabetic eyes.^[28] Lattanzio *et al.* in their study concluded that macular thickness was greater in diabetics than controls and advised the use of OCT for early detection of macular edema.^[14]

In the current study, it was found that 555 eyes (85%) having mild macular edema (CMT = 201–300 μm) retained good visual acuity (log Mar 0.3 and less). Therefore, the mild increase in macular thickness was not reflected by visual deterioration which means that OCT detected macular thickness before it could affect the vision and this is seriously important to consider when monitoring the patients.

Sánchez-Tocino *et al.* stated that the methods used to evaluate macular thickening are relatively insensitive both to early changes in retinal thickness and in those cases in which vision has not been affected yet.^[13] Arora *et al.*, although showed a strong relation between macular thickness and visual acuity they suggested that a broad range of visual acuity are possible for the degree of changes in macular edema.^[29] In a large study by DRCR.net, they concluded that central retinal thickness accounts for about 27% of the variation in visual acuity and this is consistent with the results in this study.^[30]

In this study, there was a statistically significant relation between CMT and duration of DM; since 10 eyes (71%) with severe macular edema (CMT > 400 μm) were having a duration of DM between (10–20) years. Although this contrasts with a previous study done by Elzarrug *et al.*, in Benghazi/Libya, who showed no relation between CSME and duration of DM but that study was done subjectively by biomicroscopic fundus examination and without the use of OCT.^[31] Moreover, our results are in consistent with other’s studies.^[32,33]

It was found that there was a significant relation with gender; 11 eyes (78.5%) with severe macular edema (CMT > 400 µm) were male, whereas 45 eyes (75%) with normal macular thickness (CMT = 0–200 µm) were female. and this contrasts with a study done previously in the United States by means of fundus photographs that shows no differences in DME prevalence by sex.^[34]

Brown *et al.* suggested the term subclinical foveal edema to describe eyes with mild macular thickness (201–300 µm) detected by objective imaging methods, because they fail to detect it by contact lens biomicroscopy,^[8] and similarly, in our study, these cases were neither detected subjectively nor affecting the visual acuity of the patients. Researchers showed that OCT is more sensible for the detection of early stage of edema that still not evident with biomicroscopy or FA.^[17,24]

In their study, Browning *et al.* analyzed the errors in clinical diagnosis of DME and showed that it is less sensitive than OCT and suggest that the shift to early diagnosis by OCT would lead to earlier intervention and treatment.^[25] Without the use of pupil dilatation; Hirano *et al.*, diagnosed fovea threatening DME using SD-OCT with a sensitivity of 100%,^[35] and Medina *et al.* considered SD-OCT as a useful tool to detect and to measure DME in the nonmydriatic pupil.^[36]

In this study, OCT detected the increase in macular thickness in 82% of the eyes that shows absence of biomicroscopic evidence of ME thus confirming that OCT is superior to noncontact slit-lamp biomicroscopy in detecting and quantifying the increase in macular thickness in diabetics.

CONCLUSIONS

OCT is a noninvasive method that takes few seconds to be done without exhausting and irritating the patient by strong light. It can detect and quantify early macular edema before affecting the vision of patients or becoming clinically apparent. It is strongly recommended that this technique should be the technique of choice for detecting and screening of DME in Libyan patients.

Limitation of the study

There was no control group, and we did not find any previous studies that measure the normal macular thickness in Libyan population, so we recommend researcher to evaluate this point.

Financial support and sponsorship

This research did not receive grants from any funding agency in the public, commercial, or not-for-profit sectors.

Conflicts of interest

There are no conflicts of interest.

REFERENCES

- International Diabetes Federation. IDF Diabetes Atlas. 7th ed. Brussels, Belgium: International Diabetes Federation; 2015. Available from: <https://www.idf.org/e-library/epidemiology-research/diabetes-atlas/13-diabetes-atlas-seventh-edition.html>. [Last accessed on 2018 Apr 17].
- Available from: <http://www.bsc.ly/>. [Last accessed on 2018 Apr 17].
- Kadiki OA, Roaeid RB. Prevalence of diabetes mellitus and impaired glucose tolerance in Benghazi Libya. *Diabetes Metab* 2001;27:647-54.
- Yau JW, Rogers SL, Kawasaki R, Lamoureux EL, Kowalski JW, Bek T, *et al.* Global prevalence and major risk factors of diabetic retinopathy. *Diabetes Care* 2012;35:556-64.
- Roaeid RB, Kadiki OA. Prevalence of long-term complications among type 2 diabetic patients in Benghazi, Libya. *J Diabetol* 2011;3:5.
- Massin P, Girach A, Erginay A, Gaudric A. Optical coherence tomography: A key to the future management of patients with diabetic macular oedema. *Acta Ophthalmol Scand* 2006;84:466-74.
- Richer S. Exam room, chair side evaluation of retinal edema: Improving accuracy and precision for identification of subclinical diabetic macular edema. *Optometry* 2007;78:664-73.
- Brown JC, Solomon SD, Bressler SB, Schachat AP, DiBernardo C, Bressler NM, *et al.* Detection of diabetic foveal edema: Contact lens biomicroscopy compared with optical coherence tomography. *Arch Ophthalmol* 2004;122:330-5.
- Photocoagulation for diabetic macular edema. Early treatment diabetic retinopathy study report number 1. Early treatment diabetic retinopathy study research group. *Arch Ophthalmol* 1985;103:1796-806.
- Early treatment diabetic retinopathy study design and baseline patient characteristics. ETDRS report number 7. *Ophthalmology* 1991;98:741-56.
- Brun SC, Bressler SB, Maguire MG, Heiner C, Bressler NM, Schachat AP. A comparison of fundus biomicroscopy and 90 diopter lens examination in the detection of diabetic clinically significant macular edema [ARVO abstract]. *Invest Ophthalmol Vis Sci* 1993;34:718.
- Available from: http://www.ophtalmicdata.com/wp-content/uploads/2015/03/optical_coherence_tomography.pdf. [Last accessed on 2018 May 12].
- Sánchez-Tocino H, Alvarez-Vidal A, Maldonado MJ, Moreno-Montañés J, García-Layana A. Retinal thickness study with optical coherence tomography in patients with diabetes. *Invest Ophthalmol Vis Sci* 2002;43:1588-94.
- Lattanzio R, Brancato R, Pierro L, Bandello F, Iaccher B, Fiore T, *et al.* Macular thickness measured by optical coherence tomography (OCT) in diabetic patients. *Eur J Ophthalmol* 2002;12:482-7.
- Adhi M, Aziz S, Muhammad K, Adhi MI. Macular thickness by age and gender in healthy eyes using spectral domain optical coherence tomography. *PLoS One* 2012;7:e37638.
- Ooto S, Hangai M, Sakamoto A, Tomidokoro A, Araie M, Otani T, *et al.* Three-dimensional profile of macular retinal thickness in normal Japanese eyes. *Invest Ophthalmol Vis Sci* 2010;51:465-73.
- Sugimoto M, Sasoh M, Ido M, Wakitani Y, Takahashi C, Uji Y. Detection of early diabetic change with optical coherence tomography in type 2 diabetes mellitus patients without retinopathy. *Ophthalmologica* 2005;219:379-85.
- Chan A, Duker JS, Ko TH, Fujimoto JG, Schuman JS. Normal macular thickness measurements in healthy eyes using stratus optical coherence tomography. *Arch Ophthalmol* 2006;124:193-8.
- Strøm C, Sander B, Larsen N, Larsen M, Lund-Andersen H. Diabetic macular edema assessed with optical coherence tomography and stereo fundus photography. *Invest Ophthalmol Vis Sci* 2002;43:241-5.
- Schimel AM, Fisher YL, Flynn HW Jr. Optical coherence tomography in the diagnosis and management of diabetic macular edema: Time-domain versus spectral-domain. *Ophthalmic Surg Lasers Imaging* 2011;42:S41-55.
- Goatman KA. A reference standard for the measurement of macular oedema. *Br J Ophthalmol* 2006;90:1197-202.
- Goebel W, Franke R. Retinal thickness in diabetic retinopathy: Comparison of optical coherence tomography, the retinal thickness analyzer, and fundus photography. *Retina* 2006;26:49-57.
- Antcliff RJ, Stanford MR, Chauhan DS, Graham EM, Spalton DJ, Shilling JS, *et al.* Comparison between optical coherence tomography and fundus fluorescein angiography for the detection of cystoid macular edema in patients with uveitis. *Ophthalmology* 2000;107:593-9.
- Ozdek SC, Erdiç MA, Gürelik G, Aydın B, Bahçeci U, Hasanreisoglu B. Optical coherence tomographic assessment of diabetic macular edema: Comparison with fluorescein angiographic and clinical findings. *Ophthalmologica* 2005;219:86-92.

25. Browning DJ, McOwen MD, Bowen RM Jr., O'Marah TL. Comparison of the clinical diagnosis of diabetic macular edema with diagnosis by optical coherence tomography. *Ophthalmology* 2004;111:712-5.
26. Shahidi M, Ogura Y, Blair NP, Rusin MM, Zeimer R. Retinal thickness analysis for quantitative assessment of diabetic macular edema. *Arch Ophthalmol* 1991;109:1115-9.
27. Abrar F, Rastogi PS, Ansari M. Central macular thickness in diabetic retinopathy – A comparative study. *Ann Int Med Den Res* 2017;3:OT01-4.
28. Oshima Y, Emi K, Yamanishi S, Motokura M. Quantitative assessment of macular thickness in normal subjects and patients with diabetic retinopathy by scanning retinal thickness analyser. *Br J Ophthalmol* 1999;83:54-61.
29. Arora S, Sachdeva A, Goel T, Singh K, Aggarwal M. To study the correlation of mean macular thickness using optical coherence tomography with distant and near visual acuity in patients of diabetic maculopathy. *Int J Res Med Sci* 2018;6:863-8.
30. Diabetic Retinopathy Clinical Research Network, Browning DJ, Glassman AR, Aiello LP, Beck RW, Brown DM, *et al.* Relationship between optical coherence tomography-measured central retinal thickness and visual acuity in diabetic macular edema. *Ophthalmology* 2007;114:525-36.
31. Elzarrug H, Makhlof T, Ruwida MS. Diabetic retinopathy in Libyan patients; severity and relation to systemic risk factors. *IJSR* 2017;10:848-51.
32. Acan D, Calan M, Er D, Arkan T, Kocak N, Bayraktar F, *et al.* The prevalence and systemic risk factors of diabetic macular edema: A cross-sectional study from Turkey. *BMC Ophthalmol* 2018;18:91.
33. Aiello LP, Gardner TW, King GL, Blankenship G, Cavallerano JD, Ferris FL 3rd. Diabetic retinopathy. *Diabetes Care* 1998;21:143-56.
34. Varma R, Bressler NM, Doan QV, Gleeson M, Danese M, Bower JK, *et al.* Prevalence of and risk factors for diabetic macular edema in the United States. *JAMA Ophthalmol* 2014;132:1334-40.
35. Hirano T, Iesato Y, Toriyama Y, Imai A, Murata T. Detection of fovea-threatening diabetic macular edema by optical coherence tomography to maintain good vision by prophylactic treatment. *Ophthalmic Res* 2014;52:65-73.
36. Medina FJ, Callén CI, Rebolleda G, Muñoz-Negrete FJ, Callén MJ, del Valle FG, *et al.* Use of nonmydriatic spectral-domain optical coherence tomography for diagnosing diabetic macular edema. *Am J Ophthalmol* 2012;153:536-430.

ملخص المقال باللغة العربية

تأثير مرض السكري على سماكة البقعة الوسطى المقاسة كميًا باستخدام تصوير التماسك البصري المقطعي في مركز

سيدي حسين الصحي ، بنغازي ، ليبيا

المؤلفون:

ميرفت عبد الرازق سالم عمير، سمر عبد الكريم بوخطوة¹، فاطمة صالح بن خيال²

قسم طب العيون، مركز سيدي حسين الصحي، قسم طب وجراحة العيون، كلية الطب، جامعة بنغازي¹، قسم طب الأسرة والمجتمع،

كلية الطب، جامعة بنغازي²، بنغازي ليبيا

المؤلف المسؤول: سمر عبد الكريم بوخطوة، قسم طب وجراحة العيون، جامعة بنغازي، بنغازي، ليبيا.

البريد الإلكتروني: samar.bukhatwa@uob.edu.ly

مقدمة: وذمة السكري البقعي (DME) تعتبر السبب الأكثر شيوعًا لانخفاض الرؤية في اعتلال الشبكية السكري (DR) واكتشافه يحتاج إلى معدات ومهارات. تصوير التماسك البصري المقطعي (OCT) هو أسلوب موضوعي يمكنه قياس الخاصية المورفولوجية للشبكية والتي تساعد على تحسين التشخيص والعلاج.

الأهداف: أجريت هذه الدراسة لتقييم دور تصوير التماسك البصري المقطعي في فحص وذمة السكري البقعي في مرضى السكري من خلال مقارنتها بالتنظير السريري بالإضافة إلى تقييم العلاقة بين سمك البقعة الصفراء المركزية (CMT) كما تم قياسها بواسطة تصوير التماسك البصري المقطعي وحدة البصر للمريض .

الإعدادات والتصميم: أجريت دراسة بأثر رجعي في مركز سيدي حسين الصحي ، بنغازي في الفترة ما بين 2014 و 2017.

الموضوعات والأساليب: تم استعراض بيانات 393 (786 عين) من مرضى السكري (النوع الثاني). تم استخراج سجلات خصائص الحالات بالإضافة إلى سجلات فحص قاع العين (تم بواسطة عدسة-90 + noncontact الديوبتر). كما تم تقييم سجلات تصوير التماسك البصري المقطعي (سمك البقعي المركزي) وموافقته مع فحص قاع العين وعلاقتها بالتدابير الأخرى. تم تقديم البيانات كترددات وتم إجراء التحليلات الإحصائية باستخدام SPSS Inc. ، إصدار Windows 17.0 .

النتائج: حوالي 537 (82%) من العيون ذات الوذمة البقعية المعتدلة لمرضى السكري والتي تم تشخيصها كذلك بواسطة تصوير التماسك البصري المقطعي، لم تكن تعاني من أي اعتلال الشبكية السكري عند فحصها سريريًا. مع التصوير التماسك البصري المقطعي، وجد أن 555 (85%) ذات الوذمة البقعية السكري المعتدلة كانت تتمتع بحدة بصرية جيدة (لوغاريتم الحد الأدنى لزاوية الدقة 0.3 وأقل). حوالي 10 عيون (71%) مصابة بمرض السكري البقعي الخفيف كانت مصابة بمرض السكري من 10-20 سنة.

الاستنتاجات: تصوير التماسك البصري المقطعي هو وسيلة موسعة يمكن الكشف الموضوعي بها عن وذمة السكري البقعي في وقت مبكر قبل أن يؤثر على رؤية المرضى، ويوصى بشدة أن يكون هذا هو الأسلوب المفضل لكشف وفحص وذمة السكري البقعي في المرضى الليبيين.

الكلمات المفتاحية: بنغازي ، سماكة البقعة المركزية ، اعتلال الشبكية السكري ، ليبيا ، تصوير التماسك البصري المقطعي.