

Case Report

Access this article online
Quick Response Code:

Website: www.jlponline.org
DOI: 10.4103/JLP.JLP_53_17

Hypertriglyceridemia-induced acute pancreatitis with diabetic ketoacidosis: A rare presentation of type 1 diabetes mellitus

Prabhat Kumar, Abhishek Sakwariya, Amit Ranjan Sultania, Renu Dabas

Abstract:

Diabetic ketoacidosis (DKA) is a frequently encountered complication of diabetes mellitus. DKA is an insulin deficit state and results in moderate to severe hypertriglyceridemia (HTG). HTG is the third leading cause of acute pancreatitis (AP) and often goes unnoticed. The triad of DKA, HTG, and AP is rarely seen, and literature on the same is sparse. We report a case of AP which was due to DKA-induced secondary HTG in an adult with previously undiagnosed type 1 diabetes. His HbA1c was significantly raised, and C-peptide level was low, confirming chronic hyperglycemia. He was treated successfully with insulin infusion, intravenous crystalloid, and analgesics.

Key words:

Chylomicron, heparin, insulin, plasmapheresis

Introduction

Diabetic ketoacidosis (DKA) is an acute complication of uncontrolled diabetes and is commonly encountered in people having type 1 diabetes. DKA could also be the initial manifestation, leading to the diagnosis of diabetes. The common precipitating factor includes infection, insulin discontinuation, and tissue ischemia.^[1] Nausea and vomiting is the most common symptom, followed by pain abdomen, which mimics pain of acute pancreatitis (AP). DKA can be complicated by cerebral edema, venous thrombosis, acute respiratory distress syndrome, and hypertriglyceridemia (HTG).^[2] The levels of triglyceride (TG) can be high enough to cause AP. This triad of diabetes, DKA, and HTG-induced pancreatitis is rarely seen in adults, and only a few cases have been reported so far.^[3]

This is an open access article distributed under the terms of the Creative Commons Attribution-NonCommercial-ShareAlike 3.0 License, which allows others to remix, tweak, and build upon the work non-commercially, as long as the author is credited and the new creations are licensed under the identical terms.

For reprints contact: reprints@medknow.com

Case Report

A 23-year-old student with no prior comorbidities presented in emergency room with complaints of sudden onset, severe epigastric pain abdomen which was radiating to back and was associated with vomiting for the last 2 days. He was a teetotaler and never had similar episode in the past. He took some over the counter medication for these symptoms, but pain abdomen persisted. On examination, pulse rate - 120/min, blood pressure - 110/70 mmHg, and respiratory rate was 24/min. There was tenderness in the epigastric region, and bowel sounds were sluggish. Air entry was reduced on the left side of chest. A possibility of AP was kept, and blood investigations were ordered. Serum amylase and lipase levels were 1209 U/L and 1228 U/L, respectively. Rest of the blood investigations such as hemogram, renal function test, liver

How to cite this article: Kumar P, Sakwariya A, Sultania AR, Dabas R. Hypertriglyceridemia-induced acute pancreatitis with diabetic ketoacidosis: A rare presentation of type 1 diabetes mellitus. J Lab Physicians 2017;9:329-31.

Department of Medicine,
PGIMER and Dr RML
Hospital, New Delhi, India

Address for correspondence:

Dr. Prabhat Kumar,
Department of
Medicine, PGIMER
and Dr RML Hospital,
New Delhi - 110 001,
India.

E-mail: drkumar.prabhat@gmail.com

Submission: 24-03-2017

Accepted: 05-05-2017

function test, and serum electrolytes were normal. However, blood sugar was 310 mg/dl and urinalysis showed ketonuria (7.8 mmol/l) and glycosuria (28 mmol/l). Arterial blood gas analysis was suggestive of metabolic acidosis with a pH of 7.20, bicarbonate - 12.4 mEq/l and pCO₂ - 20.2 mmHg. Ultrasound abdomen showed mildly bulky heterogeneous pancreas with peripancreatic fluid stranding, and there was no evidence of cholelithiasis. Contrast-enhanced computed tomography (CT) abdomen revealed bulky pancreas with extensive peripancreatic inflammatory fat stranding, which was suggestive of AP with a CT severity index of 6 [Figure 1]. The liver showed fatty infiltration, and gall bladder along with bile ducts was normal. Bedside Index of Severity in Acute Pancreatitis score for AP was 2. To look for etiology of AP, a lipid profile was done on the first day of admission which showed TG level of 1100 mg/dl, low-density lipoprotein - 105 mg/dl, and high-density lipoprotein - 40 mg/dl.

He was kept nil orally; insulin infusion was started at rate of 0.1 U/kg/h after a bolus dose of 0.1 U/kg along with intravenous fluids. Meanwhile, other tests for diabetes were ordered, HbA1c was 10.7%, C-peptide levels were low (0.64 ng/ml), anti-insulin antibodies, and anti-glutamic acid decarboxylase antibodies were negative. The patient showed considerable improvement in his symptoms and was shifted on long-acting subcutaneous insulin on 3rd day of admission. Blood investigations done on 5th day of admission showed normal lipase and amylase levels, TG level had decreased to 430 mg/dl, and urine for ketone bodies was negative. A final diagnosis of type 1 diabetes with DKA- and HTG-induced AP was made. He was discharged on twice daily subcutaneous insulin injection and had normal lipid profile after 1 month of follow-up.

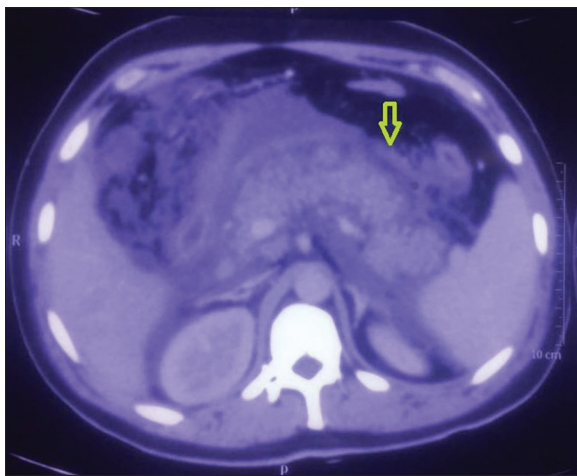


Figure 1: Contrast-enhanced computed tomography abdomen showing bulky pancreas with peripancreatic fat stranding

Discussion

The diagnosis of AP in DKA is plagued by many challenges. First, epigastric pain is quiet common in DKA, and one-fourth of these patients have elevated levels of serum lipase and amylase without any clinical or radiological evidence of pancreatitis.^[4] A three-fold rise in serum lipase and amylase levels is considered specific for the diagnosis of AP, but in HTG-induced pancreatitis, the enzyme levels can remain normal too. Almost 50% cases of HTG-induced pancreatitis have normal level of amylase due to lipemic content of blood, which interferes with calorimetric assay of amylase and presence of inhibitors of assay in plasma.^[5] AP with DKA and normal level of serum lipase have been also described.^[6]

HTG is the third most common cause of AP, and almost 5% of these cases are attributed to HTG.^[7] DKA is an insulin deficit state which promotes lipolysis and release of free fatty acids from adipose tissue and muscle. These free fatty acids are further converted into very low density lipoprotein (VLDL) by liver, but their clearance from blood is also reduced due to low levels of lipoprotein lipase (LPL), resulting in HTG.^[8] TG levels above 1000 mg/dl often triggers an episode of AP. The proposed mechanism is release of free fatty acid from TGs in pancreatic capillaries by lipase, which further activates pancreatic enzyme trypsinogen and causes free radical damage to the pancreatic tissue.^[9] Serum TG level should be measured within 24 h of onset of symptom as influx of chylomicrons in blood is reduced during fasting state, and any delay in measurement could lead to falsely low levels. The TG levels were found to be normal after 72 h of fasting in HTG-induced pancreatitis.^[10]

The treatment of HTG-induced AP is similar to any other cause of AP and includes adequate hydration, pain management, and decreased oral intake. There are no specific treatment guidelines for HTG, but insulin infusion is often effective in decreasing TG levels. LPL activity is increased by insulin infusion which degrades TG-rich chylomicrons and VLDL particles.^[11] Heparin infusion is other modality of treatment which acts by releasing endothelial LPL in circulation. However, this is often followed by delayed HTG as this action of heparin is transient, and it further depletes plasma stores of LPL. Plasmapheresis is not so frequently used for HTG, and there is no strong evidence available to recommend its routine use in these patients. However, several case reports have shown promising results when plasmapheresis is given within 48 h of presentation.^[12]

Financial support and sponsorship

Nil.

Conflicts of interest

There are no conflicts of interest.

References

1. Chiasson JL, Aris-Jilwan N, Bélanger R, Bertrand S, Beaugard H, Ekoé JM, *et al.* Diagnosis and treatment of diabetic ketoacidosis and the hyperglycemic hyperosmolar state. *CMAJ* 2003;168:859-66.
2. Kota S, Jammula S, Kota S, Meher L, Modi K. Acute pancreatitis in association with diabetic ketoacidosis in a newly diagnosed type 1 diabetes mellitus patient; case based review. *IJCCI* 2012;4:54-60.
3. Singla AA, Ting F, Singla A. Acute pancreatitis secondary to diabetic ketoacidosis induced hypertriglyceridemia in a young adult with undiagnosed type 2 diabetes. *JOP* 2015;16:201-4.
4. Yadav D, Nair S, Norkus EP, Pitchumoni CS. Nonspecific hyperamylasemia and hyperlipasemia in diabetic ketoacidosis: Incidence and correlation with biochemical abnormalities. *Am J Gastroenterol* 2000;95:3123-8.
5. Warshaw AL, Bellini CA, Lesser PB. Inhibition of serum and urine amylase activity in pancreatitis with hyperlipemia. *Ann Surg* 1975;182:72-5.
6. Nair S, Yadav D, Pitchumoni CS. Association of diabetic ketoacidosis and acute pancreatitis: Observations in 100 consecutive episodes of DKA. *Am J Gastroenterol* 2000;95:2795-800.
7. Fortson MR, Freedman SN, Webster PD 3rd. Clinical assessment of hyperlipidemic pancreatitis. *Am J Gastroenterol* 1995;90:2134-9.
8. Kota SK, Krishna SV, Lakhtakia S, Modi KD. Metabolic pancreatitis: Etiopathogenesis and management. *Indian J Endocrinol Metab* 2013;17:799-805.
9. Tsuang W, Navaneethan U, Ruiz L, Palascak JB, Gelrud A. Hypertriglyceridemic pancreatitis: Presentation and management. *Am J Gastroenterol* 2009;104:984-91.
10. Dominguez-Muñoz JE, Malfertheiner P, Ditschuneit HH, Blanco-Chavez J, Uhl W, Büchler M, *et al.* Hyperlipidemia in acute pancreatitis. Relationship with etiology, onset, and severity of the disease. *Int J Pancreatol* 1991;10:261-7.
11. Goldberg IJ. Lipoprotein lipase and lipolysis: Central roles in lipoprotein metabolism and atherogenesis. *J Lipid Res* 1996;37:693-707.
12. Lennertz A, Parhofer KG, Samtleben W, Bosch T. Therapeutic plasma exchange in patients with chylomicronemia syndrome complicated by acute pancreatitis. *Ther Apher* 1999;3:227-33.