

Case Report

Access this article online

Quick Response Code:



Website:

www.jlponline.org

DOI:

10.4103/JLP.JLP_114_17

Fine-needle aspiration cytology of granulocytic sarcoma presenting as a breast lump – Report of a rare case with a comprehensive literature search

Abhishek Sharma, Anjan Kr. Das¹, Subrata Pal, Subodh Bhattacharyya

Abstract:

Myeloid sarcoma is a neoplasm of myeloid cells that can arise before or concurrent with or may follow acute myeloid leukemia. Very rarely, it can present as an isolated breast lump. We have diagnosed a case of myeloid sarcoma by fine-needle aspiration cytology (FNAC), in a 52-year-old woman who presented with the right-sided breast lump. FNAC showed hypercellular smears with immature myeloid cells few neutrophils and many large round cells with high nuclear-cytoplasmic ratio, prominent nucleoli and a moderate amount of granular cytoplasm. The blast cells were myeloperoxidase positive and complete blood count, and peripheral blood examination were normal. We report this case for its rarity and as a note of caution to a pathologist to consider myeloid sarcoma in the differential diagnosis of breast lump to provide the correct diagnosis and avoid incorrect treatment of a curable disease.

Key words:

Acute myeloid leukemia, breast, cytology, myeloid sarcoma

Introduction

Myeloid (granulocytic) sarcoma is a tumor mass including the myeloid blast with or without maturation occurring at an anatomical site other than bone marrow.^[1,2] Myeloid sarcoma is a relatively common in certain particular type of acute myeloid leukemia (AML) with distinct cytogenetic abnormalities like AML with maturation and t(8;21) (q22;q22), acute myelomonocytic leukemia with eosinophilia and Inv (16)(p13q22) or t(16;16) (p13;q22) and AML associated with 11q23 abnormalities.^[1] Myeloid sarcoma also may develop in cases of Chronic myeloid leukemia, myeloproliferative disorders and myelodysplastic syndrome. Myeloid sarcoma presenting as breast mass is relatively uncommon.^[1-3] In this case, we present a 52-year-old women presenting of a painless right sided breast lump which

was diagnosed as myeloid sarcoma on fine-needle aspiration cytology (FNAC) with the help of myeloperoxidase (MPO) stain.

Case Report

A 52-year-old woman presented to surgery outpatient department (OPD) with a history of painless right-sided breast lump for the past 1 month. Clinical examination showed large diffuse firm mass measuring 8 cm × 6 cm with a glistening of skin and venous prominence [Figure 1]. There was no associated lymphadenopathy, but nipples were slightly retracted. She had no other symptoms, was otherwise in good health and had no relevant family or medical history. On ultrasound evaluation, it was a homogenous hypoechoic masses with well-defined margins.

FNAC was performed which yielded blood mixed aspirate. Both air-dried and

This is an open access article distributed under the terms of the Creative Commons Attribution-NonCommercial-ShareAlike 3.0 License, which allows others to remix, tweak, and build upon the work non-commercially, as long as the author is credited and the new creations are licensed under the identical terms.

For reprints contact: reprints@medknow.com

How to cite this article: Sharma A, Das AK, Pal S, Bhattacharyya S. Fine-needle aspiration cytology of granulocytic sarcoma presenting as a breast lump – Report of a rare case with a comprehensive literature search. J Lab Physicians 2018;10:113-5.

Department of Pathology,
College of Medicine and
Sagore Dutta Hospital,
¹Department of Pathology,
Calcutta National
Medical College, Kolkata,
West Bengal, India

Address for correspondence:

Dr. Subrata Pal,
Sahid Colony, Panihati,
North 24 Parganas,
West Bengal, India.
E-mail: subratapal1985@
gmail.com

Submission: 14-06-2017

Accepted: 27-09-2017

wet-fixed smear was made. The smear was stained with May-Grünwald Giemsa and Papanicolaou stain. Smear revealed high cellularity with cells arranged in sheets and scattered singly. Majority of the cells were immature myeloid cells few neutrophils and many large round cells with high nuclear-cytoplasmic ratio, prominent nucleoli and a moderate amount of granular cytoplasm [Figure 2a]. Few cells showed scanty basophilic cytoplasm. In view of immature myeloid cells, MPO stain was done on smears, and it showed MPO positive granules in the cells [Figure 2b]. The diagnosis of myeloid sarcoma of the breast was done. Complete blood count was performed which showed a hemoglobin level of 11.9 g/dl with total white blood cell count of 7590/cumm. Differential count revealed neutrophils-75%, lymphocytes-21%, monocytes-3%, eosinophils-1%, basophils-0%. No abnormal cells were found in peripheral blood smears. Platelet count was 271,000/cumm and bone marrow aspirate and biopsy were normal. Further biopsy and histopathological examination showed the tumor was composed of mononuclear cells arranged in sheets and cords with round to oval vesicular nuclei and occasional prominent nucleoli. Immunohistochemically, the case was negative for estrogen receptor, progesterone receptor, human epidermal growth factor receptor 2 neu and cytokeratin but positive for CD34 and CD117. She was referred to the Department of Radiotherapy. She was treated with lumpectomy and postoperative cytarabine (1 g/m² cytarabine/12 h on days 1–3) and idarubicin (12 mg/m² idarubicin daily on days 1–2) based consolidation chemotherapy for three cycles of and achieved complete remission. The patient was followed by ultrasound scans of the breast, chest X-ray and bone marrow aspiration in every 3 months. She was disease free even after 1 year of therapy.

Discussion

Myeloid sarcoma presenting as a breast mass is uncommon.^[1-3] An extensive search of the previous literature revealed 67 previously reported cases, of which 66 occurred in women and one case occurred in man. Thirty-seven of these previously reported cases are tabulated in Table 1, with a wide age range of 16–72 years [Table 1]. Very few cases have been reported as an isolated mass with no significant history or subsequent development of AML while on clinical follow-up.^[4] All the patients presented as asymptomatic breast mass either detected by self-examination or by mammographic studies. Right breast involvement is more common than the left while single case has been reported which was bilateral. The cases usually present with a lump and may be associated symptoms pain, but nipple inversion and discharge are usually absent.^[4,5] In our case, it was a solitary firm breast lump without pain, nipple change, and secretion.

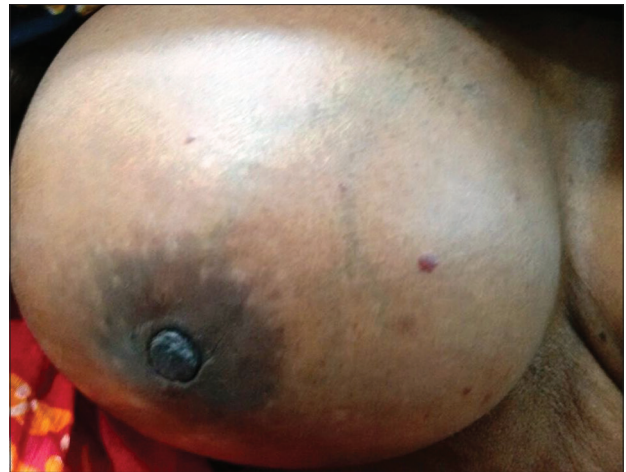

Figure 1: The breast lump with glistening of skin and venous prominence

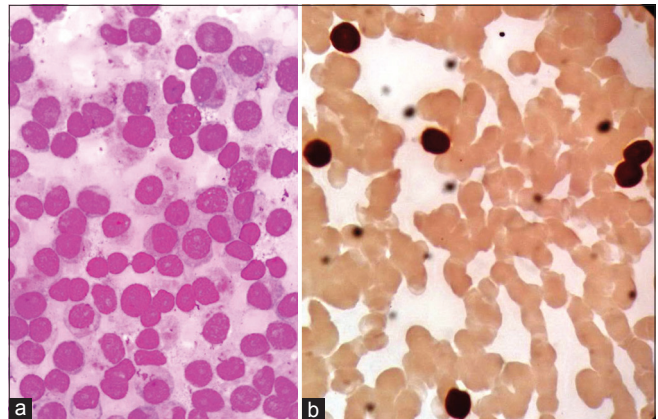


Figure 2: (a) Photomicrograph of cytology showing dispersed myeloid blast cells having small amount of granular basophilic cytoplasm, large round nuclei with prominent nucleoli in the case of myeloid sarcoma (Leishman and Giemsa stain, ×40 view). (b) Photomicrograph showing myeloperoxidase positive myeloblasts in the cytology smears (myeloperoxidase stain, ×40 view)

Cytology of myeloid sarcomas shows hypercellular smears comprised of uniform population of immature myeloid cells or myeloblasts. The cells have scanty granular basophilic cytoplasm, round nuclei with prominent one to three nucleoli. There may be Auer rods in the cytoplasm and some eosinophilic precursors in the cytology smears.^[5] The myeloid cells are positive for MPO, CD13, CD34, CD117, and CD68.^[5] In our case, cytomorphology was classical of myeloid sarcoma and confirmation done by MPO positivity.

This case is an isolated case of myeloid sarcoma without the involvement of bone marrow. The occurrence of myeloid sarcoma in the breast in an aleukemic patient is extremely rare and causes diagnostic dilemma to the pathologist.^[5] Campidelli *et al.* studied 25 cases of myeloid sarcoma and found seven cases of *de novo* occurrence without any involvement of the bone marrow and peripheral blood.^[6] Diagnosis of myeloid sarcoma should be kept in mind while reporting cytological

Table 1: Literature review of previous cases of myeloid sarcoma of breast

Authors	Age and sex	Clinical features	Associated myeloid neoplasm
Geelhoed (1973)	16 years female	Left breast	AML
Sears (1976)	21 years female	Left breast	AML
Seo (1977)	66 years female	Bilateral	AML
Krause (1979)	28 years female		AML
Cassi (1984)	27 years female	Left breast	AML
Gartenhaus (1985)	51 years female		AML
Eshghabadi (1986)	40 years female	Right breast	AML
Meis (1986)	37 years female	Left breast	AML
Pettinato (1988)	56 years female	Left breast	Aleukemic
Chua (1989)	23 years female	Right breast	AML
Silverman JF (1990)	30 years female	Breast lump	MPD
Barloon (1993)	66 years female	Left breast	AML after 48 months
Doval (1996)	25 years female	Right breast	AML after 2 months
Hiorns (1997)	24 years female	Left breast	AML
Barker (1998)	51 years female	Right breast	
Jung (1998)	28 years female	Right breast	AML
Menasce (1999)	33 years female	Undefined breast mass	AML
Breccia (2000)	71 years female		
Joo (2000)	42 years female	Left breast	AML
Deruelle (2001)	44 years female	Right breast	
Quintas (2003)	31 years female	Right breast	
Shea (2004)	55 years female	Bilateral	
Hill (2004)	60 years female	Right breast	
Dutta Roy S (2004)	72 years female	Left breast	AML
Valbuena (2005)	31 years female	Undefined breast mass	
D Costa (2007)	45 year female	Left breast	Aleukemic
Thachil (2007)	26 years female	Right breast	AML
Azim (2008)	45 years female	Left breast	
Iwagami (2009)	48 years female	Both breast	AML M2
Vela-Chávez (2010)	29 years female	Right breast	
Delporte (2010)	65 years female	Right breast	
Jelic Puskaric et al. (2010)	25 years female	Left breast	AML
Fu J (2013)	59 and 37 year female	Left breast (both)	AML M4 and M6
Nalwa A (2015)	33 years female	Right breast	Aleukemic
Huang XE (2015)	58 years female	Left breast	AML M6
Fernandes V (2016)	45 years female	Left breast	AML

AML = Acute myeloid leukemia, MPD = Myeloproliferative disorder

smears as it is often misdiagnosed due to its rarity.^[7] The commonest misinterpretations are lymphoma, breast carcinoma, melanoma, or sarcoma.^[1,7] In literature, it has been documented that a series of 61 patients with extramedullary myeloid cell tumors which were reviewed, the majority were originally diagnosed with lymphoma.^[1,8]

The treatment approaches for granulocytic sarcoma of the breast is controversial. The most of the studies concluded that all patients should be treated with mastectomy

or lumpectomy plus systemic chemotherapy.^[8,9] The present case was treated with lumpectomy and systemic chemotherapy, and no local recurrence was identified in the breast 1 year later.

In conclusion, breast lump as a presentation of myeloid sarcoma is very rare. Cytology plays an important role in the diagnosis which at times may be confusing, and it closely mimics lymphoma. The case report emphasized on clinical utility and accuracy of FNAC in making the diagnosis of myeloid sarcoma which is crucial to proper patient management. It is therefore very important to consider myeloid sarcoma of the breast in the differential diagnosis of breast lump to provide early correct diagnosis and avoid incorrect treatment of a curable condition.

Declaration of patient consent

The authors certify that they have obtained all appropriate patient consent forms. In the form the patient(s) has/have given his/her/their consent for his/her/their images and other clinical information to be reported in the journal. The patients understand that their names and initials will not be published and due efforts will be made to conceal their identity, but anonymity cannot be guaranteed.

Financial support and sponsorship

Nil.

Conflicts of interest

There are no conflicts of interest.

References

1. Thachil J, Richards RM, Copeland G. Granulocytic sarcoma - A rare presentation of a breast lump. *Ann R Coll Surg Engl* 2007;89:W7-9.
2. Ngu IW, Sinclair EC, Greenaway S, Greenberg ML. Unusual presentation of granulocytic sarcoma in the breast: A case report and review of the literature. *Diagn Cytopathol* 2001;24:53-7.
3. Mandal S, Jain S, Khurana N. Breast lump as an initial manifestation in acute lymphoblastic leukemia: An unusual presentation. A case report. *Hematology* 2007;12:45-7.
4. Valbuena JR, Admirand JH, Gualco G, Medeiros LJ. Myeloid sarcoma involving the breast. *Arch Pathol Lab Med* 2005;129:32-8.
5. Nalwa A, Nath D, Suri V, Jamaluddin MA, Srivastava A. Myeloid sarcoma of the breast in an aleukemic patient: A rare entity in an uncommon location. *Malays J Pathol* 2015;37:63-6.
6. Campidelli C, Agostinelli C, Stitson R, Pileri SA. Myeloid sarcoma: Extramedullary manifestation of myeloid disorders. *Am J Clin Pathol* 2009;132:426-37.
7. Shukla R, Pooja B, Radhika S, Nijhawan R, Rajwanshi A. Fine-needle aspiration cytology of extramammary neoplasms metastatic to the breast. *Diagn Cytopathol* 2005;32:193-7.
8. Huang XE, Li YJ, Zhou XD. Granulocytic sarcoma of the breast: A case report. *Oncol Lett* 2015;10:2447-9.
9. Paydas S, Zorludemir S, Ergin M. Granulocytic sarcoma: 32 cases and review of the literature. *Leuk Lymphoma* 2006;47:2527-41.