

Dialysis Shunt Thrombectomy Utilizing a Rotational Thrombectomy Device in Patients with Pseudoaneurysms

Abstract

Aims: To assess the safety and efficacy of dialysis shunt thrombectomy utilizing a rotational thrombectomy device in patients with pseudoaneurysms refractory to declot by conventional treatments. **Methods:** Between July 2016 and August 2019, 34 dialysis shunt thrombectomies were retrospectively examined in 29 individual patients. All patients presented with pseudoaneurysms and clotted accesses that were refractory to angioplasty balloon sweeps (“push-pull”) to restore patency. The Cleaner® rotational thrombectomy device was used as a bail-out in an attempt to restore patency to the clotted shunt. Procedure success, complications, primary patency, primary-assisted patency, secondary patency, average number of shunt pseudoaneurysms, and average pseudoaneurysm size were documented and analyzed. **Results:** Thirty-three of the 34 (97%) thrombectomies were successful in restoring patency and facilitating same-day hemodialysis. An average of 1.5 pseudoaneurysms were present per patient (range 1–3 pseudoaneurysms, standard deviation [SD] 0.65 pseudoaneurysms), with an average size of 15.0 mm (range 9.4–31.1 mm, SD 4.87 mm). Postprocedural complications occurred in 14.7% of the cases, none of which were definitively device related. Primary patency to the time of data collection was achieved in 29% of the cases, and the average primary patency for these cases was 124.5 days (range 10–946 days, SD 186.9 days). The average primary-assisted patency was 126.8 days (range 1–564 days, SD 169.8 days). Dialysis accesses were eventually abandoned or surgically revised in ten instances, resulting in an average secondary patency of 157.5 days (range 6–712 days, SD 257 days). **Conclusions:** In patients with pseudoaneurysms, rotational thrombectomy with the Cleaner® device appeared to be a safe and effective option for restoring patency to thrombosed dialysis accesses refractory to standard push-pull techniques with angioplasty balloons.

Keywords: Dialysis intervention, patency, pseudoaneurysm, shunt, thrombectomy

Introduction

With a rising number of patients in the United States undergoing dialysis and an increasing percentage of dialysis patients utilizing arteriovenous fistulae as their primary access, the maintenance and preservation of these fistulae will continue to represent an important aspect of interventional radiology practice.^[1] Thrombus obstructing fistula patency is a common threat to fistula viability and is usually managed percutaneously, with many articles describing this as preferable to surgical intervention for initial treatment. Many methods of percutaneous thrombectomy have been described, including hydrolysis, thromboaspiration, angioplasty, balloon pass-through, and administration of thrombolytic agents.^[1-3]

This is an open access journal, and articles are distributed under the terms of the Creative Commons Attribution-NonCommercial-ShareAlike 4.0 License, which allows others to remix, tweak, and build upon the work non-commercially, as long as appropriate credit is given and the new creations are licensed under the identical terms.

For reprints contact: WKHLRPMedknow_reprints@wolterskluwer.com

These conventional methods allow for efficient restoration of shunt patency in the vast majority of cases. However, a selected number of shunts are refractory to treatment with the usual methods; among these cases are those with significant pseudoaneurysms. Contrary to a true aneurysm, a pseudoaneurysm does not exhibit a normal vascular wall structure, with some papers suggesting that pseudoaneurysms can be thought of simplistically as hematomas which communicate with the shunt lumen.^[4] These pseudoaneurysms can result in adherent clot which is often unable to be cleared through conventional methods.^[5-7]

Multiple mechanical thrombectomy devices currently exist to assist with problematic declots, employing a variety of technologies, including high-velocity water jets, ultrasound, vacuum aspiration,

How to cite this article: Webb A, Zacharias K, Ciolek P, Webb T, Ahmed O. Dialysis shunt thrombectomy utilizing a rotational thrombectomy device in patients with pseudoaneurysms. Arab J Interven Radiol 2020;4:87-91.

**Anderson Webb,
Kurt Zacharias,
Paul Ciolek¹,
Thomas Webb²,
Osman Ahmed³**

Departments of Radiology and ³Interventional Radiology, University of Chicago Medical Center, ¹Department of Radiology, University of Chicago, Chicago, IL, ²Department of Radiology, Belmont University, Smithville, TN, USA

Received: 02-04-2020

Revised: 25-04-2020

Accepted: 14-05-2020

Online Published: 10-07-2020

Address for correspondence:

Dr. Anderson Webb,
Department of Radiology,
University of Chicago Medical
Center, 5841 S. Maryland
Ave – MC 2026, Chicago,
IL 60637, USA.
E-mail: anderson.webb@
uchospitals.edu

Access this article online

Website: www.arabjir.com

DOI: 10.4103/AJIR.AJIR_8_20

Quick Response Code:



mechanical coring, and sweeping mechanisms.^[8,9] One such device, the Cleaner[®] rotational thrombectomy device, utilizes a rotating, wall-contacting, sinusoidal coil wire to macerate clots. While commonly used, a paucity of data currently exists on this device for arteriovenous access maintenance, with only a handful of published studies which are limited to its use in deep vein thrombosis.^[10-12] This study therefore aimed to assess the safety and efficacy of arteriovenous dialysis shunt thrombectomy utilizing the Cleaner[®] rotational thrombectomy device in patients with pseudoaneurysms and clotted accesses refractory to conventional thrombectomy methods.

Methods

Patients

A retrospective study approved by the institutional review board was conducted on all patients undergoing percutaneous thrombectomy utilizing the Cleaner[®] device (Argon Medical Devices; Frisco, Texas, USA) who had clotted hemodialysis shunts (i.e., fistulae and grafts) and pseudoaneurysms between July 2016 and August 2019 at a tertiary care academic hospital. Although the etiology of these pseudoaneurysms is not well elucidated, it is thought that the majority of the pseudoaneurysms in our patient population were related to multiple needle punctures at the cannulation zone or central venous stenosis. The standard institutional approach to diagnosing a thrombosed hemodialysis shunt was made clinically by physical examination, indicating a lack of thrill. As per the institutional standard, mechanical thrombectomy devices are not used routinely to treat clotted hemodialysis shunts but rather as a bail-out when conventional methods did not yield a satisfactory result.

In the time period studied, there were 34 procedures performed on patients with pseudoaneurysms and clotted hemodialysis accesses that were refractory to angioplasty balloon sweeps (i.e., “push-pull” method) for patency restoration. Rotational thrombectomy was used as a bail-out in all instances in an attempt to restore patency to the clotted shunt after inadequate restoration of flow and/or persistent shunt thrombosis. Pseudoaneurysm sizes were measured fluoroscopically. Standard institutional protocol for performing percutaneous thrombectomy on thrombosed dialysis arteriovenous shunts included correction of serum potassium to a level <6 mmol/L and an international normalized ratio <3.

Demographic and procedural variables of the 29 patients’ cohort (some patients had shunts that were interrogated multiple times) were recorded from the patients’ electronic medical records and picture archiving and communication system database [Table 1]. Complications were documented according to the Society of Interventional Radiology Quality

Improvement guidelines for percutaneous image-guided management of the thrombosed or dysfunctional dialysis circuit.^[13] All thrombectomy procedures were performed by one of the seven board-certified interventional radiologists with at least 5 years of experience. The follow-up duration was a minimum of 6 weeks for all patients.

Rotational thrombectomy device

The Cleaner[®] rotational thrombectomy device^[14] [Figure 1] is a single use device consisting of a 9 or 15 mm amplitude sinusoidal wire attached to a battery-operated mechanical generator. It is activated by a button and designed to dislodge and macerate wall-adherent thrombus. The system comes in both 6 (0.035”) and 7 Fr (0.044”) systems and is not placed over a wire. The device was typically advanced beyond the point of interest and pulled back over the thrombus while applying gentle compressive pressure over the pseudoaneurysm to increase surface contact with the device.

Table 1: Variables of 29 patient cohort

| Variables | n (%) or average (range) |
|--|--------------------------|
| Demographics | |
| Male | 13 (44.83) |
| Female | 16 (55.17) |
| Age (years) | 64 (35-84) |
| Comorbidities | |
| Hypertension | 24 (82.76) |
| Hyperlipidemia | 22 (75.87) |
| Coronary artery disease and/or heart failure | 13 (44.83) |
| Medical therapy | |
| Aspirin | 20 (68.97) |
| Clopidogrel (Plavix) | 6 (20.69) |
| Anticoagulation | 5 (17.24) |
| Interventions | |
| Grafts | 19 (55.89) |
| Fistulae | 15 (44.12) |

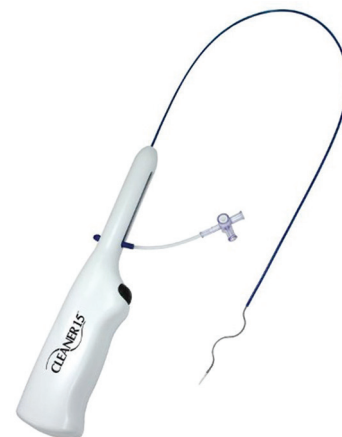

Figure 1: Cleaner rotational thrombectomy device

Procedure technique

Standard technique included the “push-pull” method.^[2] Briefly, thrombosed hemodialysis shunts containing pseudoaneurysms were accessed with a micropuncture system pointing toward the venous limb and peripheral to the aneurysm when feasible. After confirming central venous patency with venography, a second puncture was made in a similar fashion pointing toward the arterial limb. Following balloon maceration and sweep in the venous direction, a 6 mm balloon catheter (Mustang®; Boston Scientific, Marlborough, MA, USA) was used to pull the arterial plug. Typically, 4 mg of tissue plasminogen activator (tPA) was administered throughout the clotted venous outflow tract before maceration and/or sweep. When aneurysms within the shunts were found to be incompletely patent with residual clot, a short 6 or 7 Fr sheath was then placed within the antegrade access site. A Cleaner® (Argon Medical; Frisco, Texas, USA) rotational thrombectomy device [Figure 2] was placed through the sheath, and mechanical thrombectomy was then performed within the pseudoaneurysms of the outflow tract. The Cleaner® device was used based on the institutional preference and acquisition of the device. We believe that its advantages include simplicity of use, low profile (i.e., 6 or 7 Fr), increased wall apposition within pseudoaneurysms due to its sinusoidal design, and safety of passing the device through stents. One disadvantage of utilizing the Cleaner® device was the additional cost compared to traditional “push-pull” methods. As many of these pseudoaneurysms were related to multiple needle punctures at the cannulation zone, the placement of stent grafts was deemed inappropriate as they would preclude future cannulations. Following use of the Cleaner® device, an angiogram was performed to confirm patency (i.e., technical success). Dialysis sheaths were placed into the shunt and patients were subsequently sent to acute dialysis. Clinical success was documented by a thrill at procedure completion and a successful dialysis session

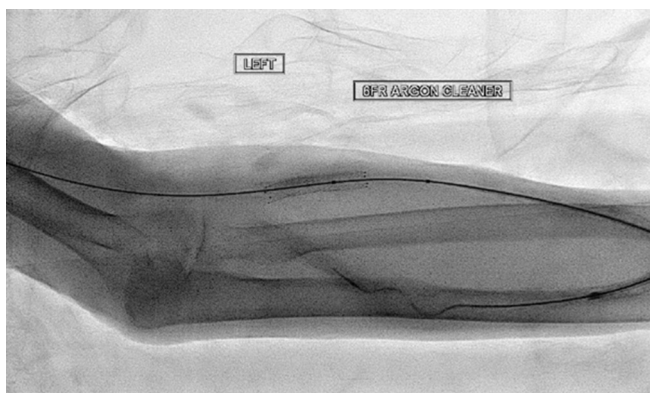


Figure 2: Cleaner rotational thrombectomy device being used to declot a hemodialysis shunt pseudoaneurysm

Outcome definitions

Technical success was defined as restored graft patency at the conclusion of the procedure. Clinical success was defined as a palpable thrill at the conclusion of the procedure and successful same-day hemodialysis. Primary patency was defined as the time (in days) between rotational thrombectomy device utilization and time to any subsequent intervention of the hemodialysis access (e.g., rethrombosis, new stenosis). Primary-assisted patency was defined as the time between the rotational thrombectomy device being used and the next time the hemodialysis access thrombosed. Secondary patency was defined as the time between the rotational thrombectomy device being used and the hemodialysis access being abandoned or surgically revised

Statistical analysis

Data were recorded and analyzed in Microsoft® Excel 2016 (Microsoft®, Redmond, WA, USA). Procedure success rate, number of complications, average primary patency, average primary-assisted patency, average secondary patency, average number of shunt aneurysms, and average aneurysm size were reported. Standard deviations were calculated where appropriate.

Results

Thirty-three of the 34 (97%) thrombectomy procedures were successful in restoring patency and facilitating same-day hemodialysis. An average of 1.5 pseudoaneurysms were present per patient (range 1–3 pseudoaneurysms, SD 0.66 pseudoaneurysms), with an average size of 15.0 mm (range 9.4–31.1 mm, SD 4.92 mm). Of these pseudoaneurysms, 8 of 51 (15.7%) were chronically thrombosed, which were defined as those pseudoaneurysms that extended to the skin. A total of 5 (14.7%) documented postprocedural complications occurred, including one episode of bleeding which prompted activation of a rapid response team [Table 2]. Although pain, swelling, and bleeding at the graft site are procedural complications, it is not evident that these complications are specifically related to the Cleaner® device as these findings are not uncommon following declots of thrombosed hemodialysis shunts, even when the conventional methods are used.

Three procedures could not be included in the calculation for patency as one procedure was unsuccessful, one

Table 2: Complications

| |
|--|
| Postprocedural pain and swelling at access site |
| Postprocedural anxiety attack, will need anesthesia for subsequent declots |
| Intraprocedural aspiration with postprocedural emesis, gingival bleeding, and access site bleeding |
| Postprocedural pain and swelling at access site |
| Postprocedural access site bleeding, prompting rapid response team activation |

patient was lost to follow-up, and one patient expired approximately 8 months after thrombectomy without any subsequent procedure-relevant documentation. The average primary patency for the 31 cases was 124.5 days (range 1–946 days, SD 186.9 days). Nine (29%) of these cases resulted in primary patency to the time of data collection, suggesting that the calculated average may be artificially low. Furthermore, one of these procedures resulted in a primary patency of only 1 day as the procedure was performed the day before data collection, suggesting that the calculated average again may be artificially low. Twenty-two of the original mechanical thrombectomy cases required a subsequent intervention due to inability to achieve adequate flow rates for dialysis that resulted in an average primary-assisted patency of 126.7 days (range 1–564 days, SD 169.8 days). Ten cases resulted in dialysis accesses that were eventually abandoned or surgically revised, resulting in an average secondary patency of 157.5 days (range 11–712 days, SD 257.0 days).

Discussion

Percutaneous thrombectomy remains a first-line treatment for thrombosed arteriovenous shunts, with surgical intervention less often considered.^[15] Hemodialysis access failure is a large contributor to patient morbidity and mortality, contributing over \$1 billion per year to US healthcare costs.^[16] Numerous articles can be found throughout the literature seeking to determine the prognostic factors involved in shunt patency, including what type of shunt to use (graft vs. fistula), which stenosis or thrombus locations are more amenable to treatment, and the role of secondary interventions.^[17-19] However, relatively, little literature exists on new and emerging methods for thrombectomy.

In this study, the vast majority (97%) of thrombectomy procedures utilizing the Cleaner[®] rotational thrombectomy device were successful in facilitating same-day hemodialysis. While primary patency^[20,21] to time of data collection was low at only 29% and many of the shunts needed to undergo subsequent interventions, it is worth emphasizing that this technique was often used as a bail-out in difficult cases that were otherwise refractory to standard techniques. The cases included in this study that may have been bound for difficulty in establishing patency regardless of method used, and the somewhat suboptimal results may simply be a reflection of selection bias for failing arteriovenous shunts. Still, the use of the Cleaner[®] device in these cases allowed for an average primary patency of 125 days, a meaningful amount of time for patients who otherwise would likely have had to undergo earlier surgical shunt revision, replacement, or abandonment.

This study specifically addresses the benefit of utilizing the Cleaner[®] rotational thrombectomy device for thrombectomy in end-stage renal disease patients with pseudoaneurysms and failing arteriovenous shunts. Given the lack of data on

the use of thrombectomy devices in clotted dialysis shunts, this study provides early evidence toward the safety and efficacy of these devices for this indication. Furthermore, given the challenge of treating clotted hemodialysis shunts related to pseudoaneurysms, rotational thrombectomy may serve an important role in effectively treating wall-adherent acute or subacute thrombus that normally cannot be addressed with conventional balloons.

It is worth noting that conventional methods of declotting, including maceration of clot via the push-pull method, may result in pulmonary emboli, and it is the authors' opinion that small pulmonary emboli are almost invariably occurring in every declot procedure. While there is no evidence to suggest that maceration with the Cleaner[®] device would protect against this possibility, it has been shown that even repeated declots via conventional methods do not increase the rate of pulmonary hypertension in the short term, potentially due to heparin administration and/or the fact that any residual thrombus would be laced with tPA.^[22] Therefore, it is our opinion that the theoretical creation of emboli in using the Cleaner[®] device would not represent a significant harm to the patient beyond that of conventional methods.

This study was limited in that ultrasound, rather than fluoroscopy, may have yielded more accurate measurements of pseudoaneurysms, provided flow velocities pre- and post-treatment, and allowed for more detailed evaluation of thrombus clearance. The study is also limited by the fact that utilization of the Cleaner[®] device was often a last-resort method, with operator preference figuring prominently in its selection for use. Finally, the fact that this was a retrospective study with no comparison group leaves the question of whether these same complicated declots in patients with pseudoaneurysms could have been performed just as well with an alternative method.

Further studies would be helpful in determining what specific patient populations would be amenable to the usage of this device, as well as in which clinical situations a provider could anticipate using the device and employ it more proactively, rather than as a last-resort method. Further inquiry could also perhaps help stratify the device's usage based on the size and number of pseudoaneurysms. Ultimately, operator preference will continue to play a significant role in selecting among the variety of techniques and tools available to assist with dialysis shunt declots. However, it is the authors' hope that this study will contribute to a growing body of literature on the subject and help move practice toward a more evidence-based approach in treating this patient population which relies so heavily on our field for its care.

Conclusions

Thrombectomy with a rotational thrombectomy device in patients with pseudoaneurysms appears to present a safe

and effective option for restoring patency to thrombosed arteriovenous shunts refractory to standard angioplasty balloon push-pull techniques. Further study is needed to validate these findings and further characterize the ideal patient populations and clinical situations for optimal use.

Financial support and sponsorship

Nil.

Conflicts of interest

There are no conflicts of interest.

References

- Zaleski G. Declotting, maintenance, and avoiding procedural complications of native arteriovenous fistulae. *Semin Intervent Radiol* 2004;21:83-93.
- Funaki B. Problematic declots: Complications and irritations. *Semin Intervent Radiol* 2004;21:69-75.
- Quencer KB, Rahmi O. Hemodialysis access thrombosis. *Cardiovasc Diagn Ther* 2017; 7 Suppl 3:S299-308.
- Mudoni A, Cornacchiari M, Gallieni M, Guastoni C, McGrogan D, Logias F, *et al.* Aneurysms and pseudoaneurysms in dialysis access. *Clin Kidney J* 2015;8:363-7.
- Ahn SY, So YH, Choi YH, Jung IM, Chung JK. Endovascular recanalization of a thrombosed native arteriovenous fistula complicated with an aneurysm: Technical aspects and outcomes. *Korean J Radiol* 2015;16:349-56.
- Hedin U, Engström J, Roy J. Endovascular treatment of true and false aneurysms in hemodialysis access. *J Cardiovasc Surg (Torino)* 2015;56:599-605.
- Inston N, Mistry H, Gilbert J, Kingsmore D, Raza Z, Tozzi M, *et al.* Aneurysms in vascular access: State of the art and future developments. *J Vasc Access* 2017;18:464-72.
- Marcelin C, D'Souza S, Le Bras Y, Petitpierre F, Grenier N, van den Berg JC, *et al.* Mechanical thrombectomy in acute thrombosis of dialysis arteriovenous fistulae and grafts using a vacuum-assisted thrombectomy catheter: A multicenter study. *J Vasc Interv Radiol* 2018;29:993-7.
- US Device Guide/Mechanical Thrombectomy/Thrombolysis. *Endovascular Today*. Available from: <https://evtoday.com/device-guide/us/mechanical-thrombectomy-thrombolysis>. [Last accessed on 2020 Jun 07].
- Bozkurt A, Kirbaş İ, Kösehan D, Demirçelik B, Nazlı Y. Pharmacomechanical thrombectomy in the management of deep vein thrombosis using the cleaner device: An initial single-center experience. *Ann Vasc Surg* 2015;29:670-4.
- Yuksel A, Tuydes O. Midterm outcomes of pharmacomechanical thrombectomy in the treatment of lower extremity deep vein thrombosis with a rotational thrombectomy device. *Vasc Endovascular Surg* 2017;51:301-6.
- Köksoy C, Yılmaz MF, Başbuğ HS, Calik ES, Erkut B, Kaygın MA, *et al.* Pharmacomechanical thrombolysis of symptomatic acute and subacute deep vein thrombosis with a rotational thrombectomy device. *J Vasc Interv Radiol* 2014;25:1895-900.
- Dariushnia SR, Walker TG, Silberzweig JE, Annamalai G, Krishnamurthy V, Mitchell JW, *et al.* Quality improvement guidelines for percutaneous image-guided management of the thrombosed or dysfunctional dialysis circuit. *J Vasc Interv Radiol* 2016;27:1518-30.
- CLEANER Rotational Thrombectomy System. Available from: <https://www.argonmedical.com/products/cleaner-rotational-thrombectomy-system>. [Last accessed on 2020 May 12].
- Turmel-Rodrigues L, Pengloan J, Rodrigue H, Brillet G, Lataste A, Pierre D, *et al.* Treatment of failed native arteriovenous fistulae for hemodialysis by interventional radiology. *Kidney Int* 2000;57:1124-40.
- Irani FG, Teo TKB, Tay KH, Yin WH, Win HH, *et al.* Hemodialysis arteriovenous fistula and graft stenosis: Randomized trial comparing drug-eluting balloon angioplasty with conventional angioplasty. *J Radiol* 2018;289:238-47.
- Park J, Kim J, Hwang S, Lee MK, Jang HR, Eun Lee J, *et al.* Arteriovenous graft patency outcomes and prognostic factors. *Vascular* 2019;27:128-34.
- Kanterman RY, Vesely TM, Pilgram TK, Guy BW, Windus DW, Picus D. Dialysis access grafts: Anatomic location of venous stenosis and results of angioplasty. *Radiology* 1995;195:135-9.
- Ayez N, Fioole B, Aarts RA, van den Dorpel MA, Akkersdijk GP, Dinkelman MK, *et al.* Secondary interventions in patients with autologous arteriovenous fistulas strongly improve patency rates. *J Vasc Surg* 2011;54:1095-9.
- Shenoy S, Allon M, Beathard G, Brouwer-Maier D, Dember LM, Glickman M, *et al.* Clinical trial end points for hemodialysis vascular access: Background, rationale, and definitions. *Clin J Am Soc Nephrol* 2018;13:490-4.
- Kim WS, Pyun WB, Kang BC. The primary patency of percutaneous transluminal angioplasty in hemodialysis patients with vascular access failure. *Korean Circ J* 2011;41:512-7.
- Hsieh MY, Lai CL, Wu YW, Lin L, Ho MC, Wu CC. Impact on pulmonary arterial pressures after repeated endovascular thrombectomy of dialysis grafts: A prospective follow-up study. *J Vasc Interv Radiol* 2014;25:1883-9.