

## Fluoroscopy-Guided Microwave Ablation after Transarterial Chemoembolization with Drug-coated Bead LUMI Radiopaque Beads

Visualization of the radiopaque drug-coated (DC) bead LUMI™ (Biocompatibles UK Ltd., Farnham, UK) under fluoroscopy or computed tomography (CT) guidance, after transarterial chemoembolization (TACE), may help in ablation of difficult lesions that cannot be localized by ultrasound (US).

We present a 61-year-old male patient who underwent selective TACE for segment VIII hepatocellular carcinoma using one vial (2 ml) of DC Bead LUMI (70–150 µm) loaded with 75 mg of doxorubicin, mixed with 18 ml of nonionic iso-osmolar contrast (Visipaque™ 320). After embolization, contrast retention was observed in the majority of the tumor with a small defect in the inferior margin [Figure 1], which feeder could not be identified. US could not clearly visualize the target residual lesion. Therefore, combined fluoroscopic and US guidance was done for precise positioning of the microwave (MW) antenna (Emprint™, Medtronic, MN, USA) within the nonembolized tumor part [Figure 2]. MW ablation was performed utilizing 100 watts over 2 min.

Follow-up CT scan of the abdomen [Figure 3] after 6 weeks showed successful treatment with no residual enhancement of the treated lesion.

### Informed consent

The patient consented for the procedure.

### Financial support and sponsorship

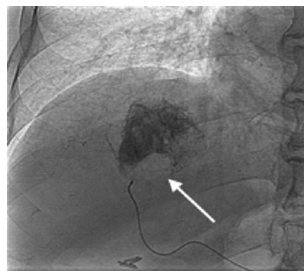
Nil.

### Conflicts of interest

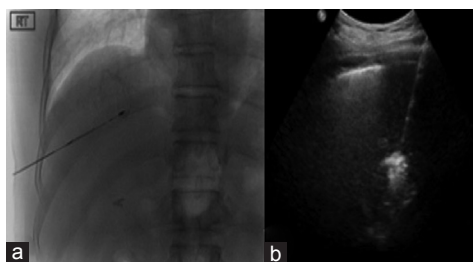
There are no conflicts of interest.

This is an open access journal, and articles are distributed under the terms of the Creative Commons Attribution-NonCommercial-ShareAlike 4.0 License, which allows others to remix, tweak, and build upon the work non-commercially, as long as appropriate credit is given and the new creations are licensed under the identical terms.

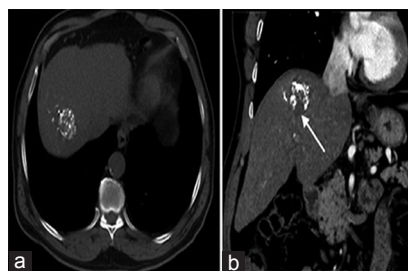
For reprints contact: reprints@medknow.com



**Figure 1:** Spot image during transarterial chemoembolization showing contrast retention in the majority of the tumor with a small defect in the inferior margin (arrow)



**Figure 2:** (a) Spot image during fluoroscopic-assisted microwave ablation showing the microwave antenna in the inferior margin of the tumor targeting the area that was suboptimally treated by embolization. (b) Ultrasound image during microwave ablation



**Figure 3:** Follow-up computed tomography of the abdomen after 6 weeks. (a) Axial nonenhanced computed tomography image showing retention of hyperdense drug-coated beads (LUMI™) within the treated hepatocellular carcinoma. (b) Coronal computed tomography image during the arterial phase showing absence of tumor enhancement. Note the ablated inferior part of the lesion (arrow)

**How to cite this article:** AlAklabi AS, Bukhary GA, Salman R. Fluoroscopy-guided microwave ablation after transarterial chemoembolization with drug-coated bead LUMI radiopaque beads. Arab J Intervent Radiol 2019;3:35.

**Aeed Saad AlAklabi<sup>1,2</sup>, Ghazy Abdulelah Bukhary<sup>1,2</sup>, Refaat Salman<sup>1,2</sup>**

<sup>1</sup>Division of Vascular Interventional Radiology, Department of Medical Imaging, Ministry of National Guard-Health Affairs, <sup>2</sup>King Abdullah International Medical Research Center, Riyadh, Saudi Arabia

**Address for correspondence:**  
Dr. Aeed Saad AlAklabi,  
Department of Medical Imaging, Division of Vascular Interventional Radiology, King Abdulaziz Medical City, P. O. Box: 22490, Riyadh 11426, Saudi Arabia.  
E-mail: alaklabiae@ngha.med.sa

### Access this article online

Website: www.arabjir.com

DOI: 10.4103/AJIR.AJIR\_45\_18

### Quick Response Code:

