

Percutaneous Endovascular Sapheno-Femoral Bypass for Treatment of Chronic Iliac Vein Stent Occlusion

Abstract

We report a case of a 45-year-old female with a history of chronic iliac vein and inferior vena cava (IVC) occlusion, who presented with diffuse bilateral lower limb edema and pain secondary to severe postthrombotic syndrome. Computed tomography and digital subtraction angiography demonstrated reocclusion in the patient's previously placed iliofemoral and IVC stents. Recanalization was achieved with a percutaneous endovascular bypass approach after unsuccessful attempts using standard and other advanced endovascular techniques including sharp needle and radiofrequency wire recanalization.

Keywords: Chronic venous occlusion, iliac vein obstruction, inferior vena cava obstruction, percutaneous bypass, recanalization

Introduction

Standard endovascular treatment for patients who develop chronic venous occlusion involves balloon angioplasty followed by stent placement.^[1-4] When the conventional approach of establishing access across an occluded vein fails, more aggressive techniques such as radiofrequency wire and sharp recanalization may be considered. Although studies have reported both the technical and clinical success of such methods, these advanced techniques do not guarantee successful recanalization and are associated with harmful complications such as vascular perforation and hemorrhage.^[5-7]

We report a new technique of percutaneous endovascular bypass to treat recurrent iliac vein and inferior vena cava (IVC) occlusion in a patient with chronic deep vein thrombosis and prior stenting. Case reports are exempt from the Institutional Review Board approval at our institution.

Case Report

A 45-year-old female with a history of deep vein thrombosis, pulmonary embolism, and lupus was treated with IVC filter placement and subsequently developed ilio caval thrombosis. She was treated at an outside hospital over 5 years prior with thrombolysis and stent placement

(Wallstent®, Boston Scientific, Natick, MA, USA) from the infrarenal IVC into the femoral veins bilaterally. After reporting initial relief of symptoms compatible with postthrombotic syndrome, she underwent an unsuccessful attempt to recanalize chronic occlusion of these stents 1 month before referral to the authors' institution.

On initial presentation, diffuse bilateral lower limb edema and pain secondary to severe postthrombotic syndrome were noted (Villalta score of 24). This was reported to have progressed over the past 18 months. Recanalization with angioplasty and stenting was performed to successfully restore patency of the left iliofemoral stents. Recanalization of the right common femoral vein stent was attempted from an internal jugular approach using conventional techniques including a Truepath® Chronic Total Occlusion device (Boston Scientific, Natick, MA, USA) and sharp needle (Rosch Uchida Transjugular Liver Access Set; Cook®, Bloomington, IN, USA) recanalization but was unsuccessful due to chronic occlusion below the stent. Recanalization of the right iliofemoral stents was again re-attempted 2 months later from a popliteal approach using a radiofrequency wire (Baylis Medical, Mississauga, Ontario) but was ineffective due to repeated contact of the wire with the metallic stent. Given prior unsuccessful

**Osman S. Ahmed,
Roberto Santos
Loanzon¹,
Bulent Arslan**

*Department of Radiology,
Section of Vascular and
Interventional Radiology, Rush
University Medical Center,
¹Chicago Medical School,
Rosalind Franklin University,
North Chicago, IL, USA*

Address for correspondence:
Mr. Roberto Santos Loanzon,
Rosalind Franklin University,
3333 Green Bay Road,
North Chicago, IL 60064, USA.
E-mail: rloanzon@gmail.com

Access this article online

Website: www.arabjir.com

DOI: 10.4103/AJIR.AJIR_3_18

Quick Response Code:



How to cite this article: Ahmed OS, Loanzon RS, Arslan B. Percutaneous endovascular sapheno-femoral bypass for treatment of chronic iliac vein stent occlusion. Arab J Intervent Radiol 2018;2:20-3.

This is an open access article distributed under the terms of the Creative Commons Attribution-NonCommercial-ShareAlike 3.0 License, which allows others to remix, tweak, and build upon the work non-commercially, as long as the author is credited and the new creations are licensed under the identical terms.

For reprints contact: reprints@medknow.com

attempts using these advanced techniques, a different approach for recanalization was sought.

Under general anesthesia, the right internal jugular vein was accessed, and a 7-Fr APTUS® directional sheath (Medtronic, Dublin, Ireland) was placed. A cardiac transeptal needle (Cook®, Bloomington, IN, USA) and 0.014" wire was directed toward the cranial aspect of the right-sided iliofemoral stents and used to obtain access into the occluded stent. The sheath was subsequently advanced over the needle and wire through the level of the right external iliac vein. Next, the needle was removed and a hydrophilic wire and crossing catheter were used to traverse the remainder of the stent into the femoral vein. Contrast was injected demonstrating multiple collaterals and chronically occluded femoral vein as seen before.

A draining vein was, however, noted medial to the catheter and common femoral vein stent, representing an enlarged saphenous vein with outflow into an enlarged collateral of the circumflex iliac venous system. The saphenous vein was subsequently accessed in the right mid-thigh under ultrasound guidance, and a venogram was obtained, demonstrating abrupt cutoff of flow at the level of the femoral vein stent with prompt opacification of the enlarged circumflex iliac collateral adjacent to the stent [Figure 1].

From the jugular access, a snare was advanced into the inferior aspect of the femoral stent and partially deployed due to chronic occlusion. A second snare was placed from the saphenous access and positioned near the other snare within the femoral stent. A micropuncture needle was then placed through both snares under fluoroscopic guidance utilizing a "bullseye" approach to align both snares [Figure 2a]. A V18® (Boston Scientific, Natick, MA, USA) wire was then advanced through this needle, successfully snared from above, and pulled through the right internal jugular vein sheath and clamped.

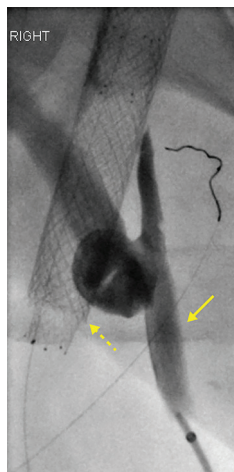


Figure 1: Venogram obtained from the saphenous vein access demonstrated venous drainage into an enlarged circumflex iliac collateral (solid arrow) adjacent to the occluded femoral stent (dashed arrow)

The V18 wire was then snared from below [Figure 2b] and pulled through the groin sheath to obtain through-and-through access. A QuickCross® (Spectranetics, Silver Springs, CO, USA) catheter was advanced and exchanged for a new V18® wire. Contrast was injected from the saphenous sheath, again demonstrating multiple collaterals and the dominant collateral coursing laterally along the inferior margin of the CFV stent [Figure 2c]. To create a path from the collateral vein through the interstices of the stent, angioplasty was performed with a 4 mm × 2 cm balloon. This enabled exchange of the V18® wire for an exchange length Amplatz wire. A 6 mm × 4 cm high-pressure balloon was then used to cross the inferior portion of the stent and further dilate the extravascular anastomosis.

Subsequently, an 8 mm balloon was used to angioplasty the newly created channel through the inferior aspect of the stent. Next, the stents were dilated with 10, 12, and 14 mm high-pressure balloons. A 10 mm × 25 mm balloon expandable Express® LD stent (Boston Scientific, Natick, MA, USA) was placed across the newly created anastomosis between the collateral and femoral stent. Two 14 mm × 80 mm overlapping Zilver® stents (Cook Medical, Bloomington, IN, USA) were placed into the infrarenal IVC and right common iliac vein. This was followed by two 12 mm × 80 mm Zilver® stents that were placed across the right iliac vein. Finally, a 10 mm × 80 mm Zilver® stent was placed inferiorly across the inferior iliac vein, common femoral vein, and Express® stents. Contrast was again injected from the sheath demonstrating wide patency of the stents and IVC with preferential flow through the stent [Figure 3]. The patient was begun on therapeutic low-molecular-weight heparin and Plavix indefinitely. At 3 months follow-up, an ultrasound performed at an outside hospital demonstrated maintained patency across both

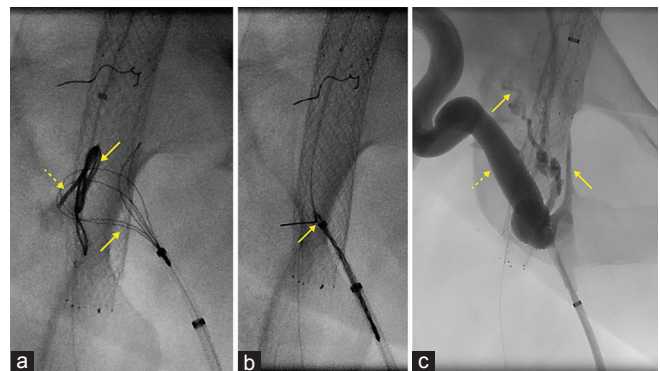


Figure 2: Fluoroscopic images of creating an extravascular bypass or shunt between the large circumflex iliac collateral and the occluded femoral vein stent. (a) Using a "bullseye" approach to fluoroscopically align both snares (solid arrows) deployed in each vein, a micropuncture needle (dashed arrow) was directed through the snares, followed by placement of a V18® guidewire. (b) After being snared from above and pulled through the right internal jugular vein sheath, the guidewire was snared from below (arrow). (c) After establishing through-and-through wire access, repeat venogram again demonstrated multiple collaterals (solid arrows) and preferential outflow through the targeted collateral (dashed arrow)

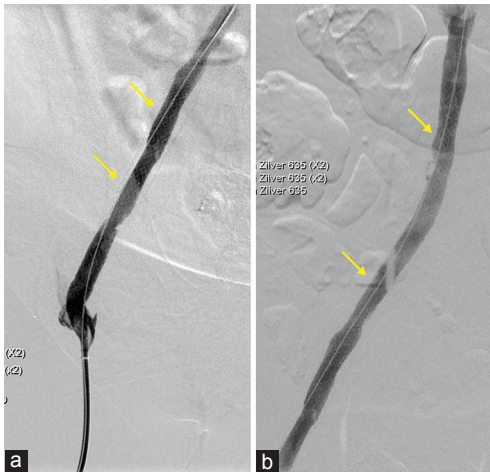

Figure 3: (a and b) Final venogram postangioplasty and stenting demonstrated restored single-vessel outflow through the right iliofemoral system (arrows) and patency of the iliofemoral stents

iliofemoral veins with marked reduction in edema and pain secondary to postthrombotic syndrome.

Discussion

Surgical venous bypass procedures are rarely performed in treating chronic venous occlusion but may be indicated in patients who present with severe symptoms and long occlusive lesions, as seen in the present case. While surgical venous bypass has been reported as a rarely utilized treatment when other endovascular interventions fail, this approach is limited in IVC and iliac vein obstructions by native graft availability for large vein reconstructions as well as a paucity of data supporting its efficacy and long-term patency.^[8,9]

In the present case, a percutaneous endovascular bypass approach was sought as conventional and advanced recanalization techniques had failed. The enlarged collateral from the saphenous was identified as a suitable inflow given its size and dynamic flow on fluoroscopy. Although this collateral could be a sufficient outflow for the leg, persistent clinical symptoms argued against this. In addition, preferential in-line flow through the stent was felt to provide best chance for this patient to relieve venous hypertension and maintain patency of the iliofemoral stents. The technical success of this procedure was attributed to operator experience and identifying an appropriate venous collateral in close to the occluded vessel without intervening critical neurovascular structures. In addition, the concept of the fluoroscopic “bullseye” approach, previously described for percutaneous mesocaval shunt creation, was utilized for this application.^[10] The technique in the present case varied slightly as one end of the anastomosis was placed into a chronically occluded vessel, prohibiting full expansion of the snare. In addition, the prior report represented a shunt between portal and systemic venous

systems whereas the current report describes a short extra-anatomic bypass across the superficial and deep venous systems. Finally, an additional method used to preserve flow within stented iliofemoral venous segments includes the surgical creation of an arteriovenous fistula to maintain high flow within the stents to prevent rethrombosis.^[11]

Conclusion

Percutaneous endovascular sapheno-femoral bypass may represent a feasible technique for treating chronic venous occlusion in patients who are refractory to conventional and other advanced endovascular techniques.

Declaration of patient consent

The authors certify that they have obtained all appropriate patient consent forms. In the form the patient(s) has/have given his/her/their consent for his/her/their images and other clinical information to be reported in the journal. The patients understand that their names and initials will not be published and due efforts will be made to conceal their identity, but anonymity cannot be guaranteed.

Financial support and sponsorship

Nil.

Conflicts of interest

Osman S. Ahmed is a speaker for Spectranetics® and medical advisory board member for Bayer® Bulent Arslan is a speaker and advisory board member for Penumbra®, Medtronic/Covidien®, and speaker for Cook®, W.L. Gore®, Guerbet®, and CR Bard®.

References

1. Neglén P, Berry MA, Raju S. Endovascular surgery in the treatment of chronic primary and post-thrombotic iliac vein obstruction. *Eur J Vasc Endovasc Surg* 2000;20:560-71.
2. Erben Y, Bjarnason H, Oladottir GL, McBane RD, Gloviczki P. Endovascular recanalization for nonmalignant obstruction of the inferior vena cava. *J Vasc Surg Venous Lymphat Disord* 2018. pii: S2213-333X(17) 30533-4.
3. Ye K, Shi H, Yin M, Qin J, Yang X, Liu X, et al. Treatment of femoral vein obstruction concomitant with iliofemoral stenting in patients with severe post-thrombotic syndrome. *Eur J Vasc Endovasc Surg* 2017. pii: S1078-5884(17) 30723-2.
4. Rossi FH, Kambara AM, Izukawa NM, Rodrigues TO, Rossi CB, Sousa AG, et al. Randomized double-blinded study comparing medical treatment versus iliac vein stenting in chronic venous disease. *J Vasc Surg Venous Lymphat Disord* 2017. pii: S2213-333X(17) 30506-1.
5. Sivananthan G, MacArthur DH, Daly KP, Allen DW, Hakham S, Halin NJ, et al. Safety and efficacy of radiofrequency wire recanalization of chronic central venous occlusions. *J Vasc Access* 2015;16:309-14.
6. Tingerides C, Annamalai G, Comin JM, Kaduri S, Pugash R, David E, et al. Percutaneous recanalization of iliac artery occlusions by radiofrequency perforation: Initial experience. *J Vasc Interv Radiol* 2016;27:68-72.

7. Ito N, Isfort P, Penzkofer T, Grommes J, Greiner A, Mahnken A, *et al.* Sharp recanalization for chronic left iliac vein occlusion. *Cardiovasc Intervent Radiol* 2012;35:938-41.
8. Adams MK, Anaya-Ayala JE, Ismail N, Peden EK. Surgical femorocaval bypass for recalcitrant iliofemoral venous occlusion to endovascular treatment. *Vasc Endovascular Surg* 2012;46:578-81.
9. Jost CJ, Gloviczki P, Cherry KJ Jr., McKusick MA, Harmsen WS, Jenkins GD, *et al.* Surgical reconstruction of iliofemoral veins and the inferior vena cava for nonmalignant occlusive disease. *J Vasc Surg* 2001;33:320-7.
10. Bercu ZL, Sheth SB, Noor A, Lookstein RA, Fischman AM, Nowakowski FS, *et al.* Percutaneous mesocaval shunt creation in a patient with chronic portal and superior mesenteric vein thrombosis. *Cardiovasc Intervent Radiol* 2015;38:1316-9.
11. Pokrovsky A, Ignatyev I, Gradusov E. First experience of performing hybrid operations in chronic venous obstructions of iliofemoral segments in patients with postthrombotic syndrome. *Vasc Endovascular Surg* 2017;51:447-52.