

Endovascular Management in a Case of Recurrent Bleed Following Transurethral Resection of the Prostate

Abstract

Transurethral resection of prostate (TURP) remains the gold standard surgical therapy for symptomatic benign prostatic enlargement, with reported International Prostate Symptom Score reduction of up to 70%. However, as many as 20% of patients can have significant complications including sexual dysfunction, perioperative bleeding requiring blood transfusion, and incontinence. Intractable hematuria from the prostate can be life-threatening, and its management remains a difficult clinical problem. Prostate artery embolization (PAE) is occasionally indicated in such patients when all other measures have failed. PAE has been used to treat benign prostatic hyperplasia; however, literature related to its use for bleeding following TURP remains limited. We report a case of an elderly male who presented with recurrent episodes of hematuria following TURP and was successfully treated by endovascular management.

Keywords: Benign prostatic hyperplasia, hematuria, prostatic artery embolization

Introduction

Intractable hematuria from the prostate is potentially a life-threatening event that raises major therapeutic challenges. Causes of severe hematuria include transurethral resection of the prostate (TURP), prostatic biopsy, and prostate cancer.^[1] At times, it may not be possible to adequately control the bleeding by conservative measures, such as irrigation or endoscopic diathermy. Prostate artery embolization (PAE) is a minimally invasive procedure that is emerging as a safe, effective means to control prostate bleeding.^[1,2] Most outcome data in the literature appear to come from case reports and small case series, and little is known about midterm outcomes. Delgal *et al.*^[1] retrospectively evaluated the efficacy and outcomes of transcatheter arterial embolization for intractable bladder or prostate bleeding in 2 women and 18 men. Embolization was feasible in 90% (18 of 20 cases). Bleeding was controlled after the first procedure in 15 of 18 patients (83.3%) and after a repeat procedure in the remaining 3 patients. We report a case of an elderly male who presented with recurrent episodes of hematuria following TURP and bleeding controlled with transcatheter embolization of the prostatic vessels.

This is an open access article distributed under the terms of the Creative Commons Attribution-NonCommercial-ShareAlike 3.0 License, which allows others to remix, tweak, and build upon the work non-commercially, as long as the author is credited and the new creations are licensed under the identical terms.

For reprints contact: reprints@medknow.com

Case Report

A 72-year-old male presented to the urological services of the hospital with a history of lower urinary tract symptoms of 4-week duration. The symptoms included both storage and voiding symptoms with an International Prostate Symptom Score of 27. Ultrasonography imaging revealed a urinary bladder stone of 22 mm in diameter with a prostatic volume of 46 cc. Upper tracts were normal. Serum prostate-specific antigen levels were 10.4 ng/ml. In view of these findings, the patient underwent 12-core transrectal prostatic biopsy under ultrasound guidance with cystolitholapaxy under regional anesthesia. A catheter was left in place following the endoscopic procedure. The histopathological examination of the biopsy specimen revealed benign prostatic hyperplasia with areas of chronic infection.

The patient failed to void following catheter removal 48 h postprocedure. He was started on alpha blockers (Silodosin 8 mg tablets at bedtime), with no success in voiding. A catheter was reinserted, but the patient failed a catheter-free trial on two occasions 15 and 30 days later. After risks were explained, the patient was taken to the operating room for the TURP. Post-TURP, the patient

How to cite this article: Nerli RB, Kadeli V, Mulimani N, Ghagane SC. Endovascular management in a case of recurrent bleed following transurethral resection of the prostate. Arab J Intervent Radiol 2018;2:33-5.

**R. B. Nerli,
Vishal Kadeli¹,
Naveen Mulimani²,
Shridhar C. Ghagane³**

KLES Kidney Foundation KLES Dr. Prabhakar Kore Hospital & Medical Research Centre, ¹Department of Urology, KLE Academy of Higher Education and Research (Deemed-to-be-University), JNMC Campus, ²Department of Interventional Radiology, KLES Dr. Prabhakar Kore Hospital & Medical Research Centre, ³Department of Urology, KLES Kidney Foundation, KLES Dr. Prabhakar Kore Hospital & Medical Research Centre, Belagavi, India

Address for correspondence:

*Dr. R. B. Nerli,
Department of Urology, KLES Dr. Prabhakar Kore Hospital and Medical Research Centre, KLES Kidney Foundation, KLE Academy of Higher Education and Research (KLE University), Belagavi - 590 010, Karnataka, India.
E-mail: rbnerli@gmail.com*

Access this article online

Website: www.arabjir.com

DOI: 10.4103/AJIR.AJIR_28_17

Quick Response Code:



successfully voided post-Foley catheter removal. He was readmitted for complaints of hematuria after a week's time. The patient's hemoglobin had dropped down to 7.6 g/dL. Cystoscopy and clot evacuation were done. No active bleeder was found on endoscopy. Catheter-free trial was again given after 48 h. The patient voided clear urine for the next 4–5 days and presented again with hematuria. These bleeding episodes continued for about 24 h. Cystoscopy was repeated and clots were evacuated. In view of recurrent episodes, a consultation with the interventional radiologist was sought.

PAE procedure was performed under local anesthesia using bilateral femoral artery access. Diagnostic selective and superselective angiograms were done using Progreat microcatheter (Terumo Corporation, Japan) and coaxially through Cobra catheter (AngioDynamics, Inc., Queensbury, NY, USA) [Figures 1 and 2] to confirm the arteries supplying the vascular blush and embolized using PVA particles (Boston Scientific Corporation, USA) (300–510 μ). Final angiograms revealed complete embolization of the bleeding vessels. The patient tolerated the procedure well. The patient is currently on close follow-up for over 24 weeks now.

Discussion

Severe hematuria following TURP that persists despite conventional treatment raises major therapeutic challenges. Patients are usually older and have other comorbidities such as hypertension, diabetes mellitus, and coronary artery disease. Prolonged or repeat hospitalization for bladder irrigation and multiple blood transfusions are not practical, and the risk of major morbidity associated with repeat endoscopic procedures is often unacceptably high. Endovascular embolization is a minimally invasive method that allows the patient to stay at home without catheters. With superselective

embolization being performed in most patients today, the initial clinical success rates are very high as reported in the most recently published studies.^[3,4]

Earlier studies had suggested a higher risk of rebleeding after unilateral embolization.^[2] Rebleeding after unilateral embolization is probably related to the rich collateral blood supply to the internal iliac artery from the contralateral internal iliac, inferior mesenteric, external iliac, and femoral arteries. To prevent rebleeding from these collaterals, the anterior division of the internal iliac artery should probably be embolized bilaterally regardless of whether the bleeding site is detectable on angiogram.^[2]

Embolization with particles has a small risk of bladder infarction due to the rich blood supply of the organ. Types of complications reported are cases of postembolization syndrome treated with symptomatic medication. Superselective embolization of the prostate arteries should be performed whenever possible to minimize the risk of ischemic complications at other sites of the internal iliac territory.^[1,2] Chen *et al.*^[5] reported on nine patients with advanced prostate cancer who underwent PAE for refractory prostatic hematuria. Angiograms showed prostatic neovascularity in all cases, and complete PAE was achieved in eight cases (89% technical success rate). Gross hematuria ceased after PAE in six cases, translating to a 67% clinical success rate.

Conclusion

Transcatheter arterial embolization may offer a feasible and safe alternative to control bleeding from the prostate after failure of conservative management. In most cases, embolization is a well-tolerated procedure that obviates the need for surgery. Embolization should be viewed as a minimally invasive, palliative measure that may control life-threatening hemorrhage and provide sustained bleeding control, contributing to decreasing the need

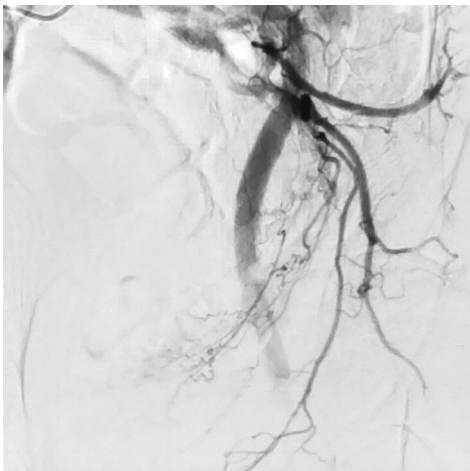


Figure 1: Selective angiograms of bilateral internal iliac and anterior divisional branches

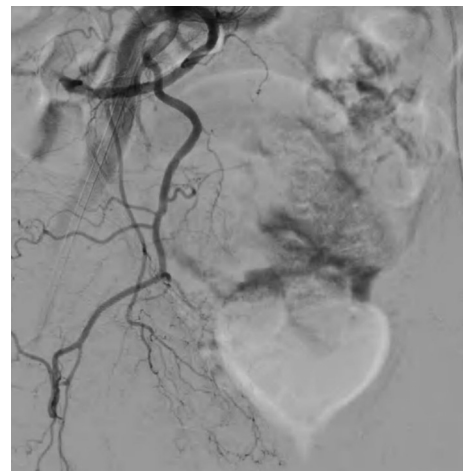


Figure 2: The prostatic arteries being embolized

for blood transfusion, bladder irrigation, and repeat cystoscopy.

Declaration of patient consent

The authors certify that they have obtained all appropriate patient consent forms. In the form the patient(s) has/have given his/her/their consent for his/her/their images and other clinical information to be reported in the journal. The patients understand that their names and initials will not be published and due efforts will be made to conceal their identity, but anonymity cannot be guaranteed.

Financial support and sponsorship

Nil.

Conflicts of interest

There are no conflicts of interest.

References

1. Delgal A, Cercueil JP, Koutlidis N, Michel F, Kermarrec I, Mourey E, *et al.* Outcome of transcatheter arterial embolization for bladder and prostate hemorrhage. *J Urol* 2010;183:1947-53.
2. Loffroy R, Pottecher P, Cherblanc V, Favelier S, Estivalet L, Koutlidis N, *et al.* Current role of transcatheter arterial embolization for bladder and prostate hemorrhage. *Diagn Interv Imaging* 2014;95:1027-34.
3. Rastinehad AR, Caplin DM, Ost MC, VanderBrink BA, Lobko I, Badlani GH, *et al.* Selective arterial prostatic embolization (SAPE) for refractory hematuria of prostatic origin. *Urology* 2008;71:181-4.
4. Prasad V, Sacks BA, Kraus S, Clouse ME. Embolotherapy for lower urinary tract hemorrhage. *J Vasc Interv Radiol* 2009;20:965-70.
5. Chen JW, Shin JH, Tsao TF, Ko HG, Yoon HK, Han KC, *et al.* Prostatic arterial embolization for control of hematuria in patients with advanced prostate cancer. *J Vasc Interv Radiol* 2017;28:295-301.