

Patent Foramen Ovale during Pulmonary Embolism Thrombolysis

Patent foramen ovale (PFO) is a communication at the fossa ovale between the atrial septum primum and secundum, persisting beyond the age of 1 year. PFO provides a portal for paradoxical embolism due to right-to-left shunt.

A 42-year-old female patient presented with a history of acute deep venous thrombosis and pulmonary embolism. The patient was hemodynamically unstable on inotropes, requiring 12 L of O₂. During catheter-directed thrombolysis using femoral approach, the wire/catheter combination went incidentally from right atrium to the left atrium through PFO and then into the pulmonary vein. Angiogram showed backward contrast flow, from the right

pulmonary vein toward the left atrium and then left ventricle and finally to the aortic arch which confirmed the presence of PFO [Figure 1]. Eventually, the pulmonary arteries were catheterized and the thrombolysis procedure continued as per the protocol. Although the presence of PFO does not contraindicate the procedure, awareness of this abnormality helps interventional radiologist to reduce manipulation and minimize the risk of paradoxical embolization.

Financial support and sponsorship

Nil.

Conflicts of interest

There are no conflicts of interest.

**Rahaf El-Hussein Salem,
Latifah Al-Fahad,
Mohammed Al-Shammari¹**

Department of Radiology, King Khalid University Hospital, ¹Department of Radiology, Security Forces Hospital, Riyadh, Saudi Arabia

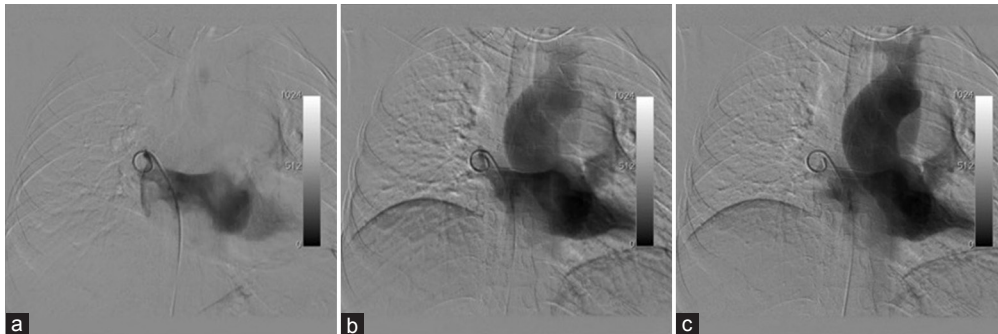


Figure 1: Pulmonary venogram: Pulmonary venogram through pigtail while placed in right pulmonary vein. (a) The is backward flow of contrast from right pulmonary vein towards the left atrium. (b) continuing flow of contrast from left atrium to left ventricle, outlining the boundaries of the left ventricular chamber. (c) Finally the contrast reaches the aortic arch and great vessels.

*Address for correspondence:
Dr. Mohammed Al-Shammari,
King Khalid University
Hospital, Riyadh, Saudi Arabia.
E-mail: dr-thani@hotmail.com*

This is an open access article distributed under the terms of the Creative Commons Attribution-NonCommercial-ShareAlike 3.0 License, which allows others to remix, tweak, and build upon the work non-commercially, as long as the author is credited and the new creations are licensed under the identical terms.

For reprints contact: reprints@medknow.com

How to cite this article: Salem RE, Al-Fahad L, Al-Shammari M. Patent foramen ovale during pulmonary embolism thrombolysis. Arab J Intervent Radiol 2018;2:37.

Access this article online

Website: www.arabjir.com

DOI: 10.4103/AJIR.AJIR_26_17

Quick Response Code:

