

## Arteriovenous Fistula of the Profunda Femoris Artery Postdynamic Hip Screw Fixation

The development of arteriovenous fistula (AVF) of the profunda femoris artery following dynamic hip screw (DHS) fixation is very rare. We present a 76-year-old female who had DHS for intertrochanteric hip fracture complicated by significant swelling of the right thigh associated with ecchymosis. A lower extremity Doppler ultrasound showed a right AVF likely arising from the profunda femoris artery [Figure 1] confirmed by computed tomography scan [Figure 2] and angiography [Figure 3]. Selective catheterization of a distal branch of the profunda femoris artery was

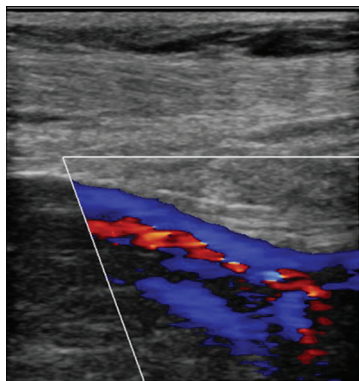


Figure 1: Doppler ultrasound showing an arteriovenous fistula in the right groin

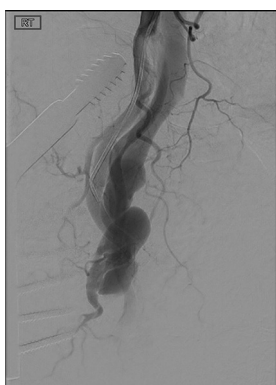

Figure 3: Digital subtraction angiography of the right profunda femoris artery showing opacification of the femoral vein consistent with an arteriovenous fistula

This is an open access journal, and articles are distributed under the terms of the Creative Commons Attribution-NonCommercial-ShareAlike 4.0 License, which allows others to remix, tweak, and build upon the work non-commercially, as long as appropriate credit is given and the new creations are licensed under the identical terms.

For reprints contact: reprints@medknow.com

performed, followed by coil embolization using 6 mm and 8 mm coils [Figure 4].

### Declaration of patient consent

The authors certify that they have obtained all appropriate patient consent forms. In the form the patient(s) has/have given his/her/their consent for his/her/their images and other clinical information to be reported in the journal. The patients understand that their names and initials will not be published and due efforts will be made to conceal their identity, but anonymity cannot be guaranteed.

### Financial support and sponsorship

Nil.

### Conflicts of interest

There are no conflicts of interest.

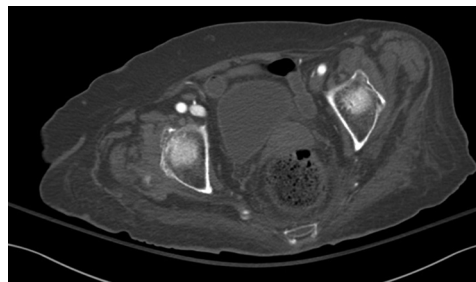


Figure 2: Contrast-enhanced computed tomography scan of the pelvis showing early enhancement of the right femoral vein indicating arteriovenous fistula

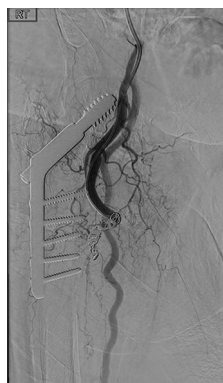

Figure 4: Digital subtraction angiogram of the right profunda femoris artery postcoiling embolization of the arteriovenous fistula

**How to cite this article:** Abohmed AB, Al Zahrani YA, Al Dulagain EM, Al Moaiqel MI. Arteriovenous fistula of the profunda femoris artery postdynamic hip screw fixation. Arab J Intervent Radiol 2018;2:93.

**Abdullah Bader Abohmed, Yousof Abdulrahman Al Zahrani, Essam Mohammed Al Dulagain, Mohammed Ibrahim Al Moaiqel**

Department of Medical Imaging, Division of Vascular and Interventional Radiology, King Abdulaziz Medical City, Riyadh, KSA

**Address for correspondence:**  
Dr. Yousof Abdulrahman Al Zahrani,  
Department of Medical Imaging,  
King Abdullah Specialist Children's Hospital and King Abdulaziz Medical City, Ministry of National Guard-Health Affairs, P.O. Box: 22490, Riyadh 11426, KSA.  
E-mail: zahraniy2@ngha.med.sa

### Access this article online

Website: [www.arabjir.com](http://www.arabjir.com)

DOI: 10.4103/AJIR.AJIR\_15\_18

### Quick Response Code:

