

Angio-Seal-Assisted Closure of Femoral Arterial Pseudoaneurysm in a Case of Uncorrectable Coagulation and Potential Allergy to Thrombin

Iatrogenic femoral artery pseudoaneurysm (FAP) is a recognized complication of the femoral artery access. Treatment options such as ultrasound-guided compression may fail in case of uncorrectable coagulopathy, and thrombin injection can trigger anaphylactic reaction with repeated exposure.^[1,2] In this case, we used ultrasound-guided deployment of Angio-Seal closure device (St. Jude Medical, Minnetonka, MN, USA) to treat FAP with uncorrectable coagulopathy and suspected allergy to thrombin.

The institutional research committee approved this single case report for publication. A 45-year-old male known with end-stage renal disease and ischemic heart disease, developed FAP following bronchial artery embolization procedure and underwent thrombin injection. The patient presented 1 week later with residual FAP at the right groin [Figure 1] measuring 4 cm × 1.8 cm × 1.5 cm and neck diameter of 3.9 mm. For the last 10 days, his coagulopathy status could not be controlled despite receiving all the blood products and factors and his coagulopathy status started to deteriorate because of unknown cause to the degree of having recurrent hemoptysis. Considering the potential risk of developing anaphylactic reaction, thrombin re-injection was not done; instead, ultrasound-guided compression was carried out for 30 min without success. Autologous clot was also considered. Blood was extracted and left for more than 10 min, but there was no evidence of clot formation. Therefore, closure device deployment across the narrow neck of the pseudoaneurysm was considered.

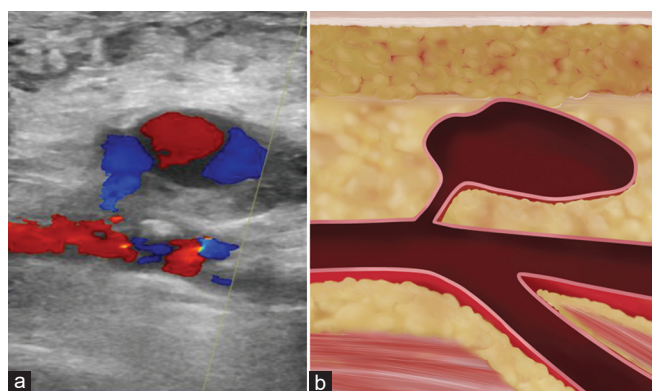


Figure 1: Sagittal Doppler ultrasound confirmed the presence of a pseudoaneurysm (4 cm × 1.8 cm × 1.5 cm) arising from the common femoral artery (a), the neck is narrow (3.9 mm). And a corresponding illustration (b)

Under ultrasound guidance, a micropuncture 21G needle was advanced through the narrow pseudoaneurysm neck into the common femoral artery [Figure 2]. After advancing the guidewire and removing the needle under fluoroscopic guidance, a 6-F Angio-Seal closure device was deployed across the pseudoaneurysm neck under real ultrasound guidance, confirming that the T-anchor is firmly pulled against the neck [Figure 2]. Hemostasis was achieved with no flow into the pseudoaneurysm confirmed by color Doppler [Figure 3]. Follow-up ultrasound after 24 h and computed tomography scan 1 week later confirmed complete hemostasis.

Percutaneous thrombin injection for the management of FAP showed high success rate (94%–100%) and low complication rate (2%).^[1] However, failure is likely to occur in larger size pseudoaneurysms, uncorrectable coagulopathy, or thrombin injection contraindications.

Repeated exposure to thrombin administration is associated with higher probability of developing antibodies to the coagulation factors and formation of immunoglobulin E antibodies that can trigger a fatal allergic reaction.^[3-5] In a randomized, double-blinded, controlled trial of 200 patients who were evaluated for the presence of antibodies to bovine thrombin, 5% were positive at baseline and 21.5% were positive after treatment.^[6] Dorion *et al.*'s study showed that 10% of the patients who received thrombin had antibodies against thrombin and patients who had multiple exposures to thrombin were eight times more prone to develop antibodies than patients with single exposure.^[5,7]

In this case, we described the use of Angio-Seal closure device to treat FAP by a single puncture technique and real-time ultrasound without need for contralateral puncture, and hemostasis was accomplished immediately under color Doppler monitoring. This approach may facilitate treatment of FAPs with a neck size <5 mm and for those with coagulopathy or with previous thrombin exposure. This case reminds interventional radiologists of the possible risk of anaphylaxis in patients with prior exposure to thrombin.

Financial support and sponsorship

Nil.

Conflicts of interest

There are no conflicts of interest.

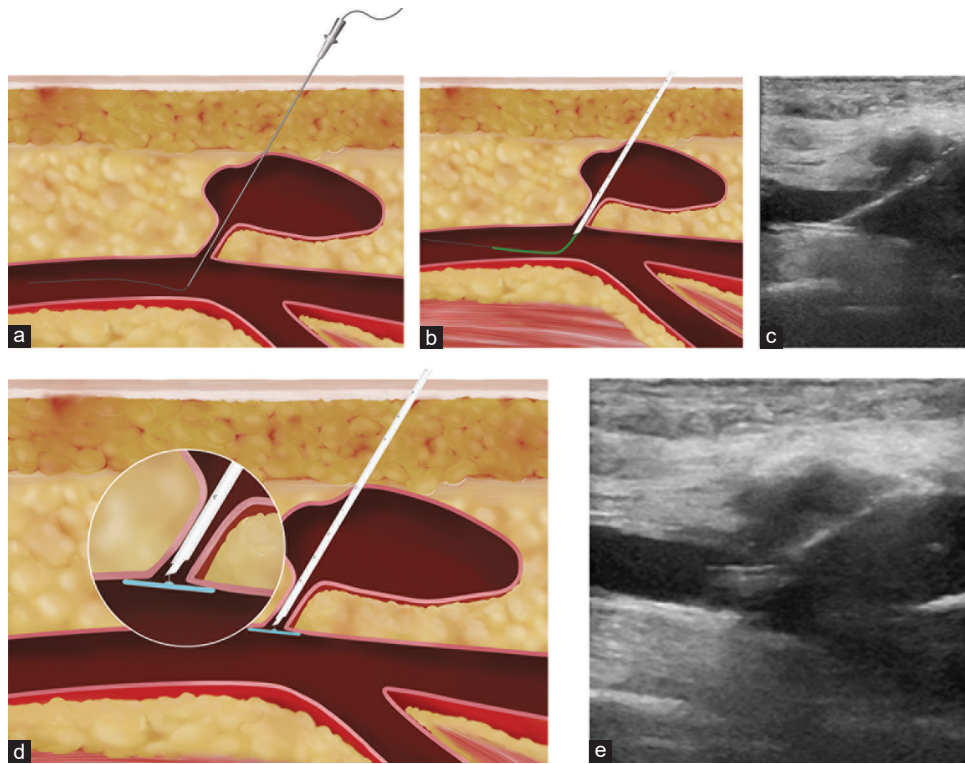


Figure 2: Ultrasound and corresponding illustrations showing the Angio-Seal closure device passing through the pseudoaneurysm neck crossing through the sac. (a-c) The anchor plate is opened at the common femoral artery and the anchor plate is pulled back against at the wall facing the neck (d and e)

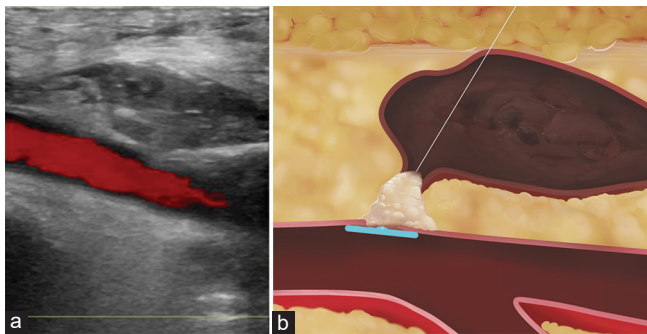


Figure 3: Ultrasound (a) and corresponding illustration (b) showing that the collagen is deployed across the neck of the pseudoaneurysm with complete clotting of the sac with no color on ultrasound

**Abdulmajeed Bin Dahmash,
Abdulrahman Al Qahtani, Shaker Alshehri**

Department of Medical Imaging, Vascular and Interventional Radiology Unit, King Abdulaziz Medical City and King Abdullah Specialized Children's Hospital, Ministry of National Guard-Health Affairs, Riyadh, Saudi Arabia

Address for correspondence:
Dr. Shaker Alshehri,

Department of Medical Imaging, Vascular and Interventional Radiology Unit, King Abdulaziz Medical City, Ministry of National Guard-Health Affairs, Riyadh 22490-11426, Saudi Arabia.
E-mail: alshehrish1@ngha.med.sa

References

1. Saydam O, Serefli D, Engin AY, Atay M. Ultrasound-guided thrombin injection for treatment of iatrogenic femoral artery pseudoaneurysms compared with open surgery: First experiences from a single institution. *Ann Surg Treat Res* 2020;98:270-6.
2. Gabrielli R, Rosati MS, Vitale S, Millarelli M, Chiappa R, Siani A, *et al.* Fatal complication after thrombin injection for post-catheterization femoral pseudoaneurysm. *Thorac Cardiovasc Surg* 2011;59:372-5.
3. Pope M, Johnston KW. Anaphylaxis after thrombin injection of a femoral pseudoaneurysm: Recommendations for prevention. *J Vasc Surg* 2000;32:190-1.
4. Paulson EK, Nelson RC, Mayes CE, Sheafor DH, Sketch MH Jr., Kliewer MA. Sonographically guided thrombin injection of iatrogenic femoral pseudoaneurysms: Further experience of a single institution. *AJR Am J Roentgenol* 2001;177:309-16.
5. Wai Y, Tsui V, Peng Z, Richardson R, Oreopoulos D, Tarlo SM. Anaphylaxis from topical bovine thrombin (ThrombostatR) during haemodialysis and evaluation of sensitization among a dialysis population. *Clin Exp Allergy* 2003;33:1730-4.
6. Chapman WC, Singla N, Genyk Y, McNeil JW, Renkens KL Jr., Reynolds TC, *et al.* A phase 3, randomized, double-blind comparative study of the efficacy and safety of topical recombinant human thrombin and bovine thrombin in surgical hemostasis. *J Am Coll Surg* 2007;205:256-65.

7. Dorion RP, Hamati HF, Landis B, Frey C, Heydt D, Carey D. Risk and clinical significance of developing antibodies induced by topical thrombin preparations. Arch Pathol Lab Med 1998;122:887-94.

This is an open access journal, and articles are distributed under the terms of the Creative Commons Attribution-NonCommercial-ShareAlike 4.0 License, which allows others to remix, tweak, and build upon the work non-commercially, as long as appropriate credit is given and the new creations are licensed under the identical terms.

Access this article online	
Quick Response Code: 	Website: www.arabjir.com
	DOI: 10.4103/AJIR.AJIR_13_20

How to cite this article: Bin Dahmash A, Al Qahtani A, Alshehri S. Angio-seal-assisted closure of femoral arterial pseudoaneurysm in a case of uncorrectable coagulation and potential allergy to thrombin. Arab J Interven Radiol 2020;4:138-40.

Received: 18-04-2020,
Accepted: 28-05-2020,

Revised: 26-05-2020,
Online Published: 07-07-2020.

© 2020 The Arab Journal of Interventional Radiology | Published by Wolters Kluwer - Medknow