

# Three-dimensional analysis to compare parallelism of occlusal planes to the hamular notch-incisive papilla plane in dentulous and edentulous subjects

Kishan Singh, Namratha Lakshmi<sup>1</sup>, Yoshaskam Agnihotri<sup>2</sup>, Suraj R. Suvarna, Sukant Sahoo, Prince Kumar

Departments of Prosthodontics, Shree Bankey Bihari Dental College and Research Centre, Ghaziabad, Uttar Pradesh, <sup>1</sup>Prosthodontics and <sup>2</sup>Conservative Dentistry and Endodontics, Hi Tech Dental College and Hospital, Bhubaneswar, Odisha, India

Address for correspondence:

Dr. Prince Kumar,  
Department of Prosthodontics,  
Shree Bankey Bihari Dental College  
and Research Center, N.H. 24, Masuri,  
Ghaziabad, Uttar Pradesh, India.  
E-mail: princekumar@its.edu.in

## ABSTRACT

**Purpose and Aim:** The aim of this study was to evaluate the reliability of hamular notch-incisive papilla (HIP) plane as an anatomical landmark in establishing occlusal plane in edentulous subjects. **Materials and Methods:** Seventy subjects were selected from the South Indian population, of which 50 were dentulous and 20 were edentulous. Dental stone casts were fabricated for dentulous and edentulous subjects. Dental stone casts of the dentulous and edentulous subjects, along with occlusal rims were analyzed using the three-dimensional analyzing machines. The angles between the occlusal planes and HIP plane were determined using the reference coordinate system based on characteristic points in the dentition on the cusp tips in dentulous casts and on maxillary occlusal rim on edentulous casts. **Results:** The HIP plane tends to be parallel to the occlusal plane. There is no statistical difference between sexes. **Conclusion:** The HIP plane is parallel to the natural occlusal plane and can be used as a reference plane to re-establish the occlusal plane in edentulous patients.

## Key words

Anatomical landmarks, hamular notch-incisive papilla reference plane, occlusal plane, three-dimensional analyzing machine

## INTRODUCTION

Occlusal plane is a classic example of a harmonious coordination in the stomatognathic system. Configuration of the occlusal plane is an anatomical entity, maintained by various physiological factors. A perfect inter-play between many factors contributes to the configuration of the plane of occlusion in human gnathodynamics. The glossary of Prosthodontic term (2005) defines occlusal plane as “the average plane established by the incisal and occlusal surfaces of the teeth.”<sup>[1]</sup> A plane is determined by at least 3 reference points that are not in a straight line. The occlusal plane is determined anteriorly by the maxillary incisor teeth and posteriorly by the retromolar pads. The junction of the upper

and middle third of the retromolar pads are the usual posterior landmarks.<sup>[2,3]</sup>

Although plane refers to a flat surface, the occlusal plane is not a straight line; rather it is a curve, representing the average curvature of the occlusal surfaces. The curvatures of occlusal plane are due to a large extent to the varying degrees of inclinations of natural teeth.<sup>[2,4-6]</sup> Anatomical landmarks that have been suggested to clinically help to determine the position of the occlusal plane are the upper lip, corners of the mouth, lateral margins of the tongue, buccinator grooves,  $\frac{2}{3}$  of the height of the retromolar pad, parallel to the Camper’s plane or ala-tragus line, 3.3 mm below the parotid papilla etc.<sup>[4-21]</sup>

Orientation of the occlusal plane is lost in patients rendered edentulous and should be relocated if complete dentures are to be esthetic and functional. It is difficult to find the optimal position of occlusal plane in every edentulous patient using the reported soft tissue landmarks.<sup>[22]</sup> Improper use of these landmarks may compromise the functional and esthetic result of the intended prosthetic rehabilitation.<sup>[23-26]</sup>

### Access this article online

#### Quick Response Code:



Website:  
www.ejgd.org

DOI:  
10.4103/2278-9626.116009

Hamular notch-incisive papilla (HIP) plane was reported in the literature to be useful in establishing the occlusal plane. The HIP plane can be defined as a plane extending from the hamular notches of the pterygoid hamulus to the incisive papilla. From these structures, the abbreviation HIP plane was derived. This plane remains unaltered even with the loss of teeth as incisive papilla and hamular notches appeared to be least affected by residual ridge resorption and remains visible.<sup>[27-31]</sup>

The HIP reference plane has been recognized by Cooperman and Willard (1960) as representing a “transit line plane” to diagnostically relate the maxillary arch to a horizontal reference table to disclose the degree of diseased occlusion in the natural dentition and in prostheses.<sup>[32]</sup>

Some authors have opined that angulation of the occlusal plane is generally related to skeletal base of maxilla and that the occlusal plane tends to be parallel to HIP plane.<sup>[31]</sup> Karkazis *et al.* concurred with this view after a cephalometric analysis of edentulous subjects.<sup>[32]</sup>

Rich, Karkazis, and Polyzois observed the parallel relation between HIP plane and occlusal plane. This study was designed to identify the parallel relationship of the HIP plane and maxillary occlusal plane. In dentulous situations, the defined occlusal plane passes through the cusp tips of the posterior teeth and incisal edges of anterior teeth and in edentulous situations, it is established using Ala-Tragal and interpupillary reference planes.<sup>[31,32]</sup>

## MATERIALS AND METHODS

Seventy subjects were chosen of which 50 were dentulous and 20 were edentulous subjects. The dentulous group was subdivided into subgroup I that consisted of 30 dentulous subjects of age group 16-19 years, whereas Group II consisted of 20 dentulous subjects of 50-55 years age group with moderate to severe attritional patterns on the occlusal surfaces of the teeth. Group III consisted of 20 completely edentulous subjects [Table 1].<sup>[33]</sup>

### Criteria for the selection of subjects used in the study

The dentulous subjects were seated in a dental chair in an upright position, and an accurate alginate impression of

maxillary dentulous arch was made with perforated metal stock tray. Making an accurate and clear impression of the hamular notches is very important and thus the accurate determination of HIP plane was achieved. In order to correctly register the position of bilateral hamular notches, our subjects were asked to open their mouth slightly to reduce the tension of the pterygomandibular raphe. Furthermore, the impression was made under minimal pressure to reduce soft-tissue distortion.

Dental stone casts of dentulous subjects were fabricated. In the edentulous casts, the maxillary occlusal rims were fabricated and the occlusal plane was clinically established parallel to Camper’s line and mid line was marked on the anterior aspect of the occlusal rim.<sup>[5,7,9,14,18,34]</sup>

### Standardization of the models

Base former was used to establish the upper casts of all subjects. One side of the cast was trimmed to produce a flat surface. The cast was then inverted so that the central incisors and the first molars in dentulous and the established occlusal plane in edentulous were in contact with a piece of 3 mm thick T-shaped polyvinyl chloride (fox plane) sheet. A horizontal line was scraped on the side of the base of the model with the tip of a pointer, which was 33 mm from the top of the table; the base of the cast was trimmed to the scraped line. The casts thus produced, were standardized with the occlusal plane parallel to the horizontal plane when the bases of the casts were placed on a flat horizontal surface like the flat granite platform of the of the three-dimensional precise measuring device.

### Surveying tools, positions and methods

This experiment utilized the accurate three-dimensional precise measuring device (Coordinate Three-Dimensional measuring machine – Guindy machine tools, Chennai, India) [Figure 1]. The tip of the electron probe was 1 mm in diameter with a liner accuracy of 0.003 mm. All the measured data were recorded and analyzed with the three-dimensional surveying software. In the dentulous casts, the midpoint of the incisive papilla and deepest points of the hamular notches were lightly touched by the electron probe of the three-dimensional analysis machine, to determine the HIP plane [Figures 1 and 2].

**Table 1: Inclusion criterias and division of groups**

Dentulous subjects (Group I, 16-19 years)	Group II (Group II, 50-55 years age)	Edentulous subjects (Group III)
With permanent teeth (28 or more) in ideal arch form and alignment	With permanent teeth (28 or more) in ideal arch form and alignment	Free of oral diseases
With no history of orthodontic treatment	With no history of orthodontic treatment	Free of temporomandibular disorders
With angle’s class I relationship,	With angle’s class I relationship	Good neuromuscular coordination present
With no extensive restorations,	With no extensive restorations	
Normal tooth form	Minimal to moderate attrition with normal tooth form	

In a similar way, the occlusal plane I (joining mesio-labial incisal edge of upper right central incisor – mesio-buccal cusp tips of upper first molars), occlusal plane II (joining mesio-labial incisal edge of upper right central incisor – mesio-buccal cusp tips of upper second molars), occlusal plane III (joining mesio-labial incisal edge of upper right central incisor – mesio-palatal cusp tips of upper first molars) and occlusal plane IV (joining mesio-labial incisal edge of upper right central incisor – mesio-palatal cusp tips of upper second molars) were determined<sup>[35]</sup> [Figure 3]. In group II individuals who have moderate to severe attrition, the point, which is most prominent in the occlusal facets of the above reference points is taken into consideration for the study which is determined by the tip of three-dimensional analyzing machine.

The angle between the HIP plane and each of the four different occlusal planes was measured; such an angle can be termed included angle. The general premise is: The lesser the included angle between the HIP plane and the occlusal plane chosen for evaluation, the greater would be the parallelism of that plane with HIP plane. Included

angles were measured between the HIP plane and the occlusal planes in Group I and Group II dental stone casts of the dentulous subjects using software (Metrologic-XG; France).

In edentulous stone casts, the deepest points of the hamular notches and the center of the incisive papilla were marked with an indelible marker and were lightly touched by the electron probe of the three-dimensional analysis machine, to determine the HIP plane, then the occlusal rims with recorded occlusal plane using camper's plane along with marked midline were placed on their individual patient's cast and a single angle was measured between the plane determined by joining the anterior reference point (marked near mesial aspect of the right central incisor region using marked midline as reference) and posterior reference points (joining the posterior points marked 1.5 cm from the deepest points of the hamular notches on the cast and transferred to the occlusal rim on the right and left 2<sup>nd</sup> molar regions) on clinically established occlusal plane and HIP plane [Figure 4].




Figure 1: Ruby tip electron probe of the three-dimensional analysis machine

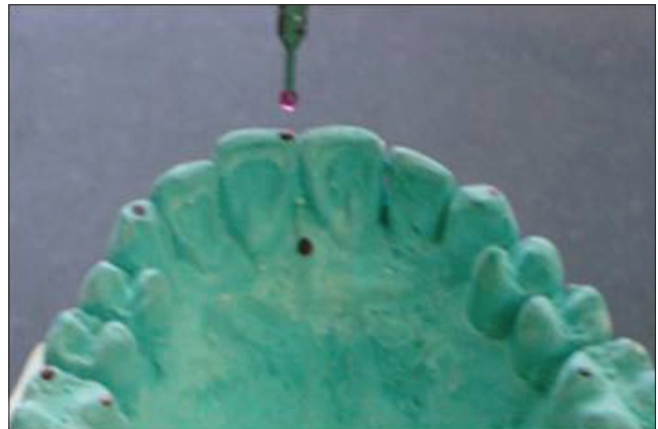

Figure 2: Electron probe of the three-dimensional analysis machine being used for determining the occlusal planes




Figure 3: Four occlusal planes and hamular notch-incisive papilla plane




Figure 4: Determined occlusal plane and hamular notch-incisive papilla plane

**Table 2: In group I (16-19 years-dentulous), the mean values with a standard deviation obtained for angles I, II, III and IV (from occlusal planes of I, II, III and IV to the hamular notch-incisive papilla plane in degrees)**

Angle between occlusal plane and HIP plane in degrees	Mean	Standard deviation	N
Angle 1	3.136	1.199	30
Angle 2	2.666	1.152	30
Angle 3	4.412	1.148	30
Angle 4	3.724	1.218	30

HIP – Hamular notch-incisive papilla

**Table 3: In group II (50-55 years-dentulous), the mean values with a standard deviation obtained for angles I, II, III, and IV (from occlusal planes of I, II, III, and IV to the hamular notch-incisive papilla plane in degrees)**

Angle between occlusal plane and HIP plane in degrees	Mean	Standard deviation	N
Angle 1	1.252	0.92	20
Angle 2	0.635	0.49	20
Angle 3	2.192	1.04	20
Angle 4	1.692	0.92	20

HIP – Hamular notch-incisive papilla

**Table 4: In Group III (completely edentulous), the mean value and the standard deviation obtained for angle was (in degree) occlusal plane to the hamular notch-incisive papilla plane**

Location	Mean	Standard deviation	N
Anterior	9.033640	1.9945953	20
Posterior	8.674510	1.8220947	20

**Table 5: Inter group comparison of angulations analysis of variance**

ANOVA test	Sum of squares	Df	Mean square	F value	Significance
Between group	50.641	2	25.320	21.507	0.000
Within groups	78.878	67	1.177	-	-
Total	129.519	69	-	-	-

DF – Degrees of freedom; ANOVA – Analysis of variance

**Table 6: Post hoc comparison of angulations among all groups (Tukey Honestly significant difference test)**

Group interactions section A-section B	Mean difference (A-B)	Standard error	Significance	95 % confidence interval	
				Lower bound	Upper bound
Group I	2.0305483*	0.3132207	0.000	1.279795	2.781301
Group II Group III	1.0975583*	0.3132207	0.002	0.346805	1.848311
Group II	-2.0305483*	0.3132207	0.000	-2.781301	-1.279795
Group I Group III	-0.9329900*	0.3431161	0.022	-1.755399	-0.110581
Group III	-1.975583*	0.3132207	0.002	-1.848311	-0.346805
Group I Group II	0.9329900*	0.3431161	0.022	0.110581	1.755399

\*The mean difference is significant at the 0.05 level

## RESULTS

The mean and standard deviation values for the angles were measured from the occlusal planes to the HIP plane for Group I, II, and III subject’s maxillary casts (16-19 years-dentulous) followed by Pearson’s correlation test for individual groups [Tables 2-4].

## INTER GROUP COMPARISON

One-way ANOVA test between Group I (16-19 years-dentulous), Group II (50-55 years-dentulous), and Group III (completely edentulous) [Table 5]. One-way ANOVA results between the groups showed that they were highly significant indicating that there is a variation in occlusal plane level for the three groups [Figure 5].

One-way ANOVA between the groups has statistically significant difference with *P* value at 0.00 levels.

The horizontal axis shows the Groups and the vertical axis shows the means of the angles of three groups in degrees. The Group I has the highest mean value and the Group II has the smallest mean value. The angle of the Group III tends to be established closer to the Group II. (Since angle II is closest in Group I and II to HIP plane, same was compared with the angle of edentulous group).

## POST-HOC TEST

Tukey HSD (Honestly Significant Difference) test indicated that angle II of Group II (50-55 years-dentulous) is closest to the HIP plane. Angle of the Group III subjects was between the angle II of the Group I and II

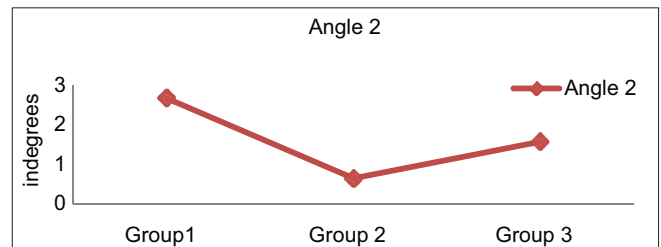


Figure 5: Relationship between the angles of the three groups

subjects [Table 6]. Student *t*-test was carried out between all angles for males and females in all the groups. Results showed that they were not statistically significant indicating that there is no gender difference for occlusal plane orientation.

## DISCUSSION

In this study, an attempt has been made to compare the occlusal plane to the HIP plane in dentulous and edentulous subjects using three-dimensional analysis machine and to find its reliability as an anatomical landmark in establishing the occlusal plane in edentulous subjects. This study used the tip of the electron probe of 1 mm diameter of the three-dimensional measuring machine to analyze various reference points in the dental casts.<sup>[36]</sup> This procedure has been proved to be an accurate method for determining the occlusal plane as has been shown in the previous studies conducted by Arakawa 1980, Otthoff *et al.* 2000, Kojima 2003 and Fu *et al.* 2007.<sup>[35-37]</sup> The apparent limitation of analyzing the dental casts could be that there can be some error while matching reference points and fabrication of bite blocks. However, accuracy of the electron probe (0.003 mm) makes the error negligible. The results of the present study confirm the previous observations of Rich and Karkazis and Polyzois who applied cephalometry to investigate the relationship between the occlusal plane (defined as the mesio – incisal edge of upper central incisor and mesio – palatal cusp tips of upper first molars) and HIP plane that the HIP plane tends to be parallel to the occlusal plane.<sup>[31,32]</sup>

In this study, both males and females were examined in all 3 age groups. The results showed that there is no statistical difference between both sexes. This indicates that HIP plane can be used as a guide to establish occlusal plane irrespective of the gender. The present study revealed that the occlusal plane II was most parallel to HIP plane in dentulous subjects and this is in agreement with the results of Fu *et al.* in a study of 100 Taiwanese young adults ( $2.61 \pm 0.81^\circ$ ), suggesting that HIP plane can be used as another anatomical landmark for the orientation of the occlusal plane in edentulous subjects.<sup>[37]</sup> There exists a definite parallelism between occlusal plane and HIP plane. The three-dimensional analyzer can be used to perform direct measurement of the dental cast and express occlusal plane in a co-ordinate system.

## CONCLUSION

The objective of this study was to determine the parallelism of the HIP plane to the occlusal plane in three different age groups using a three-dimensional analyzing machine. Within the limitations of the present study, the following conclusions could be drawn:

1. The HIP plane is parallel to the natural occlusal plane
2. The HIP plane can be used as a reference plane to re-establish the occlusal plane in edentulous patients
3. There is no difference in gender with respect to parallelism of the occlusal plane to HIP plane
4. This study shows that the three-dimensional analyzing machine is a precise machine for the accurate measurement of the included angles in the maxillary casts
5. The occlusal plane tends to be more parallel in Group II subjects (50-55 years) than the Group I subjects (16-19 years).

## REFERENCES

1. The glossary of prosthodontic terms. J Prosthet Dent 2005;94:10-92.
2. Curtis TA, Shaw EL, Curtis DA. The influence of removable prosthodontic procedures and concepts on the esthetics of complete dentures. J Prosthet Dent 1987;57:315-23.
3. Shigli K, Chetal BR, Jabade J. Validity of soft tissue landmarks in determining the occlusal plane. J Indian Prosthodont Soc 2005;5:139-45.
4. Lundquist DO, Luther WW. Occlusal plane determination. J Prosthet Dent 1970;23:489-98.
5. Williams DR. Occlusal plane orientation in complete denture construction. J Dent 1982;10:311-6.
6. Gupta R, Himanshu A, Singh SP. Relationship of anatomical landmarks with occlusal plane. J Indian Prosthodont Soc 2009;9:142-7.
7. Landa JA. A scientific approach to the study of the temporomandibular joint and its relation to occlusal disharmonies. J Prosthet Dent 1957;7:170.
8. Yasaki M. Height of the occlusion rim and the inter-occlusal distance. J Prosthet Dent 1961;11:26.
9. Ismail YH, Bowman JF. Position of the occlusal plane in natural and artificial teeth. J Prosthet Dent 1968;20:407-11.
10. Rhonda J, Steven E, Zarb GA, Bolender CL. Boucher's Prosthodontic for Edentulous Patients. 12<sup>th</sup> ed. St. Louis: CV Mosby Co; 2004. p. 292.
11. Broomell IN. The value of temperamental indications in the correct prosthesis of entire dentures. Dent Cosmos 1897;39:1.
12. Augsburg RH. Occlusal plane relation to facial type. J Prosthet Dent 1953;3:755-70.
13. Schlosser FW, Gehl DH. Complete Denture Prosthetics. 3<sup>rd</sup> ed. Philadelphia: Saunders; 1953. p. 190.
14. Sharry JJ. Complete Denture Prosthodontics. 3<sup>rd</sup> ed. Philadelphia: Lea and Febiger; 1974. p. 236.
15. Ricketts RM. The role of cephalometrics in prosthetic diagnosis. J Prosthet Dent 1956;6:488.
16. Levin B, Sauer JL Jr. Results of a survey of complete denture procedures taught in American and Canadian dental schools. J Prosthet Dent 1969;22:171-7.
17. Abrahams R, Carey PD. The use of the ala-tragus line for occlusal plane determination in complete dentures. J Dent 1979;7:339-41.
18. van Niekerk FW, Miller VJ, Bibby RE. The ala-tragus line in complete denture prosthodontics. J Prosthet Dent 1985;53:67-9.
19. Javid NS. A technique for determination of the occlusal plane. J Prosthet Dent 1974;31:270-2.
20. Kazanoglu A, Unger JW. Determining the occlusal plane with the Camper's plane indicator. J Prosthet Dent 1992;67:499-501.
21. Foley PF, Latta GH Jr. A study of the position of the parotid papilla relative to the occlusal plane. J Prosthet Dent 1985;53:124-6.

22. Ernest WW. The facial line and angles in prosthetic dentistry. *Dent Cosmos* 1897;39:789-800.
23. Monteith BD. A cephalometric method to determine the angulation of the occlusal plane in edentulous patients. *J Prosthet Dent* 1985;54:81-7.
24. Ow RK, Djeng SK, Ho CK. Orientation of the plane of occlusion. *J Prosthet Dent* 1990;64:31-6.
25. Chaconas SJ, Gonidis D. A cephalometric technique for prosthodontic diagnosis and treatment planning. *J Prosthet Dent* 1986;56:567-74.
26. Jayachandran S, Ramachandran CR, Varghese R. Occlusal plane orientation: A statistical and clinical analysis in different clinical situations. *J Prosthodont* 2008;17:572-5.
27. Harper RN. The incisive papilla. *J Dent Res* 1948;27:661.
28. Ehrlich J, Gazit E. Relationship of the maxillary central incisors and canines to the incisive papilla. *J Oral Rehabil* 1975;2:309-12.
29. Grave AM, Becker PJ. Evaluation of the incisive papilla as a guide to anterior tooth position. *J Prosthet Dent* 1987;57:712-4.
30. Sloane RH, Cook J. A guide to orientation of the occlusal plane. *J Prosthet Dent* 1953;3:33.
31. Karkazis HC, Polyzois GL. Cephalometrically predicted occlusal plane: Implications in removable prosthodontics. *J Prosthet Dent* 1991;65:258-64.
32. Cooperman HN: HIP plane of occlusion in oral diagnosis. *Dent Sury* 1975;51:60-2.
33. Ferrario VF, Sforza C, Serrao G, Schmitz JH. Three-dimensional assessment of the reliability of a postural face-bow transfer. *J Prosthet Dent* 2002;87:210-5.
34. Zarb GA, Carlsson GE, Bolender CL. *Prosthodontic Treatment for Edentulous Patients. Complete Dentures and Implant-Supported Protheses*. 12<sup>th</sup> ed. St. Louis, MO: Mosby; 2004. p. 262-4.
35. Fu PS, Hung CC, Hong JM, Wang JC, Tsai CF, Wu YM. Three-dimensional relationship of the maxillary anterior teeth to the incisive papilla in young adults. *Kaohsiung J Med Sci* 2007;23:519-25.
36. Kojima T, Sohmura T, Nagao M, Wakabayashi K, Nakamura T, Takahashi J. A preliminary report on a computer-assisted dental cast analysis system used for the prosthodontic treatment. *J Oral Rehabil* 2003;30:526-31.
37. Fu PS, Hung CC, Hong JM, Wang JC. Three-dimensional analysis of the occlusal plane related to the hamular-incisive-papilla occlusal plane in young adults. *J Oral Rehabil* 2007;34:136-40.

**How to cite this article:** Singh K, Lakshmi N, Agnihotri Y, Suvarna SR, Sahoo S, Kumar P. Three-dimensional analysis to compare parallelism of occlusal planes to the hamular notch-incisive papilla plane in dentulous and edentulous subjects. *Eur J Gen Dent* 2013;2:286-91.

**Source of Support:** Nil, **Conflict of Interest:** None declared.

## New features on the journal's website

### Optimized content for mobile and hand-held devices

HTML pages have been optimized of mobile and other hand-held devices (such as iPad, Kindle, iPod) for faster browsing speed.

Click on **[Mobile Full text]** from Table of Contents page.

This is simple HTML version for faster download on mobiles (if viewed on desktop, it will be automatically redirected to full HTML version)

### E-Pub for hand-held devices

EPUB is an open e-book standard recommended by The International Digital Publishing Forum which is designed for reflowable content i.e. the text display can be optimized for a particular display device.

Click on **[EPub]** from Table of Contents page.

There are various e-Pub readers such as for Windows: Digital Editions, OS X: Calibre/Bookworm, iPhone/iPod Touch/iPad: Stanza, and Linux: Calibre/Bookworm.

### E-Book for desktop

One can also see the entire issue as printed here in a 'flip book' version on desktops.

Links are available from Current Issue as well as Archives pages.

Click on  View as eBook