Article published online: 2021-11-01

SHORT COMMUNICATION

Adenomatoid odontogenic tumor expressing p53 and PCNA: A true benign neoplasm?

Kunal Sah, Alka D. Kale[1], Vijaylaxmi Kotrashetti[1], Sunira Chandra[2]

Departments of Oral Pathology and Microbiology, [2]Oral Medicine and Radiology, Saraswati Dental College and Hospital, Faizabad Road, Lucknow, Uttar Pradesh, [1]Department of Oral Pathology and Microbiology, VK KLE Institute of Dental Sciences, KLE University, Belgaum, Karnataka, India

Address for correspondence:
Dr. Kunal Sah,
Department of Oral Pathology and Microbiology, Saraswati Dental College and Hospital, Faizabad Road, Lucknow - 227105, Uttar Pradesh, India.
E-mail: steps_32kunal@hotmail.com

ABSTRACT

Adenomatoid odontogenic tumor (AOT) is a relatively uncommon distinct odontogenic neoplasm. Histogenesis of AOT is still uncertain, and whether it represents anomalous hamartomatous growth or a true benign neoplasm is debatable. We report herein an unusual case of AOT occurring in the mandible. The tumor showed an unusual and aggressive clinical course, location, and radiographical and histopathological features expressing PCNA and p53 protein, which are suggestive of its proliferative potential, aggressive tumor behavior, and invasive characteristics. Based on these evidences, we suggested it to be a benign aggressive neoplasm rather than a hamartoma, though based on the analysis of single case it is still debatable.

Key words
Adenomatoid odontogenic tumor, mandible, neoplasm, p53 protein, PCNA

INTRODUCTION

Adenomatoid odontogenic tumor (AOT) is a relatively uncommon and distinct odontogenic neoplasm that was first described by Steensland in 1905. Philipsen and Birn proposed the name AOT, which is widely accepted and used currently.[1] Some authors believe it to be a true benign, non-aggressive, non-invasive neoplasm, but few categorize it as a developmental hamartomatous odontogenic growth.[2]

CASE REPORT

A 17-year-old male patient presented with the chief complaint of swelling on the right side of the lower jaw, which was asymptomatic for the past 2 months. The patient's dental and medical histories were noncontributory. Facial asymmetry was evident on the right side. Intraorally, a well-defined dome shaped 2 × 1.5 cm swelling was present, extending from distal of 42 to mesial of 45, obliterating the labial, buccal, and lingual vestibule [Figure 1a and b]. Overlying mucosa appeared normal and smooth. On palpation, the swelling was bony hard, non-tender, and immobile, while 43, 44 were displaced and 46 was grossly carious and non-tender.

Radiographically, orthopantomogram (OPG) showed a well-defined radiolucent lesion with displacement of 43, 44 with resorption of root apices of 44, 45 and mesial root of 46 [Figure 1c]. Mandibular occlusal radiograph showed expansion and thinning of buccal and lingual cortical plate [Figure 1d]. Surgical excision of the lesion was done under local anesthesia. On gross examination, the specimen appeared as a single, pink-white, soft tissue mass measuring 2.6 × 2 cm in diameter [Figure 2a]. Cut surface showed cystic area full of soft tissue nodules surrounded by a thick capsule [Figure 2b and c].

Microscopic examination showed cystic space lined by focal solid areas of the tumor islands having polyhedral to spindle cells forming various patterns [Figure 3a-c]. Tumor nests were highly cellular with nuclear hyperchromatism and mitotic figures [Figure 3d-f]. Tumor cells showed invasion into the capsule [Figure 3g]. Due to the following unconventional histopathological features, we decided to perform immunohistochemical staining for PCNA and p53. Cellular areas showed positivity for PCNA ++ [Figure 3h] and p53 protein + [Figure 3i]. Based on clinico-pathological features,

Access this article online	
Quick Response Code:	Website: www.ejgd.org
	DOI: 10.4103/2278-9626.116007

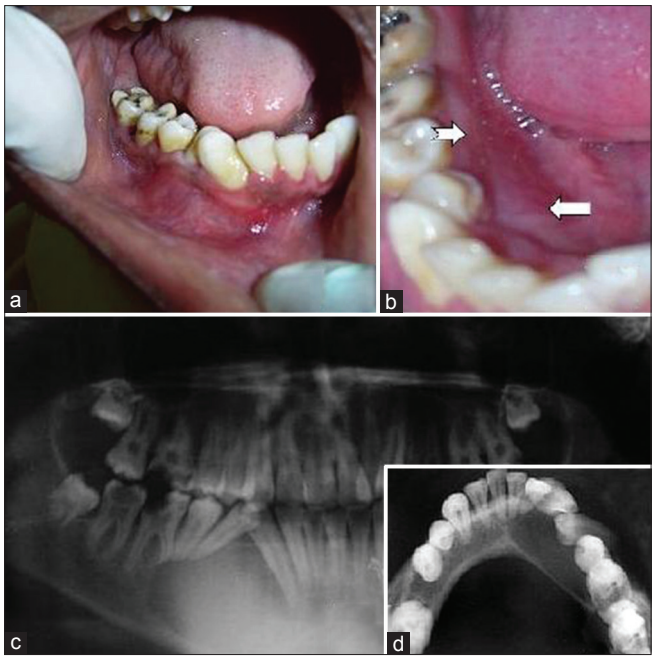

Figure 1: Intraoral photograph; (a) Buccal view; (b) Lingual view; (c) Panoramic radiograph showing radiolucent lesion in the right mandibule with displacement and resorption of root apices of 44, 45 and mesial root of 46; (d) Mandibular occlusal radiograph showing expansion of buccal cortical plate

Figure 2: (a) Gross specimen with extracted 42, 43, 44, 45, and 46; (b and c) Cut surface showing tumor nodules with capsule filled with blood clot

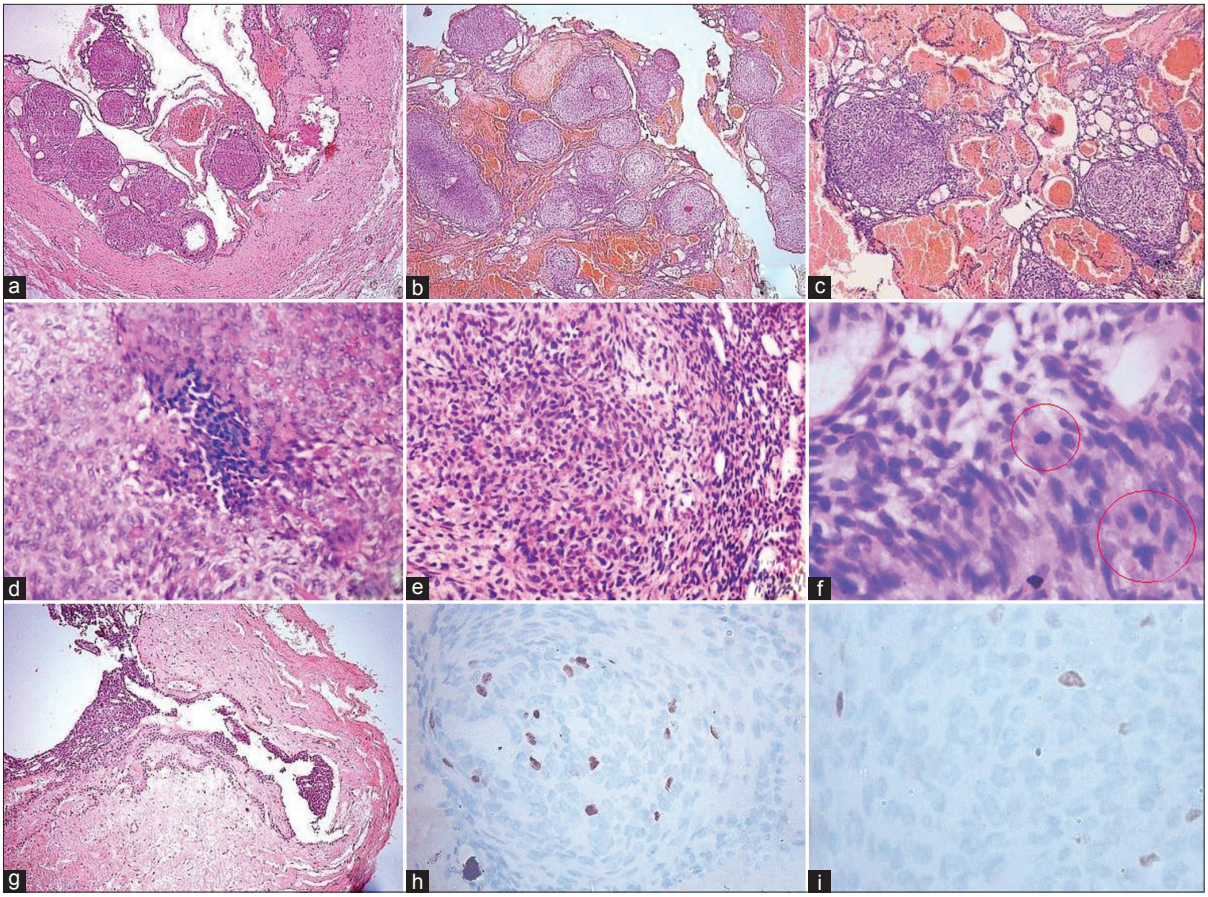

Figure 3: Cystic space lined by focal solid areas of the tumor cells (a, H and E ×4). Polyhedral to spindle cells forming nests, cords, ducts, rossette, cribriform, and lace-like patterns (b, c, H and E ×4, ×10). Highly cellular tumor nests showing nuclear hyperchromatism (d, e, H and E ×40). Prominent mitotic figures (f, H and E ×40). Tumor cells invading the capsule (g, H and E ×4). Tumor nests shows positivity for PCNA ++ (IHC, ×40) and p53 protein + (i, IHC, ×40)

diagnosis of an aggressive extrafollicular AOT of mandible was made.

DISCUSSION

AOT is an uncommon, benign, and slow-growing tumor, and it represents 3% of all odontogenic tumors.[3] Sometimes referred to as "two-third tumor" because two-third of cases occur in the maxilla, it arises in young females and is associated with an unerupted canine.[1] It often causes expansion of surrounding bone and displacement of adjacent teeth. However, the slow growing nature of the lesion takes years until it produces an obvious deformity. Although larger lesions are reported in the literature, the tumors are usually in the dimensions of 1.5-3 cm.

The tumor has three clinicopathological variants, namely intraosseous follicular, intraosseous extrafollicular, and peripheral. The follicular type (in 73% of all AOT cases) is associated with an unerupted tooth, whereas extrafollicular type (24%) has no relation with an impacted tooth, and the peripheral variant (3%) is attached to the gingival structures.[3]

Radiographically, they usually appear unilocular and may contain fine calcifications; irregular root resorption is rare in them.[4] The tumor may be partly cystic and, in some cases, the solid lesion may be present. It comprises of odontogenic epithelium with various patterns and with varying degrees of inductive change in the connective tissue. However, very few cases with mitotic figures are reported.[4] The tumor may contain pools of eosinophillic, uncalcified, amorphous material called "tumor droplets" and globular masses of calcified material. The tumor is well encapsulated. Therefore, conservative surgical enucleation produces excellent outcome without recurrence.[5]

Histogenesis of AOT is uncertain; there has been long debate on whether it represents anomalous hamartomatous growth or is a true benign neoplasm. The 1971 WHO classification stated, "it is generally believed that the lesion is not a neoplasm." Glickman *et al.*, concluded that "such a controversy is irresolvable because sound argument can be advanced in favor of and against both hypothesis. The arguments are based on personal bias rather than on scientific evidence."[1]

Currently, immunohistochemical (IHC) markers have been widely used, especially in tumor progression tests. One of the oldest markers is P53. Naturally, P53 is a tumor-suppressor gene for abnormal mitotic activity.[6] PCNA are proteins with expression in mitotic cells; they are widely used in studies to determine tumoral activity.[7,8]

Marcelo *et al.*, in there study on the origin and nature of AOT found PCNA positivity and negativity for p53 protein expression. They concluded that AOT is hamartoma and not a neoplasia.[9] Medeiros *et al.*, applied two markers, P53 and PCNA, in 8 cases of AOT, IHC markers were very low and therefore they concluded that AOT is a hamartoma rather than a tumor.[10] In a survey by Leon *et al.* in 2005, Ki-67 IHC marker was evaluated in 39 cases of AOT. Expression of this marker was very low in AOT (LI < 1%), therefore, the investigators concluded that this tumor growth is very slow and it cannot invade adjacent tissues.[11] According to these studies, AOT had hamartomatosis behavior and it does not have the tendency to recur, therefore the treatment for AOT is just an enucleation.[9-11]

Gomes *et al.*, preformed HUMARA gene polymorphism assay on odontogenic tumor and suggested that, among other odontogenic tumors, AOTs are monoclonal and therefore neoplastic.[12] Nigam *et al.*, also accepted it to be a true neoplasm.[13] Whereas Barboza *et al.*, found positivity for PCNA and weak expression of p53 to determine the proliferative nature.[14] Similarly, in the present case, we found high positivity for PCNA and weak reaction for p53 protein, suggestive of its proliferative potential, aggressive tumor behavior, and invasive characteristics.

CONCLUSION

This unconventional case report of an AOT shows some unusual clinical, radiological, and histopathological features expressing PCNA and p53 protein suggestive of its proliferative potential, aggressive tumor behavior, and invasive characteristics [Table 1]. Taking all these evidence together, we suggest that such an aggressive cases should be considered as true benign neoplasm, although based on analysis of single case, it is not possible to draw any conclusions of this kind and this topic remains debatable. Aggressive treatment protocol should be laid down for such type of unconventional AOT. Further analysis is required to delineate the genetic background of these aggressive AOTs.

Table 1: Unconventional features in the present case

Clinical and radiological features
17-year-old male
Mandibular location
Aggressive clinical course: 2 months
Tumor size: 2.6×2 cm
Displacement and resorption of root apices: 44, 45, 46
Expansion and thinning of buccal and lingual cortical plate
Histopathological features
Varied patterns of arrangement
Increased cellularity
Hyperchromatism
Prominent mitotic figures
Invasion into the capsule
PCNA expression positive: ++
P53 expression positive: +

REFERENCES

1. Garg D, Palaskar S, Shetty VP, Bhushan A. Adenomatoid odontogenic tumor-hamartoma or true neoplasm: A case report. J Oral Sci 2009;51:155-9.
2. Philipsen HP, Reichart PA, Siar CH, Ng KH, Lau SH, Zhang X, *et al.* An updated clinical and epidemiological profile of the adenomatoid odontogenic tumour: A collaborative retrospective study collaborative retrospective study. J Oral Pathol Med 2007;36:383-93.
3. Yilmaz N, Acikgoz A, Celebi N, Zengin AZ, Gunhan O. Extrafollicular adenomatoid odontogenic tumor of the mandible: Report of a case. Eur J Dent 2009;3:71-4.
4. Nomura M, Tanimoto K, Takata T, Shimosato T. Mandibular adenomatoid odontogenic tumor with unusual clinicopathologic features. J Oral Maxillofac Surg 1992;50:282-5.
5. Handschel JG, Depprich RA, Zimmermann AC, Braunstein S, Kübler NR. Adenomatoid odontogenic tumor of the mandible: Review of the literature and report of a rare case. Head Face Med 2005;1:3.
6. Gnepp DR, Chen JC, Warren C. Polymorphous low grade adenocarcinoma of minor salivary gland. An immunohistochemical and clinicopathologic study. Am J Surg Pathol 1988;12:461-8.
7. Dhanuthai K, Chantarangsu S, Swasdison S. Proliferating cell nuclear antigen expression in odontogenic cysts and ameloblastomas. Asian J Oral Maxillofac Surg 2005;17:6-10.
8. Suzuki H, Hashimoto K. Adenomatoid odontogenic tumour of the maxilla: Immunohistochemical study. Asian J Oral Maxillofac Surg 2005;17:267-2.
9. Crivelini MM, Soubhia AM, Renata Callestini Felipini RC. Study on the origin and nature of the AOT by immunohistochemistry J Appl Oral Sci 2005;13:406-12.
10. de Medeiros AM, Nonaka CF, Galvão HC, Souza LB, Freitas Rde A. Expression of extracellular matrix proteins in ameloblastoma and adenomatoid odontogenic tumors. Eur Arch Otorhinolaryngol 2010;267:303-10.
11. Leon JE, Mata GM, Fregnani ER, Carlos-Bregni R, de Almeida OP, Mosqueda-Taylor A, *et al.* Clinicopathological and immunohistochemical study of 39 cases of adenomatoid odontogenic tumour: A multicentric study. Oral Oncol 2005;41:835-42.
12. Gomes CC, Oliveira Cda S, Castro WH, de Lacerda JC, Gomez RS. Clonal nature of odontogenic tumor. J Oral Pathol Med 2009;38:397-400.
13. Nigam S, Gupta SK, Chaturvedi KU. Adenamatoid odontogenic tumor-a rare cause of jaw swelling. Braz Dent J 2005;16:251-3.
14. Barboza CA, Pereira Pinto L, Freitas Rde A, Costa Ade L, Souza LB. Proliferating cell nuclear antigen and p53 protein expression in ameloblastoma and AOT. Braz Dent J 2005;16:56-61.

How to cite this article: Sah K, Kale AD, Kotrashetti V, Chandra S. Adenomatoid odontogenic tumor expressing p53 and PCNA: A true benign neoplasm?. Eur J Gen Dent 2013;2:328-31.

Source of Support: Nil, **Conflict of Interest:** None declared.

"Quick Response Code" link for full text articles

The journal issue has a unique new feature for reaching to the journal's website without typing a single letter. Each article on its first page has a "Quick Response Code". Using any mobile or other hand-held device with camera and GPRS/other internet source, one can reach to the full text of that particular article on the journal's website. Start a QR-code reading software (see list of free applications from http://tinyurl.com/yzlh2tc) and point the camera to the QR-code printed in the journal. It will automatically take you to the HTML full text of that article. One can also use a desktop or laptop with web camera for similar functionality. See http://tinyurl.com/2bw7fn3 or http://tinyurl.com/3ysr3me for the free applications.