

Multiple regenerative techniques for class II furcation defect

Pushpendra Kumar Verma, Ruchi Srivastava, Anju Gautam, T. P. Chaturvedi

Department of Dental Sciences, I.M.S., Banaras Hindu University, Varanasi, Uttar Pradesh, India

Address for correspondence:

Dr. Pushpendra Kumar Verma,
Department of Dental Sciences, I.M.S.,
Banaras Hindu University,
Varanasi - 221005, Uttar Pradesh, India.
E-mail: pushpendrakgmc@gmail.com

ABSTRACT

Regeneration of the periodontium is a major goal in the treatment of teeth affected by periodontitis. Periodontal regeneration is quite challenging, especially when it is in the furcation area. There are several techniques used alone or in combination, considered to achieve periodontal regeneration, including bone grafts or substitutes, guided tissue regeneration, root surface modification, and biological mediators. Many factors may account for variability in the response to regenerative therapy in class II furcation. This case report describes the management of a buccal class II furcation defect, with the help of surgical intervention, including the guided tissue regeneration (GTR) membrane and bone graft materials. This combined treatment resulted in a healthy periodontium, with radiographic evidence of alveolar bone gain. This case report demonstrates that proper diagnosis, followed by removal of the etiological factors and utilizing combined treatment modalities, restored health and function of the tooth with severe attachment loss, at the 18-month follow-up.

Key words

Class II furcation, furcation involvement, guided tissue regeneration, periodontal regeneration

INTRODUCTION

The ultimate objective of periodontal therapy is to regenerate tissues, lost as a consequence of periodontal disease. Lesions of the periodontal ligament and adjacent alveolar bone may originate from infections of the periodontium or dental tissues.^[1] However, when a significant loss of the periodontal attachment apparatus and osseous structure occurs, the long-term prognosis becomes poor.^[2] There are several techniques used alone or in combination, which are considered to achieve periodontal regeneration, including bone grafts or substitutes, guided tissue regeneration, root surface modification, and biological mediators.^[3]

One of the most important indications for the guided tissue regeneration (GTR) treatment is the class II furcation defect. In GTR, a barrier is inserted between the root surface and the gingival tissues, to inhibit the apical migration of the epithelium and gingival connective tissue of the flap, allowing the granulation

tissue derived from the periodontal ligament and osseous tissues to repopulate the space adjacent to the denuded root surface.^[4] Historically, the expanded polytetrafluoroethylene membrane was utilized during this procedure, which is non-resorbable and requires a second surgical intervention after several months, for its removal. At present, a variety of bio-resorbable matrix barriers are available that slowly resorb and are gradually replaced by periodontal tissue, thus eliminating the need for a secondary surgical intervention.

Clinical studies have shown that GTR can improve the response of class II furcation defects to therapy by means of pocket reduction, gain in clinical attachment levels, and bone defect fill. Regenerative procedures frequently include the use of GTR barrier membranes and bone grafting materials to encourage the growth of the surrounding tissues, while excluding unwanted cell types, such as epithelial cells. Here is a case report showing regeneration in buccal class II furcation with a bone graft and GTR membrane.

CASE REPORT

A 45-year-old female patient came to the Faculty of Dental Sciences, BHU, Varanasi, India, with a chief complaint of pain and continuous discomfort in the lower right posterior region of the jaw, since two months. The patient's medical history was uneventful. On clinical examination, signs of inflammation were present in tooth

Access this article online

Quick Response Code:



Website:

www.ejgd.org

DOI:

10.4103/2278-9626.103389

46, with a probing depth of 4 mm and class II buccal furcation involvement [Figure 1]. Mobility was absent and a periapical radiograph showed a deep bony defect in the furcation of 46 [Figure 2]. Therefore, considering the dental history and radiographs, first a root canal treatment was performed and then a periodontal surgery was planned. After local anesthesia, a mucoperiosteal flap was raised. Severe osseous destruction was observed in the buccal furcation of 46. The horizontal attachment loss was about 5mm [Figure 3]. After thorough root planing, this large osseous defect, at furcation, was filled with bone graft (Perio bone-G, alloplastic graft) and GTR membrane (Periocol-GTR, resorbable) covering the root surface [Figures 4-6]. The flap was repositioned and sutured with 3-0 silk non-resorbable interrupted sutures [Figure 7]. Periodontal dressing was placed [Figure 8]. Antibiotics and analgesics were prescribed for one week. The sutures were removed five days later. The patient was monitored on a weekly schedule postoperatively, to ensure good oral hygiene in the surgerized area [Figure 9]. Supportive periodontal maintenance at three months was prescribed to maintain periodontal health and to re-evaluate this area. At the 18-month recall, the tooth was

asymptomatic, with successful healing, and the probing depth was minimal. The radiograph, after the 18-month follow-up, showed evidence of apparent bone fill, with resolution of the osseous defect [Figure 10].

DISCUSSION

Regeneration of periodontal hard and soft tissues, including formation of a new attachment apparatus is the main aim of regenerative therapy. Traditional approaches to treat periodontal and endodontic defects, include, nonsurgical debridement of root surfaces or root canals, as well as surgical approaches that provide better access to clean the root surfaces and apical lesions, and to reshape the surrounding bone / root apex. Bone loss caused by pulpal disease is reversible, whereas, advanced bone loss caused by periodontal disease is usually irreversible. The necessity of periodontal surgical therapy is most likely because the periodontal bone loss was more advanced and less likely to resolve after non-surgical therapy alone.^[1] However, periodontal regeneration in furcation defects, although possible, is

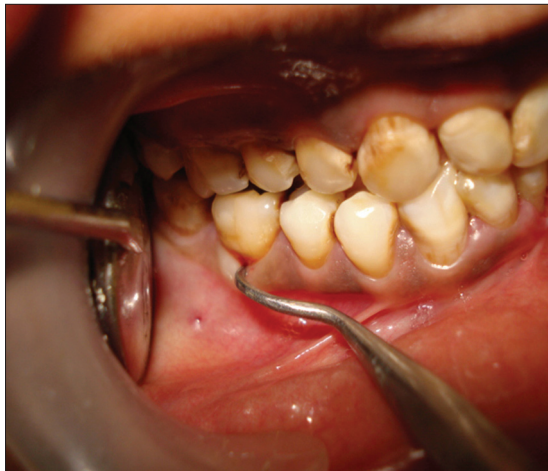

Figure 1: Pre-operative view of tooth 46

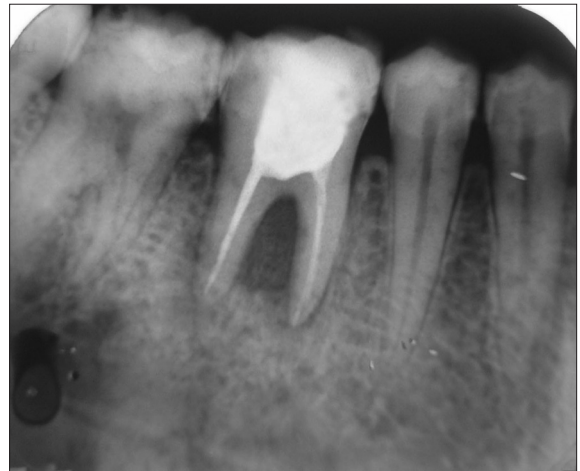

Figure 2: Pre-operative intra oral periapical (IOPA) X-ray

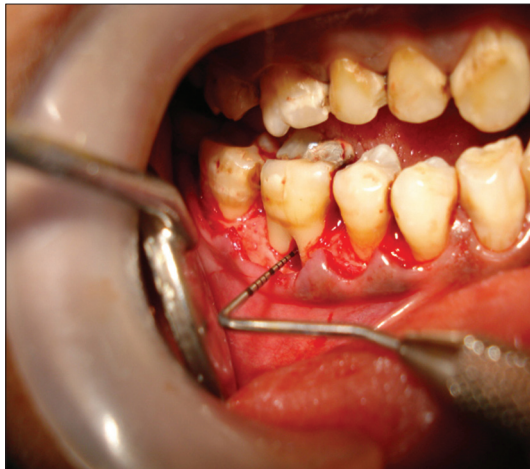


Figure 3: Flap reflected

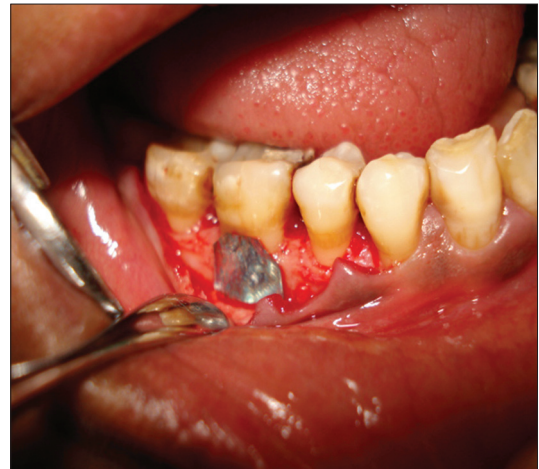

Figure 4: Foil placed to determine size of GTR

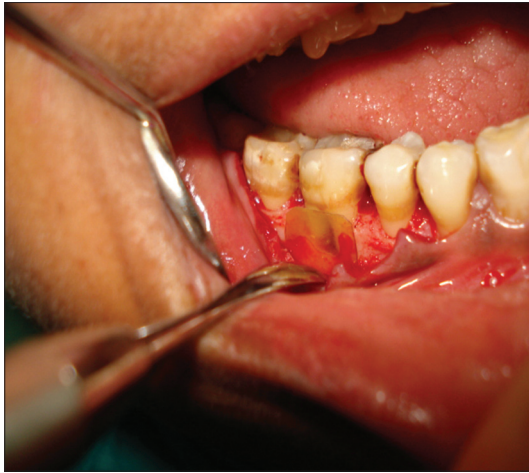

Figure 5: Size determination before GTR placement

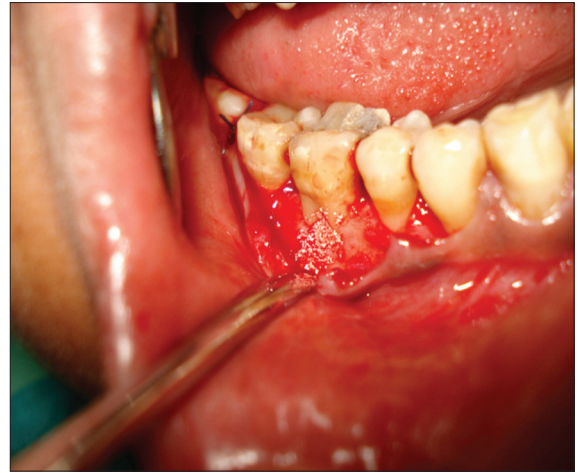

Figure 6: Bone graft placed

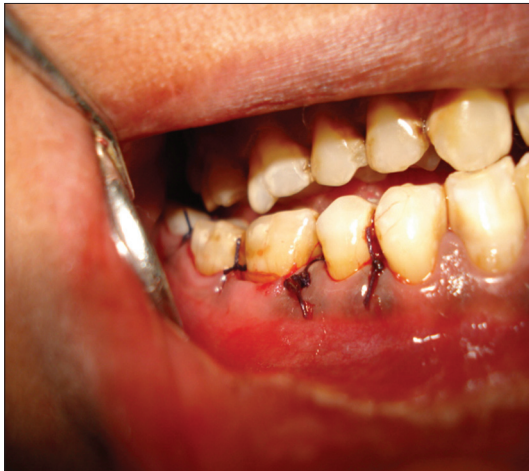

Figure 7: Sutures placed

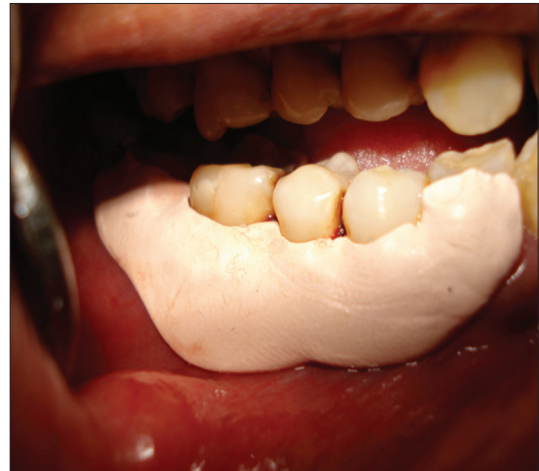

Figure 8: Periodontal dressing

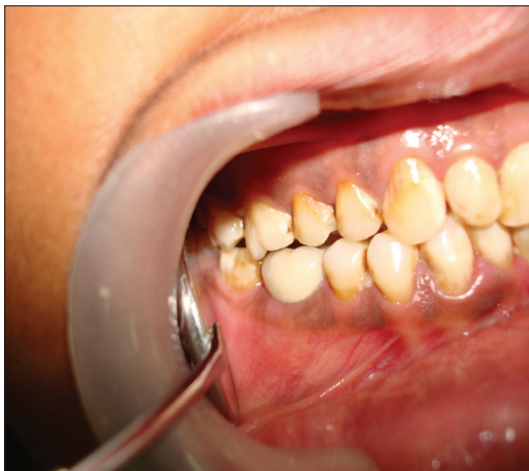

Figure 9: Post-operative view of tooth 46

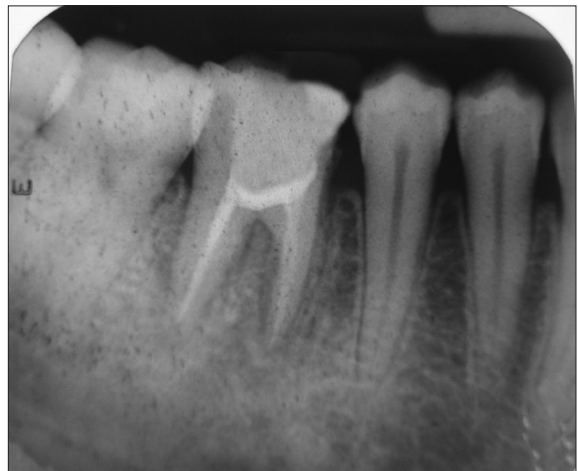

Figure 10: Post-operative IOPA X-ray

not considered totally predictable, especially in terms of a complete bone fill. Many factors may account for variability in the response to regenerative therapy in class II furcation. Novaes and Novaes^[5] have reported eight different situations of class II furcations in which GTR is

not indicated: (a) Lack of access for adequate debridement of the furcation, (b) endodontic or prosthetic perforations in the furcation areas of the roots, (c) crown lengthening procedures that invade the furcations, (d) root proximities untreatable by the restorative alveolar interface (RAI)

technique, (e) extensive gingival recessions, (f) deep caries involving the roots, (g) untreatable endo-perio lesions, and (h) longitudinal root fractures. In these cases, hemisection is recommended. It must be noted that there are many factors acting collectively that influence the final outcome of GTR in class II furcations. Selecting a defect that is amenable to regeneration is also critical for achieving success.^[6] Wang and Boyapati^[7] have suggested four factors, the so-called PASS principles, that are critical for predictable bone regeneration: Primary wound closure, angiogenesis as a blood supply and source of undifferentiated mesenchymal cells, space maintenance, and stability of the wound. GTR has offered better results than open-flap debridement or bone replacement grafts alone, in class II furcation.^[8] Despite achieving significant positive gains in the new attachment using GTR, consistent successful treatment of mesial furcation defects with membrane techniques remains a challenge. Furcation morphology may restrict access to adequate debridement and root instrumentation, and may have a reduced source of available cells and blood supply from the periodontal ligament and bone defect.^[9] One important factor for successful regeneration at the furcation and non-furcation sites is the amount of periodontium that remains apical and lateral to the defect. Coronal migration of cells originating from the periodontal ligament and bone marrow spaces is particularly critical to the healing outcome following periodontal regenerative procedures in furcation defects. Here, the role of the bone graft is space-making and also inducing bone formation. Space maintenance involves the creation of space for periodontal tissues to grow into. To increase the predictability and clinical success of regenerative therapy, factors related to the patient, furcation, surgical treatment, and the postoperative period must be considered. Each patient has a different healing potential that can directly influence the response to treatment. The patient-related factors that have a negative influence on the regeneration of these lesions include smoking, stress, diabetes mellitus, acquired immunodeficiency syndrome, and other acute and debilitating diseases, as also the presence of multiple deep periodontal pockets. Periodontal regeneration is a technique-sensitive procedure requiring training and experience, even for a competent surgeon. A poor operative technique in membrane placement or surgical soft tissue management, and failure to adequately cover the membrane can cause gingival recession and consequently membrane exposure. Recession may create root sensitivity and can complicate plaque control, whereas, membrane exposure may lead to infection to the site and bone graft.^[10] However, in the above case,

use of the GTR membrane combined with a bone graft, resulted in successful healing after an 18-month follow-up period. The clinical and radiographic findings have been quite impressive, resulting in a significant reduction of probing depth and gain in the bone fill.

CONCLUSION

Although traditional nonsurgical periodontal therapy can be predictably used to arrest mild-to-moderate defects, it may be inadequate for the treatment of deep pockets or wide circumferential furcation defects. At present, multiple regenerative techniques are widely available, as used in the above-mentioned case. This suggests that class II mesial furcation defects in the maxillary molars can be successfully managed by combined treatment modalities like the use of the GTR membrane with bone graft.

REFERENCES

1. Meng HX. Periodontic-endodontic lesions. *Ann Periodontol* 1999;4:84-90.
2. Skoglund A, Persson G. A follow-up study of apicoectomized teeth with -up total loss of buccal bone plate. *Oral Surg Oral Med Oral Pathol* 1985;59:78-81.
3. Santana RB, de Mattos CM, Van Dyke T. Efficacy of combined regenerative treatments in human mandibular class II furcation defects. *J Periodontol* 2009;80:1756-64.
4. Gottlow J, Karring T. Maintenance of new attachment gained through guided tissue regeneration. *J Periodontol* 1992;19:315-7.
5. Novaes AB Jr, Novaes AB. Guided tissue regeneration versus hemisection in the treatment of furcation lesions. A clinical analysis. *Braz Dent J* 1992;3:99-102.
6. Zuolo ML, Ferreira MO, Gutmann JL. Prognosis in Periradicular surgery: A clinical prospective study. *Int Endod J* 2000;33:91-8.
7. Wang HL, Boyapati L. "PASS" principles for predictable bone regeneration. *Implant Dent* 2006;15:8-17.
8. Novaes AB Jr, Palioto DB, de Andrade PF, Marchesan JT. Regeneration of class II furcation defects: Determinants of increased success. *Braz Dent J* 2005;16:87-97.
9. Bowers GM, Schallhorn RG, McClain PK, Morrison GM, Morgan R, Reynolds MA. Factors influencing the outcome of regenerative therapy in mandibular class II furcations: Part I. *J Periodontol* 2003;74:1255-68.
10. Nowzari H, MacDonald ES, Flynn J, London RM, Morrison JL, Slots J. The dynamics of microbial colonization of barrier membranes for guided tissue regeneration. *J Periodontol* 1996;67:694-702.

How to cite this article: Verma PK, Srivastava R, Gautam A, Chaturvedi TP. Multiple regenerative techniques for class II furcation defect. *Eur J Gen Dent* 2012;1:90-3.

Source of Support: Nil, **Conflict of Interest:** None declared.