

# Spontaneous spinal epidural hematoma in a young individual associated with hypertension

Krishan K. Yadav, Sanjay Kumar, Saurabh K. Verma, Amit A. Wagh

Department of Neurosurgery, Command Hospital (Southern Command), Wanworie, Pune, Maharashtra, India

## ABSTRACT

Spontaneous spinal epidural hematoma (SSEH) is a rare cause of acute spinal cord compression. The exact etiology of this entity is not known, and it has been associated with blood dyscrasias, coagulopathy, infection, tumor, vascular malformations, and hypertension in the literature. Emergency surgical decompression is the treatment of choice, however, lately conservative management of SSEH has been advocated in the literature for a particular group of patients whose clinical profile shows early improvement of their neurological status. We report a case of SSEH in a 24-year-old male who had severe hypertension at the onset of the SSEH leading to quadriplegia, and he was managed conservatively. The patient's blood pressure (BP) normalized over the next few weeks as the patient recovered neurologically. This direct association of hypertension with SSEH has been reported only in a few case reports. The normalization of BP in this case is unexplainable.

**Key words:** Conservative, cord compression, epidural, hematoma, hypertension, spontaneous

## INTRODUCTION

Spontaneous spinal epidural hematoma (SSEH) is a very rare entity, and the first case was reported by Jackson.<sup>[1]</sup> The incidence has been estimated as 0.1 patients/100,000 individuals and represented <1% of all spinal space occupying lesions.<sup>[2]</sup> The usual clinical presentation of SSEH is sudden onset neck pain or back pain associated with para/quadruparesis or para/quadruplegia depending on the level of the lesion. This entity has been reported to be associated with blood dyscrasias, coagulopathy, anticoagulant treatment, infections, tumors, pregnancy vascular malformations, rheumatoid arthritis, Paget's disease, and rarely hypertension, however, no definite cause can be found in 40–50% of cases.<sup>[2-5]</sup> Although emergency surgical decompression is the recommended approach,<sup>[6,7]</sup> conservative management is advocated in the literature in few case reports if the patient has objective improvement in his neurological status early in the course of the disease.<sup>[6,8,9]</sup> We report our case which is unique in that the patient was detected to

have hypertension at the onset of the disease which normalized after the conservative management of the patient.

## CASE REPORT

A 24-year-old male was admitted to a peripheral hospital with a history of sudden onset neck pain, radicular pain right upper limb associated with paresthesia bilateral lower limb. Over the next 24–36 h, patient developed rapidly progressive weakness of all four limbs initially involving the bilateral lower limbs with urinary retention. There was no history of trauma or breathing difficulty. At the time of admission in the peripheral hospital, patient was detected to have blood pressure of 186/106 mm Hg. Neurological evaluation revealed quadriplegia with power Medical Research Council (MRC) 3/5 in both upper limbs and MRC 2/5 in bilateral lower limbs. There was diminished pin prick sensation below CV7 dermatome. Deep tendon jerks were sluggish, and plantars were mute bilaterally. Hematological data including platelet count, coagulation profile, and biochemical parameters were within normal limits. Urgent magnetic resonance imaging (MRI) of the cervical spine revealed a mass lesion predominantly in left posterolateral region extending from CV4 to CV6 which was isointense to cord on T1-weighted images [Figure 1a] and heterogeneously hyperintense to cord on T2-weighted images [Figure 1b] as seen on sagittal images. On T1- and T2-weighted axial images,

Access this article online	
Quick Response Code:	Website: www.ijns.in
	DOI: 10.4103/2277-9167.146837

**Address for correspondence:** Dr. Krishan K. Yadav,  
Department of Neurosurgery, Command Hospital (Southern Command), Wanworie, Pune - 411 040, Maharashtra, India.  
E-mail: kkrishanyadav@gmail.com

the mass was seen mainly on the left posterolateral aspect leading to cord compression [Figure 1c and d]. There was thinning of the cord at the level. However, there were no intensity changes in the cord [Figure 1a and b]. There was no postcontrast enhancement on gadolinium (Gd-DTPA) injection. The MRI was commensurate with the intensity changes of blood in the hyperacute stage.

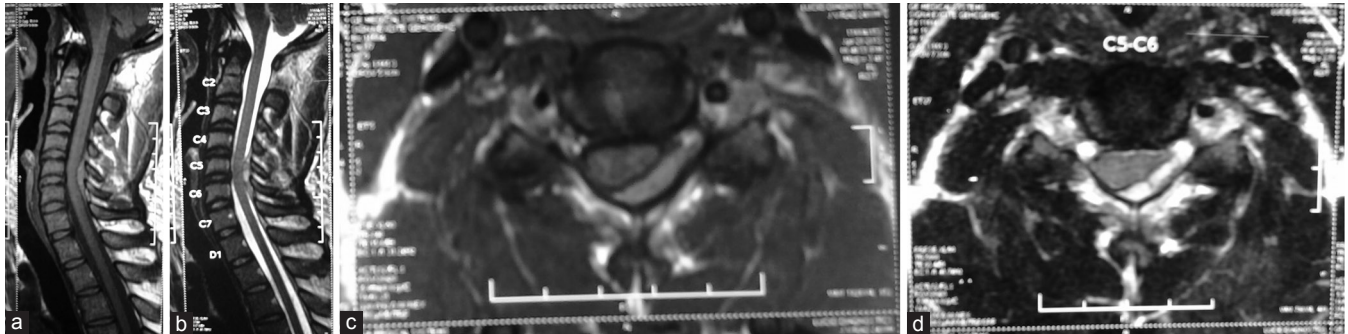
The patient was transferred to our center after 96 h after the onset of symptoms. On examination, patient had started improving neurologically as compared to his initial evaluation. The patient's blood pressure was managed initially with nitroglycerin infusion and subsequently with oral antihypertensive. Repeat MRI was done which revealed gradual regression of the mass lesion seen in the initial images. Since the patient was improving, conservative measures were continued. After 10 days, only mild sensory symptoms were present. Patient became ambulant over the next few weeks and sphincter control was restored. An MRI scan after 03 weeks was completely normal [Figure 2a-d].

Surprisingly, his BP readings also normalized and antihypertensive medication was tapered gradually and stopped after 4 weeks from the date of onset of the

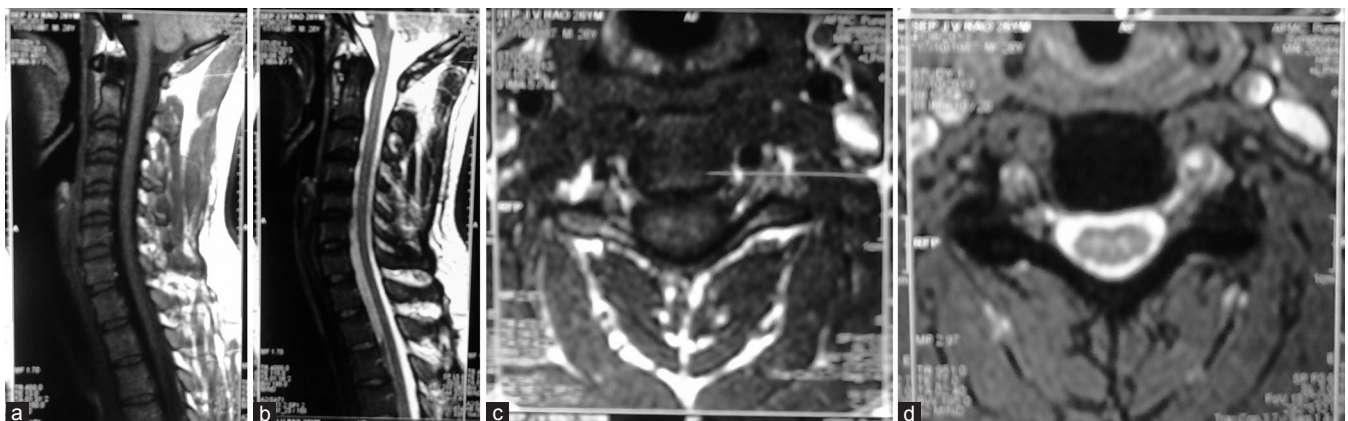illness for which no cause or explanation was found. At follow-up, after 09 months, the patient has remained symptom-free with no residual neurological deficits. Repeat MRI has shown no underlying abnormality.

## DISCUSSION

Spontaneous spinal subdural hematoma is a rare entity reported in the literature as a cause of acute spinal cord compression.<sup>[1,10]</sup> The yearly incidence is thought to be 0.1/100,000 persons,<sup>[2]</sup> but the true incidence is still not known.<sup>[10]</sup> This case of SSEH was the only case in 135 cases of spinal masses managed between 2006 and 2012 at our institution. The possible etiological factors which have been reported in the literature with SSEH are coagulation disorders seven anticoagulant therapy, arteriovenous malformations, vasculitis, minor trauma, pregnancy, cavernous angiomas, Paget's disease, weight lifting, and hypertension.<sup>[2,4,5,10,11]</sup> These factors may cause secondary spinal epidural hematoma with a clear cause (60%) or SSEH of unclear cause (40%).<sup>[4,12,13]</sup> Analysis of a large series of cases of SSEH that was reported in the literature suggested correlation between SSEH and coexistence of



**Figure 1:** Magnetic resonance images showing epidural hematoma at day 01 of the onset of symptoms. (a) T1-weighted sagittal image – isointense lesion opposite C5-6 vertebra showing relative thinning of the cord as indicated by the arrow. (b) T2-weighted sagittal image – heterogeneously hyperintense lesion and no intensity changes of the cord. (c) T1-weighted axial image – lesion located in left posterolateral region compressing the cord. (d) T2-weighted axial image showing the lesion in left posterolateral region



**Figure 2:** Magnetic resonance images after 3 weeks of onset of symptoms showing the complete resolution of the spinal hematoma with conservative management. (a) T1-weighted sagittal image. (b) T2-weighted sagittal image. (c) T1-weighted axial image. (d) T2-weighted axial image

arterial hypertension,<sup>[12]</sup> however, this correlation was again questioned in a recent publication.<sup>[11]</sup> But as reported in our case, the hypothesis of the association of arterial hypertension with SSEH seems to be true. SSEH tends to be more common in middle-aged or older patients, in males compared to females.<sup>[3]</sup> The majority of SSEH are situated in the CV5-DV2 area<sup>[12]</sup> and posteriorly or posterolaterally<sup>[11]</sup> as was the case in our patient.

The mechanism of development of SSEH is unclear. It has been suggested that venous pressure may increase in line with an increase in abdominal and intrathoracic pressure, since the spinal vein is of the primitive type with no venous valve, and that this may easily cause hemorrhage.<sup>[14,15]</sup> Alternatively, SSEH may develop due to the collapse of the free epidural artery following hemorrhage at a level that causes spinal cord compression, with acute onset and progress of symptoms.<sup>[13]</sup> Many reports have also suggested that SSEH may be triggered by actions that increase venous pressure, such as cough, sneezing, and holding of heavy baggage,<sup>[16]</sup> and venous hemorrhage has also been proposed as a cause.

Spontaneous spinal epidural hematoma present with history of sudden onset neck pain associated with radicular pain and varying degrees of neurological deficits ranging from monoparesis to quadriplegia with sphincter involvement and respiratory distress depending on the level of the epidural hematoma as reported in the literature.<sup>[8,9,11,13,14]</sup>

The diagnosis of SSEH is made on the basis of MRI findings which are chronologically similar to the appearance those seen with intracranial hemorrhage [Figure 1a-d].<sup>[2,4]</sup> Traditionally, the management of SSEH has been emergency laminectomy and evacuation of the hematoma as early as possible for good neurological recovery to occur. However, in the recent literature, cases have been mentioned which were managed conservatively with a favorable outcome. The decisions to manage these cases conservatively were probably taken based on the relatively lesser degree of neurological deficits and the patient's showing significant recovery very early in the course of the disease. However, the decision to manage our patient conservatively in spite of having significant neurological deficits was taken as he was shifted to our center after almost 96 h after the onset of the disease. The patient had shown signs of recovery with conservative measures (steroids and physiotherapy).

Patient had complete neurological recovery within 3 weeks and follow-up MRI after 3 weeks showed no residual lesion [Figure 2a-d].

Conservative treatment is currently indicated in uncommon situations or when neurological symptoms improve before medical evaluation, as was the case who presented to us with significant neurological recovery after 04 days of onset of symptoms.

Hence, we conclude that conservative management of SSEH is an option in the young patient who in spite of significant neurological deficits at the onset of symptoms shows early neurological recovery.

## REFERENCES

1. Jackson R. Case of spinal apoplexy. *Lancet* 1869;94:5-6.
2. Holtás S, Heiling M, Lönnroft M. Spontaneous spinal epidural hematoma: Findings at MR imaging and clinical correlation. *Radiology* 1996;199:409-13.
3. Bruyn GW, Bosma MJ. Spinal extradural hematoma. In: Vinken PJ, Bruyn GW, editors. *Handbook of Clinical Neurology*. Vol. 26. Amsterdam; 1976. p. 1-30.
4. Fukui MB, Swarnkar AS, Williams RL. Acute spontaneous spinal epidural hematomas. *AJNR Am J Neuroradiol* 1999;20:1365-72.
5. Chen CJ, Fang W, Chen CM, Wan YL. Spontaneous spinal epidural haematomas with repeated remission and relapse. *Neuroradiology* 1997;39:737-40.
6. Hentschel SJ, Woolfenden AR, Fairholm DJ. Resolution of spontaneous spinal epidural hematoma without surgery: Report of two cases. *Spine (Phila Pa 1976)* 2001;26:E525-7.
7. Kingery WS, Seibel M, Date ES, Marks MP. The natural resolution of a lumbar spontaneous epidural hematoma and associated radiculopathy. *Spine (Phila Pa 1976)* 1994;19:67-9.
8. Duffill J, Sparrow OC, Millar J, Barker CS. Can spontaneous spinal epidural haematoma be managed safely without operation? A report of four cases. *J Neurol Neurosurg Psychiatry* 2000;69:816-9.
9. Boukobza M, Guichard JP, Boissonet M, George B, Reizine D, Gelbert F, et al. Spinal epidural haematoma: Report of 11 cases and review of the literature. *Neuroradiology* 1994;36:456-9.
10. Chen HH, Hung CC. Spontaneous spinal epidural hematoma: Report of seven cases. *J Formos Med Assoc* 1992;91:214-8.
11. Groen RJ, Hoogland PV. High blood pressure and the spontaneous spinal epidural hematoma: The misconception about their correlation. *Eur J Emerg Med* 2008;15:119-20.
12. Groen RJ, Ponsen H. The spontaneous spinal epidural hematoma. A study of the etiology. *J Neurol Sci* 1990;98:121-38.
13. Beatty RM, Winston KR. Spontaneous cervical epidural hematoma. A consideration of etiology. *J Neurosurg* 1984;61:143-8.
14. Groen RJ. Non-operative treatment of spontaneous spinal epidural hematomas: A review of the literature and a comparison with operative cases. *Acta Neurochir (Wien)* 2004;146:103-10.
15. Lawton MT, Porter RW, Heiserman JE, Jacobowitz R, Sonntag VK, Dickman CA. Surgical management of spinal epidural hematoma: Relationship between surgical timing and neurological outcome. *J Neurosurg* 1995;83:1-7.
16. Kimiwa T, Takahashi T, Shimizu H. Clinical approach of idiopathic spinal epidural hematoma. *No Shinkei Geka (Japanese)* 2004;32:333-8.

**How to cite this article:** Yadav KK, Kumar S, Verma SK, Wagh AA. Spontaneous spinal epidural hematoma in a young individual associated with hypertension. *Indian J Neurosurg* 2014;3:171-3.

**Source of Support:** Nil, **Conflict of Interest:** None declared.