Intracranial extension of Marjolin's ulcer of the scalp with a latency of 3 years

Sir,

Squamous cell carcinoma (SCC) of Marjolin's ulcer, originating mostly in chronic scars and wounds of diverse origin, is locally and systemically more aggressive than other forms of SCC.[1] Direct intracranial invasion is rarely reported in literature[2] with average latency of 31 years.[3] We herein present a case of Marjolin's ulcer of the scalp in a 15-year-old male with intracranial extension in a latency of 3 years.

A 15-year-old male child, scald injury to scalp while 1 month old, presented to us with the complaints of throbbing headache, occasional vomiting, and two episodes of convulsions in last 3 months, and a slowly progressive painful, tense, tender, soft-tissue lump over the vertex for last 3 years [Figure 1a]. He had undergone debridement of ulcer with tissue expander, and series of local transposition flaps. Scrap cytology of the lump was suggestive of SCC of Marjolin's origin. Contrast enhanced computerized tomography revealed intracranial extension of extracranial soft-tissue mass with a filling defect in superior sagittal sinus (SSS) [Figure 1b]. Magnetic resonance imaging (MRI) revealed, contrast enhancing soft-tissue mass invading brain parenchyma intraaxially, and extraaxially [Figure 1c]. Magnetic resonance venogram (MRV) revealed thinned out SSS with collaterals [Figure 1d].

He underwent wide surgical excision with 2 cm tumor free margins at the skin, bone, dura, SSS, and partly the falx with scalp reconstruction by bipedicled rotational flap, and donor site split-thickness skin graft [Figure 2a]. Histopathology confirmed, an invasive moderately differentiated SCC without any vascular or perineural invasion [Figure 2b]. Post-operatively, his wound was healthy [Figure 2c] with near total tumor clearance on contrast MRI of the brain [Figure 2d].

Direct intracranial invasion occurs commonly through intraosseous, intradural spread, and rarely the involvement of SSS[2-7] with dura being the strong physiological barrier to prevent the deep local invasion.[6] Marjolin's ulcers occur at any age with male:female ratio 3:1.[8] The average age of onset is 58 years[9] with 18 years of age as the youngest case and 84 years[10] the oldest. The time lag varies from 4 weeks[11] to 68 years[12] with 31 years as the median.[3] The exact incidence and reasons of malignant transformation are unknown.[8,9] Risk factors include continuous irritation, healing by secondary intention, non-healing secondary to sepsis, fragile and easily traumatized tissue, ulcerated scars with obliterated lymphatics, and poor local and systemic immune resistance.[9,10] Identification of risk factors and a high index of suspicion is the key to early diagnosis.[8-10] Clinically, a change in sensation or appearance of the ulcer mandates histological assessment. With central nervous

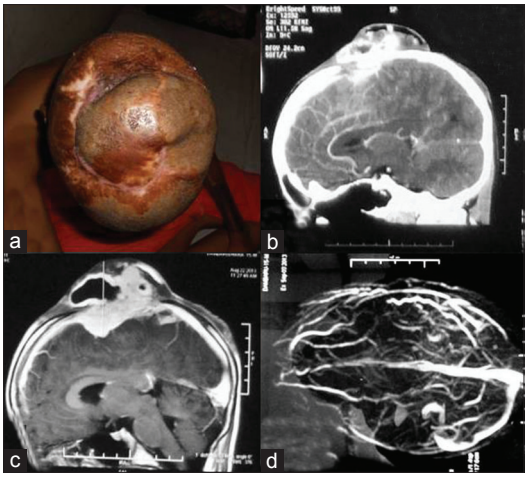

Figure 1: (a) Preoperative photograph of tense, boggy soft-tissue swelling occupying vertex of the scalp; (b) Contrast enhanced computerized tomography of brain revealing intracranial extension of soft-tissue scalp swelling with a filling defect in superior sagittal sinus (SSS); (c) Magnetic resonance imaging of brain revealing contrast enhancing soft-tissue mass invading brain parenchyma intraaxially, and extraaxially; (d) Magnetic resonance venogram showing thinned out SSS with collaterals

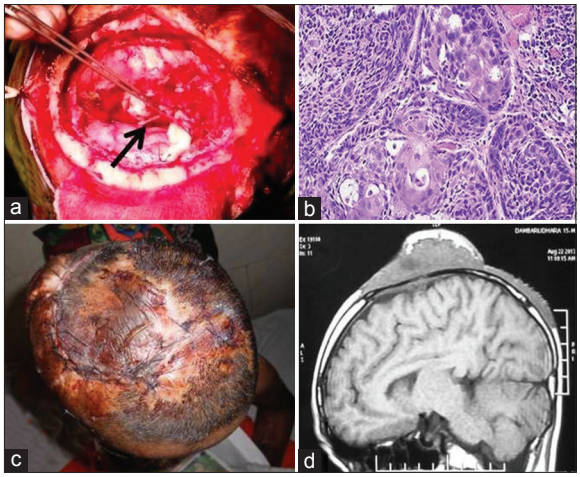

Figure 2: (a) Intraoperative photograph after wide local excision of cranial bone, dura, part of falx cerebri with thrombosed superior sagittal sinus (thick black arrow pointing), and involved brain parenchyma; (b) Histopathological features suggestive of moderately differentiated squamous cell carcinoma without vascular and perineural invasion; (c) Post-operative photograph of healthy scalp wound; (d) Post-operative magnetic resonance imaging revealed near total tumour clearance with post-op changes

This document was downloaded for personal use only. Unauthorized distribution is strictly prohibited.

system involvement, common findings are headache, papilledema, and vomiting secondary to raised intracranial pressure.[6]

Early, aggressive, and appropriate surgical management offers good outcome.[4,8,13] Treatment modalities include surgical excision,[8] radiotherapy and chemotherapy[3,9,10] of which mainstay of treatment is wide local excision with a 2 cm tumor free margin at skin, bone, dura, and other involved structures.[3,8,9,14] Radiotherapy and/or chemotherapy have varied response rates.[3] Recurrence ranges between 20-50%.[3,9]

Prognostic factors include histopathological features (degree of differentiation, thickness, depth of invasion, and perineural involvement), etiology, latency period, immune status of the patients, and the local extension.[6,8] Perineural invasion has a poor outcome.[6] No perineural invasion in our case seems to have a better outcome in the long run.

This report mandates early diagnosis, and aggressive, but early surgery to regain the best possible functional outcome for such a locally aggressive skin tumor of the scalp. MRI with MRV is a must before surgery. Wide surgical excision is the primary treatment, radiotherapy having an adjunctive role that has to be backed by careful oncological surveillance.

Sudhansu Sekhar Mishra, Mani Charan Satapathy, Prithiwiraj Singh[1], Satya Bhusan Senapati, Itibrata Mohanta

Departments of Neurosurgery and [1]Plastic Surgery, S.C.B. Medical College, Cuttack, Odisha, India.
E-mail: drmcsatapathy@gmail.com

REFERENCES

1. Poulsen M. Merkel-cell carcinoma of the skin. Lancet Oncol 2004;5:593-9.
2. Ahn JH, Abu-Serriah M, Ameerally P. Multiple synchronous cutaneous squamous cell carcinomas of the head and neck: A case report. J Oral Maxillofac Surg 2011;69:e317-23.
3. Mathes SJ. Tumors of head, neck and skin. Management of non melanoma skin cancer. Plastic Surgery. 2nd ed., Vol. 5. Saunders Elsevier: 2006. p. 437-9.
4. Lang PG Jr, Braun MA, Kwatra R. Aggressive squamous carcinomas of the scalp. Dermatol Surg 2006;32:1163-70.
5. Neubauer KE, Goldstein GD, Plumb SJ. Squamous cell carcinoma of the scalp in organ transplant recipients: Exploring mechanisms for recurrence and treatment guidelines. Dermatol Surg 2010;36:185-93.
6. Papadopoulos O, Frantzoglou M, Chrisostomidis C, Konofaos P, Frangoulis M, Barlas G. Neglected squamous cell carcinoma of the frontal area: A clinical report. J Craniofac Surg 2006;17:1015-20.
7. Selçuk G, Aysal BK, Ahmet E, Cihan S, Fatih U, Demircan MN. Intracranial extension of squamous cell carcinoma of the scalp: A case report. J Neurol Sci (Turkish) 2013;30:406-10.
8. Daya M, Balakrishan T. Advanced Marjolin's ulcer of the scalp in a 13-year-old boy treated by excision and free tissue transfer: Case report and review of literature. Indian J Plast Surg 2009;42:106-11.
9. Er-Fan X, Li AO, Shi-ling W, Shao-Yu K, Guang-Xiu C. Burn scar carcinoma: Case reports and review of the literature. Ann MBC 1992;5:2.
10. Guenther N, Menenakos C, Braumann C, Buettemeyer R. Squamous cell carcinoma arising on a skin graft 64 years after primary injury. Dermatol Online J 2007;13:27.
11. Celiköz B, Demiriz M, Selmanpakoğlu N. A shorter lag period of mesenchymal malignancy on Marjolin's ulcer. Burns 1997;23:72-4.
12. Thio D, Clarkson JH, Misra A, Srivastava S. Malignant change after 18 months in a lower limb ulcer: Acute Marjolin's revisited. Br J Plast Surg 2003;56:825-8.
13. Soma PF, Chibbaro S, Makiese O, Marsella M, Diemidio P, Fricia M, *et al*. Aggressive scalp carcinoma with intracranial extension: A multidisciplinary experience of 25 patients with long-term follow-up. J Clin Neurosci 2008;15:988-92.
14. Hahn SB, Kim DJ, Jeon CH. Clinical study of Marjolin's ulcer. Yonsei Med J 1990;31:234-41.

Access this article online

Quick Response Code:	Website: www.ijns.in
	DOI: 10.4103/2277-9167.132016

This document was downloaded for personal use only. Unauthorized distribution is strictly prohibited.