Cerebral hydatid disease: Is it primary or secondary?

Onteddu Joji Reddy, Jamkhana Abdul Gafoor, Balla Suresh, Polysetty Obuleswar Prasad
Department of Radiodiagnosis, Government General Hospital, Budhawarpet, Kurnool, Andhra Pradesh, India

ABSTRACT

Hydatid disease is a serious medical problem in Mediterranean and particularly among sheep farming countries, caused by larval stages of dog tapeworms belonging to the genus *Echinococcus*. Hydatid cysts may affect every organ in the human body; however, multiple organ involvement (spleen, adrenal gland, heart, pericardium, intravascular growth of hydatids and brain) without affecting the two major filters in the body liver and the lung was very rare. In this case, myocardial hydatid cyst is considered as primary and involvement of other organs such as brain, spleen, adrenal glands, and vascular involvement are considered as secondary involvement due to the rupture of hydatid in heart. Rarity of this atypical presentation of hydatid disease leads to this case report.

Key words: *Echinococcus*, intracranial, myocardial hydatid cyst

INTRODUCTION

Hydatid disease is caused by the infestation of the larvae of *Echinococcus*. The definite hosts of *Echinococcus* are various carnivores, the common being the dog. Humans get infected through the faeco-oral route by ingestion of food or milk contaminated by dog faeces containing ova of the parasite or by direct contact with dogs. These larvae enter portal circulation from intestines and are trapped in capillaries of liver and lung and these are most commonly involved organs in the body. Some may pass through the capillary filter of the liver and lungs and get entry into the systemic circulation. In India, hydatid disease is highly endemic in the Kurnool district of Andhra Pradesh, Madurai District of Tamil Nadu and in Punjab.[1] Various series of intracranial hydatids from India have reported its incidence as 0.2% of all intracranial space occupying lesions.[2]

CASE REPORT

A 35-year-old female patient came with the chief complaints of headache, vomiting, altered sensorium since 1 week and loss of consciousness since 2 days. Emergency chest X-ray, ultrasound abdomen, and contrast enhanced computed tomography of the brain were done. The chest X-ray showed minimal bronchiectasis in left lower zone of the lung, ultrasound of the abdomen showed multiple unilocular large cystic lesions were present in spleen. Contrast enhanced computed tomography of the brain showed well-defined large unilocular cystic lesions without surrounding edema and contrast enhancement. These cystic lesions were supratentorial, intraaxial noted in parietal periventricular white matter of both cerebral hemispheres with mass effect on lateral ventricles [Figure 1 a-c] causing mild midline shift to right. With these imaging findings, we suspect hydatid disease involving the brain and spleen. Emergency bilateral parietal craniotomy was done and the five cystic lesions were excised without rupture [Figure 2a and b] and send for histopathological examination. Patient recovered from unconsciousness and postoperative course was uneventful. Histopathology confirmed these cystic lesions were hydatid cysts without brood capsules and scolex. Usually, hydatid disease of brain present as solitary unilocular cystic lesion involving only one cerebral hemisphere. This unusual bilateral involvement of both cerebral hemispheres with multiple cysts made us to suspect a local source discharging the larvae into the circulation causing atypical involvement of the brain. Two-dimensional cardiac echo was done, which showed a cystic lesion attached to the interventricular septum which was freely communicating with the left ventricular lumen [Figure 3a and b]. With these imaging findings, we thought myocardial hydatid cyst was primary and involvement of other organs like the spleen and brain were considered secondary due to rupture of this cyst causing widespread dissemination of larvae.

Access this article online	
Quick Response Code:	Website: www.ijns.in
	DOI: 10.4103/2277-9167.132004

Address for correspondence: Dr. Onteddu Joji Reddy,
Department of Radiodiagnosis, Government General Hospital, Budhawarpet, Kurnool, Andhra Pradesh, India. E-mail: onteddoo@yahoo.co.in

This document was downloaded for personal use only. Unauthorized distribution is strictly prohibited.

Contrast enhanced computed tomography abdomen was done to look for other organ involvement which showed cystic lesions in pericardium, spleen, left adrenal gland. Right common iliac and external iliac arteries were filled with cystic lesions causing complete occlusion of these arteries [Figure 4a and b]. Angiogram of the aorta and iliac arteries showed complete blockage of the right common iliac and external iliac arteries [Figure 4c]. Refilling of the proximal superficial femoral arteries was present due to the formation of collateral vessels. Patient was referred to higher centers for surgical management of intravascular cystic lesions.

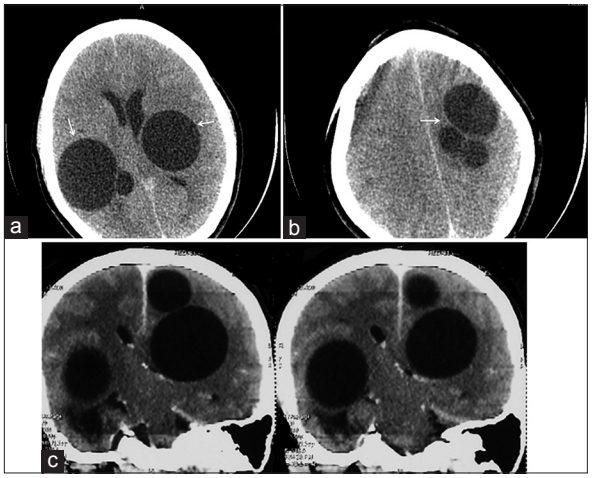

Figure 1: (a) Contrast enhanced computed tomography of brain axial section at the level of ventricles showing multiple cystic lesions in the parietal region in both cerebral hemispheres without edema and with midline shift to right (b) Contrast enhanced computed tomography of brain axial section above the level of ventricles showing multiple cystic lesions in the left parietal region without edema and with midline shift to right (c) Contrast enhanced computed tomography of brain coronal sections showing multiple cystic lesions in the parietal region in both cerebral hemispheres without edema and with midline shift to right

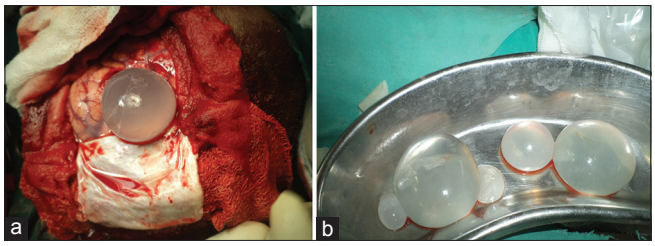

Figure 2: (a) Intra operative image showing cystic lesion in the brain after elevating dural flap, (b) Specimen showing five cystic lesions, which were excised without rupture of cysts

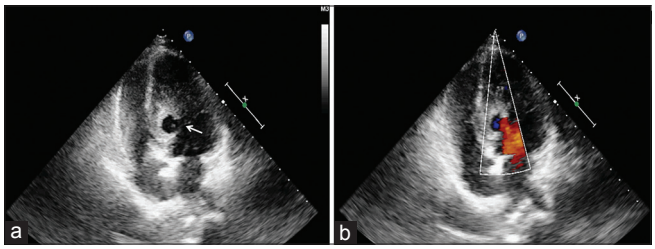

Figure 3: (a and b) Two-dimensional cardiac echo showing cystic lesion in the interventricular septum (white arrow), which was freely communicating with the left ventricular lumen

DISCUSSION

Intracranial hydatid disease is rare, with reported incidence of 1-2% of all cases with hydatid disease.[3] Cerebral hydatid disease is more common in pediatric population.[4] Hydatid cysts of the brain are usually single, spherical, unilocular, and may be large; in rare instances, they can be multiple and embolic. Although an intracranial single lesion is nearly always primary, multiple lesions are frequently secondary. Multiple hydatid cysts resulting from the rupture of a primary cyst are acephaloceles; they are infertile and have no broad capsule. However, very rarely a multiple larval intake may cause primary multiple cerebral hydatid cysts.

In the majority of cerebral hydatid cases, the brain is involved directly by larvae forming a primary cyst which is usually solitary and located in the supratentorial region in the parietal lobe.[5] Less commonly, the brain is affected by multiple cysts which develop either from spontaneous, traumatic or surgical rupture of a primary solitary cyst or from rupture of an extracranial hydatid cyst which embolizes to the brain.[6] The association between cerebral and cardiac hydatid disease has been reported previously.[5] Under rare circumstances, multiple cerebral hydatid cysts may develop secondary to embolization as a sequelae to rupture of an intracardiac hydatid disease.[7,8]

Cardiac echinococcosis is a rare disease with incidence of 0.02-2%.The left ventricle is the most common area affected with incidence of 55-60%, followed by the right ventricle, interventricular septum, left atrium, right atrium and inter atrial septum.[9] The larvae of ecchinococcus granulosus reaches the heart through coronary circulation or pulmonary veins. Contractions of the heart provide a natural resistance to the growth of hydatid causing early rupture of cysts.[10] In 50% of cardiac hydatid cases, there is multiple organ involvement due to rupture of the cyst discharging cyst contents into blood stream.[11] In our patient, myocardial hydatid cyst is considered as primary and involvement of other organs such as brain, spleen, and adrenal glands are considered as secondary involvement due to the rupture of hydatid in the heart causing disseminated disease.

Intravascular growth of hydatid cysts was very rare and only few cases are reported in the literature. This may be due embolism of hydatid cyst contents at the time of rupture of hydatid cyst in the heart.[12] The larvae are lodged at major vessel bifurcations and can form hydatid

This document was downloaded for personal use only. Unauthorized distribution is strictly prohibited.

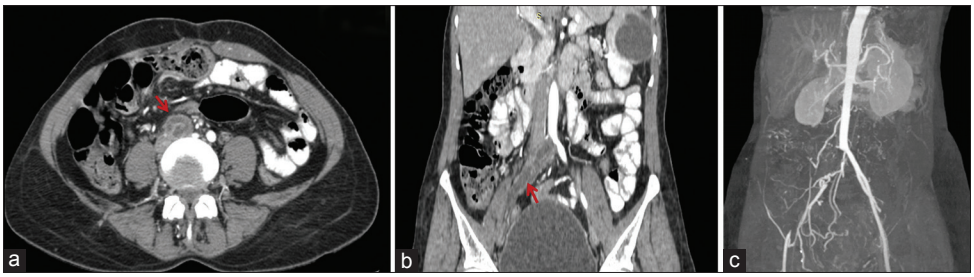

Figure 4 : (a) Contrast enhanced computed tomography of abdomen showing right common iliac artery (red arrow) is filled with multiple cystic lesions with the absence of blood flow, (b) Coronal sections of contrast enhanced computed tomography of abdomen showing right common iliac artery (red arrow) from the bifurcation of aorta is filled with multiple cysts, (c) Computed tomography maximum intensity projection image showing complete blockage of right common iliac artery from the bifurcation of the aorta. Superficial femoral artery is supplied by multiple collateral vessels

cysts which grow slowly causing gradual narrowing of lumen of major arteries. Embolism of hydatid cysts can occur affecting the peripheral arteries causing acute ischemic symptoms which are a surgical emergency.

In this case, due to bilateral involvement of both cerebral hemispheres with multiple hydatid cysts which are acephaloceles, these are considerd as secondary hydatid cysts due to rupture of hydatid cyst in the heart which is considered as primary, causing widespread dissemination. In our patient, most commonly involved organs liver and lung are not affected which is a rare presentation. Intravascular growth of hydatid cysts in right common iliac and external iliac arteries causing complete occlusion of both arteries is a very rare presentation.

CONCLUSION

We concluded that involvement of brain with multiple hydatid cysts should indicate vascular spread from another primary source not necessarily from heart. The diagnosis of multiple bilateral cerebral hydatid cysts should alert physicians about the probability of cardiac involvement of hydatid cyst.

ACKNOWLEDGMENTS

The authors are grateful to Dr. M. Ramanjaneyulu (Associate Professor, Department of Neurosurgery), Dr. M. Lakshmi Ananth (Assistant Professor, Department of Neurosurgery), Dr. Nagaraju (Assistant Professor, Department of Neurosurgery), Dr. P. Chandrashekhar (Associate Professor, Department of Cardiology), Dr. J. Sireesha and Dr. M. Rajanikanth (Tutors, Department of Radiodiagnosis) at Kurnool Medical College, Kurnool.

REFERENCES

1. Dharker SR. Hydatid disease. In: Ramamurthi B, Tandon PN, editors. Text Book of Neurosurgery. 2nd ed. New Delhi: Churchill Livingstone; 1996. p. 535-44.
2. Gupta S, Desai K, Goel A. Neurol India 1999:47:214-7.
3. Erşahin Y, Mutluer S, Güzelbağ E. Intracranial hydatid cysts in children. Neurosurgery 1993;33:219-24.
4. Jiménez-Mejías ME, Castillo-Ojeda E, Cuello Contreras JA, García Gutiérrez D, Romero Arce J, Pachón Díaz J. Cerebral hydatidosis. Analysis of a series of 23 cases. Med Clin (Barc) 1991;97:125-32.
5. Pillai AK, Pillai MV, Vohra S, Oommen EB. Multiple central nervous system hydatidosis secondary to cardiac echinococcosis. Neuroradiology 2004;14 (1):81-83.
6. Cavuşoğlu H, Tuncer C, Ozdilmaç A, Aydin Y. Multiple intracranial hydatid cysts in a boy. Turk Neurosurg 2009;19:203-7.
7. Turgut M, Bayülkem K. Cerebrovascular occlusive disease: Hydatidosis. Childs Nerv Syst 1998;14:697-9.
8. Iraj L, Payman V, Shahram H, Hassan D. Multiple cerebral hydatid cysts secondary to embolization from intracardiac hydatidosis. Neurosurg Q 2007;17:134-7.
9. Darwazah AK, Zaghari M, Eida M, Batrawy M. Left ventricular endocardial ecchinococcosis associated with multiple intracranial hydatid cysts. J Cardiothorac Surg 2013;8:104.
10. Kabbani SS, Jokhadar M, Sundouk A, Nabhani F, Baba B, Shafik AI. Surgical management of cardiac echinococcosis. Report of four cases. J Cardiovasc Surg (Torino) 1992;33:505-10.
11. Bayezid O, Ocal A, Işik O, Okay T, Yakut C. A case of cardiac hydatid cyst localized on the interventricular septum and causing pulmonary emboli. J Cardiovasc Surg (Torino) 1991;32:324-6.
12. Beshlyaga VM, Demyanchuk VB, Glagola MD, Lazorishinets VV. *Echinococcus* cyst of the left ventricle in 10-year-old patient. Eur J Cardiothorac Surg 2002;21:87.

How to cite this article: Reddy OJ, Gafoor JA, Suresh B, Prasad PO. Cerebral hydatid disease: Is it primary or secondary?. Indian J Neurosurg 2014;3:41-3.
Source of Support: Nil, **Conflict of Interest:** None declared.

This document was downloaded for personal use only. Unauthorized distribution is strictly prohibited.