

Occipital intradiploic epidermoid presenting as benign intracranial hypertension: A rare manifestation

Sir,

Intradiploic epidermoids are rare benign tumors, and they commonly present as slow growing, painless lumps in the scalp. Lesions that lead to neurological

deficits are consequently either of considerable size or demonstrate significant intracranial extension. Rarely, it can cause intracranial hypertension due to partial or complete obstruction of major venous system of the brain.^[1]

A 28-year old male presented with the complaint of transient blurring of vision for the last 1 month. On examination, there was no visible swelling over scalp. His visual acuity was 6/6 with normal field of vision in both eyes. However, bilateral papilledema was present. A computerized tomography (CT) scan of head (plain) was carried out, which showed a small well defined oval intradiploic hypodense midline lesion causing expansion of diploic space and lytic defect of both tables of occipital bone. There was no hydrocephalus or midline shift [Figure 1]. Magnetic resonance imaging (MRI) of the brain showed the mass, which was T1 hypointense, T2 hyperintense, fluid attenuation inversion recovery (FLAIR) heterogeneous signal and showed marked restriction of diffusion on diffusion weighted imaging and apparent diffusion coefficient. There was no evidence of fat, hemorrhage, calcification or post contrast enhancement in the mass. Contrast magnetic resonance venogram (MRV) showed compression of torcular herophili, mainly terminal part of the superior sagittal sinus and proximal part of bilateral transverse sinus by the mass, with no venous thrombosis [Figure 1]. A diagnosis of midline intradiploic occipital epidermoid over the torcula with benign intracranial hypertension was made and the patient was operated.

Intra-operatively, a thinned shell-like outer table of occipital bone with pearly white mass at the centre was seen, which was excised completely along with the capsule after doing craniectomy [Figure 2a]. Histopathological examination of mass confirmed that

is was an epidermoid [Figure 2b]. After 1 month of follow-up, the patient had complete resolution of visual symptoms and papilledema.

Epidermoid cysts result from inclusion of ectodermal tissue at the time of neural groove closure. They constitute less than 1% of intracranial tumors and commonly seen in middle aged males.^[2] 90% of cranial epidermoids are intradural and 10% are extradural, mostly intradiploic.^[3] Epidermoids usually are hypodense in plain CT scan, uncommonly hyperdense (due to hemorrhage/high protein content/patchy calcification) and shows no post contrast enhancement.^[4] An epidermoid is usually hypo to isointense on T1-weighted images and slightly hyperintense and heterogeneous on T2-weighted and T2 FLAIR images with no enhancement unless it gets infected.^[5] Most common radiological differentials are intradiploic dermoid and arachnoid cyst. Dermoids are commonly seen close to the suture lines containing dermal elements such as hair, fat and calcification unlike epidermoids which contain keratin, cellular debris and cholesterol.^[6] FLAIR sequences and diffusion-weighted images differentiate epidermoid cysts from arachnoid cyst as former appears hyperintense relative to cerebro spinal fluid (CSF) and shows restriction of diffusion.^[7] Surgical excision of intradiploic epidermoid is indicated when it is of large size causing neurological deficit or cosmetic deformity. Total removal of epidermoid along with its capsule prevents recurrence.^[8]

In the present case, transient blurring of vision was due to papilledema, the cause of which was explained

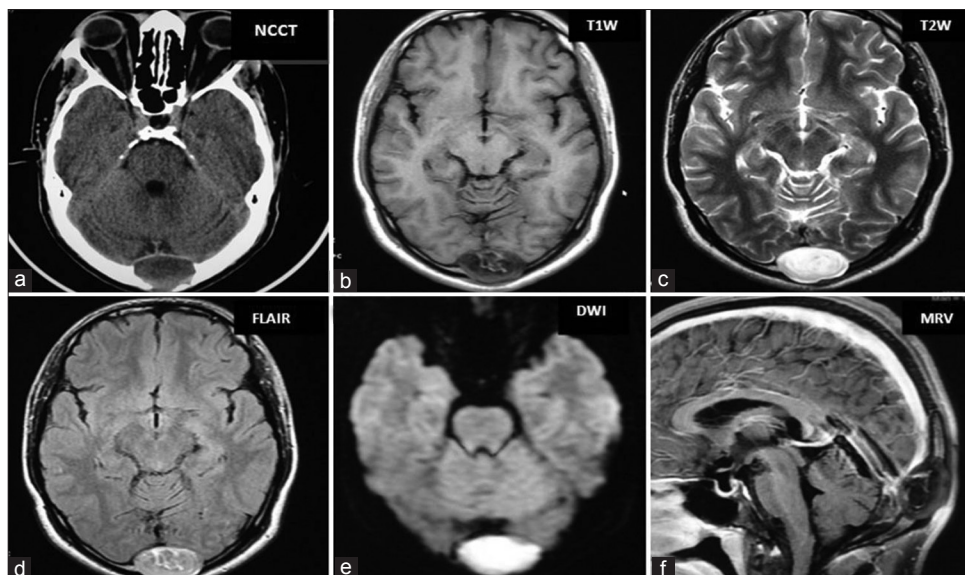


Figure 1: Computerized tomography of head (plain) showing a well-defined midline occipital intradiploic hypodense mass causing expansion of diploic space and lytic defect of both tables of occipital bone; Magnetic resonance imaging brain showing an oval lesion in the occipital intradiploic space in midline which is Hypointense on T1W, Hyperintense in T2W, heterogeneous signal in FLAIR, restricted diffusion in diffusion weighted imaging (DWI), non-enhancement of the lesion and compression of torcula herophili on post-contrast magnetic resonance venogram (MRV)

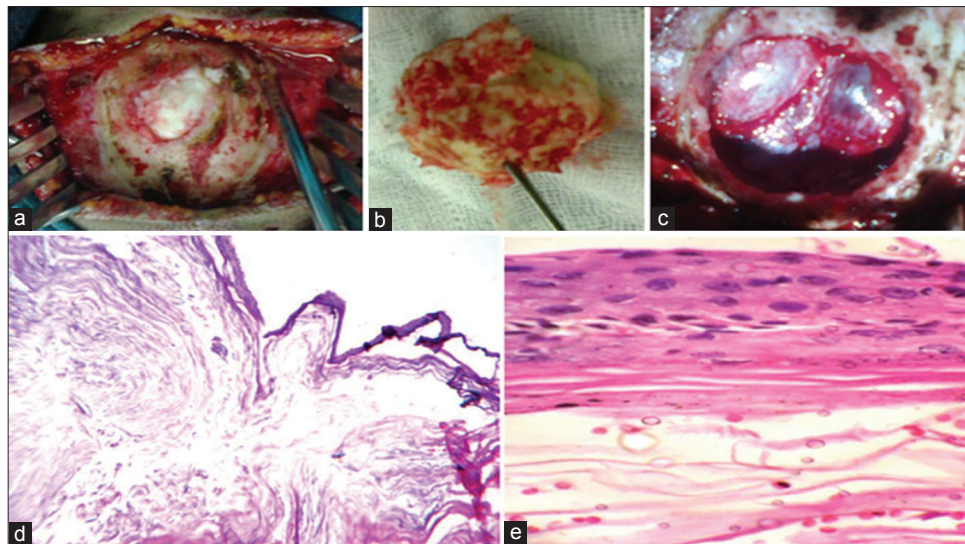


Figure 2: (a, b and c) Intra-operative pictures showing thinned shell-like outer table of occipital bone with pearly white tumor at the centre, pearly white mass resected with intact capsule and craniectomy defect with underlying torcula; (d and e) Microphotograph (low and high power view) showed squamous epithelial lining with keratin content inside suggestive of epidermoid

by the compression of torcular herophili by the midline intradiploic occipital epidermoid as evident on contrast MR venogram. Post-operative follow-up showed disappearance of symptoms and papilledema after 1 month. Our finding resembles other case reports by Djindjian *et al.*,^[9] Lam *et al.*,^[10] Gabriel Yin Foo Lee *et al.*,^[11] and Davis *et al.*^[12] Our case is probably the fourth case of occipital intradiploic epidermoid over torcula presenting purely as BIH.

In summary occipital, intradiploic epidermoid can rarely present as BIH due to compression of torcular herophili. CT scan and/or MRI study are essential diagnostic tools for the characterization and extension of the lesion. Total excision of the epidermoid along with the capsule results in excellent clinical outcome.

Ranjan Kumar Sahoo, Pradipta Tripathy¹,
Satya Sunder Gajendra Mohapatra,
Debahuti Mohapatra², Madan Mohan Mohapatra³

Departments of Radiology, ¹Neurosurgery, ²Pathology and ³Ophthalmology, Institute of Medical Science and SUM Hospital, Kalinga Nagar, Ghatikia, Bhubaneswar, Odisha, India.
E-mail: pradipta_tripathy@yahoo.com

REFERENCES

1. Rengachary S, Kishore PR, Watanabe I. Intradiploic epidermoid cyst of the occipital bone with torcular obstruction. Case report. J Neurosurg 1978;48:475-8
2. Ciappetta P, Artico M, Salvati M, Raco A, Gagliardi FM. Intradiploic epidermoid cysts of the skull: Report of 10 cases and review of the

- literature. Acta Neurochir (Wein) 1990;102:33-7.
3. Anne G. Osborn: Diagnostic Neuroradiology. 3rd ed. [ISBN]: Indian Reprint; 2008. p. 632.
4. Guiard JM, Kien P, Colombani S, Caillé JM. Intradiploic epidermoides cysts in adults. CT Contribution to diagnosis in 6 new cases. J Neuroradiol 1986;13:22-31.
5. Kallmes DF, Provenzale JM, Cloft HJ, McClendon RE. Typical and atypical MR imaging features on intracranial epidermoid tumors. AJR Am J Roentgenol 1997;169:883-7.
6. Narlawar RS, Nagar A, Hira P, Raut AA. Intradiploic epidermoid cyst. J Postgrad Med 2002;48:213-4.
7. Chen S, Ikawa F, Kurisu K, Arita K, Takaba J, Kanou Y. Quantitative MR evaluation of intracranial epidermoid tumors by fast fluid-attenuated inversion recovery imaging and echo-planar diffusion-weighted imaging. AJNR Am J Neuroradiol 2001;22:1089-96.
8. Khan AN, Khalid S, Enam SA. Intradiploic epidermal cyst overlying the torcula: A surgical challenge. BMJ Case Rep 2011;2011:1-4
9. Djindjian M, Keravel Y, Lepresle E, Caron JP, Ruel M, Gaston A. Occipital intraosseous epidermoid cyst producing a clinical picture simulating benign intracranial hypertension. A clinical case. Neurochirurgie 1987;33:395-8.
10. Lam CH, Solomon RK, Clark HB, Casey SO. Reversal of increased intracranial pressure with removal of a torcular epidermoid: Case report. Neurosurgery 2001;48:929-32.
11. Lee GY, Seex K, Scott G. Pseudotumour cerebri due to a torcular epidermoid cyst: ANZ J Surg 2001;71:385-8.
12. Davis G. Pseudotumour cerebri due to a Torcular epidermoid cyst. ANZ Journal of Surgery 2002;72:608.

Access this article online

Quick Response Code:



Website:
www.ijns.in

DOI:
10.4103/2277-9167.124246