Primary neuroendocrine carcinoma of brain radiologically mimicking high grade glioma: A case report and review of literature

Satya S. G. Mohapatra, Pradipta Tripathy[1], Ranjan K. Sahoo, Debahuti Mohapatra[2]
Departments of Radiology, [1]Neurosurgery, and [2]Pathology, Institute of Medical Science and SUM Hospital, Bhubaneswar, Odisha, India

ABSTRACT

Primary neuro-endocrine carcinoma (NEC) of central nervous system is extremely rare; only one case is reported till date. It mainly involves the dura, frontal lobe and paranasal sinus close to anterior skull base. We report a case of intrinsic brain tumor in left frontal lobe with extension to corpus callosum whose pre-operative MRI diagnosis was high grade glioma. He was operated, intra operative squash and post operative histopathological diagnosis of the tumor came as high grade glioma. However, on immunohistochemical (IHC) study the diagnosis turned out to be primary neuro endocrine carcinoma of brain.

Key words: Brain, high grade glioma, immunohistochemistry, neuro endocrine carcinoma, primary

INTRODUCTION

Neuro endocrine tumors (NET) originate from combination of nerve cell and endocrine cells. They are of two types, low or high grade. The low grade tumors include carcinoid tumor, insulinoma and pheochromocytoma while the high grade types are merckel cell carcinoma, small and large cell neuroendocrine carcinoma (NEC).[1] Depending on hormonal activity, NEC is further subdivided into functional or non-functional type. Non-functional NEC are rare tumors, occurring primarily in lung, gastro intestinal tract (GIT) or in breast. Brain is an extremely rare location to be involved primarily by NEC. Only one case of NEC in anterior skull base is reported until date.[2] However few cases of brain metastasis from primary NEC of lung and urinary bladder have been reported in the literature.[3,4] Owing to its rarity, location and high mitotic activity these tumors are very often mis-diagnosed as high grade glioma radiologically. Even, histologically it may be difficult to to diagnose and differentiate it from glioma. Immunohistochemical (IHC) test is the gold standard to establish a final diagnosis of primary neuro endocrine carcinoma of brain. We report this rare case of primary NEC of brain in a young adult, the diagnosis of which was confirmed only on IHC study. We have also reviewed the available literature on this rare condition.

Access this article online	
Quick Response Code:	Website: www.ijns.in
	DOI: 10.4103/2277-9167.124239

CASE REPORT

The present case report is about a 24 years old male patient who was admitted to neurosurgery ward with the complaint of generalized seizure for 2 months, headache and repeated vomiting for 1 month. His general physical examination was normal. On neurological examination, he was conscious but confused with the right side hemiparesis; Gr-4/5 power both in upper and lower limb, right side plantar was extensor. His routine tests were normal, chest X-ray and ultrasound abdomen were normal. The magnetic resonance imaging (MRI) study of brain revealed a diffuse lesion in left frontal lobe with medio-inferior extension involving the genu of corpus callosum going to opposite side with extensive brain edema. The lesion was hypointense in T1-weighted image [Figure 1a], hyperintense in T2-weighted image [Figure 1b] and non-enhancing except a ring enhancing nodule close to anterior skull base dura of left side on contrast study [Figure 1c]. On magnetic resonance (MR) spectroscopy, high choline peak was found which suggested a highly proliferative lesion [Figure 1d]. The radiological diagnosis was high grade glioma of corpus callosum. The patient was operated, left frontal craniotomy and tumor decompression was done.

Address for correspondence: Dr. Pradipta Tripathy,
Department of Neurosurgery, Institute of Medical Science and SUM Hospital, Sector 8, Kalinga Nagar, Ghatikia, Bhubaneswar - 751 003, Odisha, India. E-mail: pradipta_tripathy@yahoo.com

This document was downloaded for personal use only. Unauthorized distribution is strictly prohibited.

Tumor was soft in consistency. The cytology showed highly cellular smears comprising of round to ovoid, pleomorphic cells with high nuclear cytoplasmic (N:C) ratio and bizarre tumor giant cells. The background showed necrosis [Figure 2a and b]. Frozen report was consistent with high grade glioma.

The gross specimen received for histology was of multiple grayish brown tumor tissue of 1.5 cm × 1.5 cm size. The microscopic picture showed an infiltrating tumor comprising of moderately pleomorphic round to spindle shaped cells with high N:C ratio, increased mitotic figure arranged in perivascular and papillaroid pattern with intervening necrotic areas. However no true or pseudo rosettes were seen [Figure 2c and d]. The histopathological diagnosis was glioblastoma multiforme. The IHC study was done which was strongly positive for neuron specific enolase (NSE), typical punctate perinuclear cyto keratin (CK), grimellius stain and synaptophysin, negative for glial fibrillar acidic protein (GFAP) and vimentin [Figure 3]. Thus, the final diagnosis of primary NEC of brain was made. Subsequently, patient was subjected for radiotherapy. Post radiotherapy contrast computed tomography (CT) head showed no residual mass or recurrence [Figure 4]. On 6 months follow-up, patient was symptom free and neurologically intact.

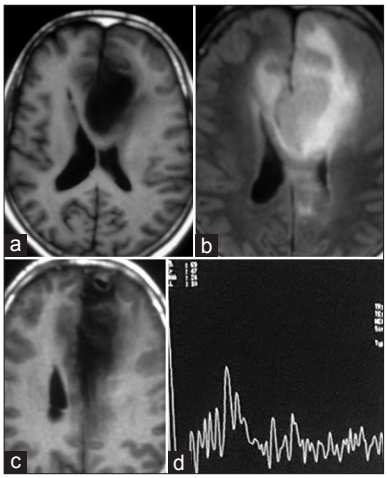

Figure 1: Magnetic resonance imaging brain showing a mass in left frontal lobe extending from anterior pole upto medial frontal lobe involving the genu of corpus callosum going to opposite side with odema which is, (a) Hypointense in T1-weighted image, (b) Hyperintense in T2-weighted image, (c) A ring enhancing nodule at the left frontal pole on contrast study and (d) High choline peak on magnetic resonance Spectroscopy

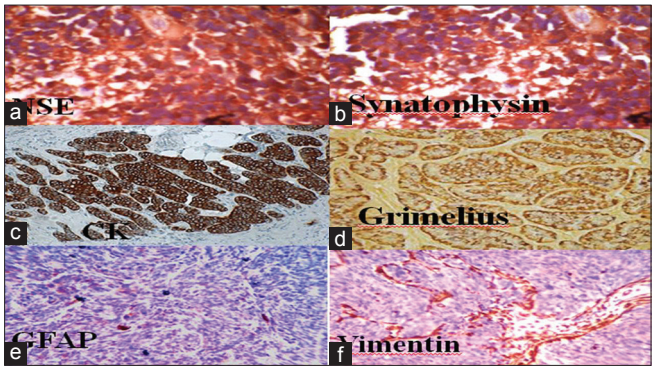

Figure 3: Immune histochemical markers of the neoplastic cells showed strong positivity for neuron specific enolase (a) and Synaptophysin (b), Cytokeratin (c), Grimelius stain (d) and negativity for glial fibrillary acidic protein (e) and Vimentin (f)

DISCUSSION

NEC are uncommon entity first coined by Toker in 1972 under the name of trabecular carcinoma of skin.[2] The primary site include skin, lung, breast and GIT.[1] Anterior skull base is an extremely rare primary site of NEC, which reflects a disorder of embryonal migration of merkel cell precursor along their pathway.[5] Another school of thought is that they originate from nasal crest of basal cells of olfactory epithelium.[3] The other theory put forward was that they originate from glandular epithelium of exocrine gland of nasal olfactory mucosa.[6]

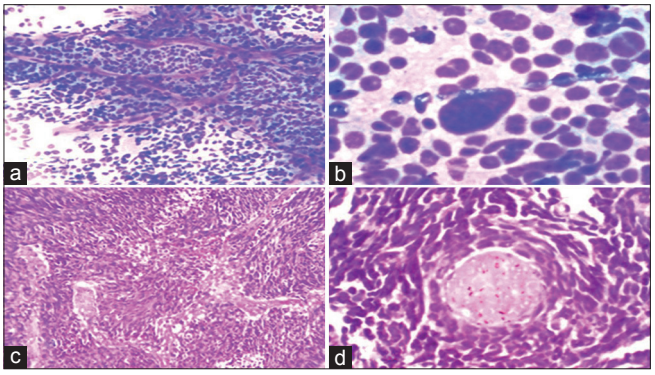

Figure 2: Sqush cytosmears (a) MGG ×100 view showed round to ovoid pleomorphic cells with high N:C ratio arranged in sheets and high power (b) MGG ×400 many bizarre tumor giant cells also seen. Microphotograph in low power (c) (H and E, ×100) showed round to spindloid shaped cells with high N:C ratio arranged in papillaroid pattern and high power (d) (H and E, ×400) showed perivascular arrangement of neoplastic cells

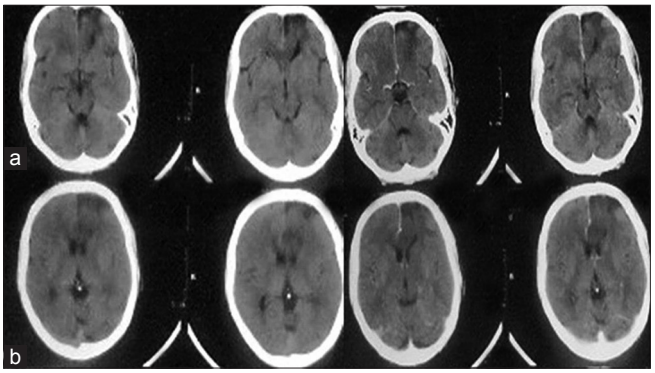

Figure 4: Follow-up computed tomography Scan of head after completion of radiotherapy (a) Plain and (b) Contrast study showed no residual tumor or recurrence

This document was downloaded for personal use only. Unauthorized distribution is strictly prohibited.

The predisposing factors for NEC include alcoholism, immunodeficiency, family history of multiple endrocrine neoplasia MEN type 1 and 2, von Hippel-Lindau and neurofibromatosis type 1.[1]

Primary NEC of brain usually present early with history of repeated seizures and features of raised intracranial pressure.

On plain CT scan of head it appears hypodense ill-defined area which is non enhancing on contrast study. On MRI scan it appears hypointense in T1 weighted image, hyperintense in T2 weighted image and predominantly non-enhancing on contrast study except areas of varigated enhancement at periphery. On MR spectroscopy, high choline peak is usually seen which suggest a highly proliferating lesion. There is no definite radiological signs characteristic of primary NEC of brain as seen in other brain tumors. Most often the radiological diagnosis is high grade glioma.

The salient histological features of NEC are monomorphic round to spindle cells with high N:C ratios, arranged in nests and papillaroid pattern with thin delicate fibroconnective tissue and focal glandular differentiation. Increased mitosis and necrosis are also seen. However true/pseudo rosettes are absent. The confirmatory diagnosis is only established by IHC markers study like NSE, SP etc. Typical punctate perinuclear (CK) and grimellius stain positivity are hall mark for the diagnosis of NEC as seen in our case.[5]

The main differential diagnosis include olfactory neuroblastoma which is differentiated by presence of typical homer wright rosettes and fibrillary background.[7] Location wise small cell GBM is the most common differential which classically present as butterfly like lesion, but presence of increased mitosis, endothelial cell proliferation, glio-fibrillary background and strong positivity to GFAP stain differentiate GBM from NEC.[8]

Anaplastic primary central nervous system lymphoma (PCNSL) of B cell type sometimes confuse the diagnosis of NEC which is differentiated on the basis of prominent nucleoli, brisk mitosis, diffuse arrangement and CD20,45 positivity classical of anaplastic PCNSL.[8]

Though NET are slow growing, radiosensitive tumors, NEC has high rate of recurrence and metastatic dissemination to lung, bone, spine and lymphnode.[2] The bad prognostic factors of NEC are non-functional tumor, Ki67 positivity, anenoploidy and distant metastasis.[1] Radical resection with adjuvant radiotherapy is preferred treatment option for solitary lesions.[3] However chemotherapy is given as palliation in advanced stage and metastatic tumors.[2]

Primary NEC of brain is rare, only one case has been reported in the literature. Our case is probably the second case of primary NEC in left frontal lobe. IHC study, typical punctate perinuclear (CK) and grimellius grimelius stain positivity in particular are is the confirmatory test to establish a final diagnosis of primary NEC. Early diagnosis and prompt treatment can prolong the survival.

REFERENCES

1. Klimstra DS, Modlin IR, Coppola D, Lloyd RV, Suster S. The pathologic classification of neuroendocrine tumors: A review of nomenclature, grading, and staging systems. Pancreas 2010;39:707-12.
2. Matula C, Roessler K, Burian M, Schuster H, Trattnig S, Hainfllner JA, Budka H. Primary neuroendocrine carcinoma of anterior skull base. Skull Base Surgery 1997;7:151-8.
3. Pavel M, Grossman A, Arnold R, Pereen A, Kaltas g, Stein Muller T, *et al*. ENET consensus guidelines for the management of brain, cardiac and ovarian metastasis from neuroendocrine tumours. Neuroendocrinology 2010;91:326-32.
4. Isaka T, MarunoM, Sato M, Kinoshita M, Nishid T, Kiyohara H, Yoshimine T. Brain metastasis from small cell neuro endocrine carcinoma of urinary bladder: A case report. Brain tumor pathol 2002;19:117-22.
5. Silva EG, Butler JJ, Mackay B, Goepfert H. Neuroblastomas and neuroendocrine carcinomas of nasal cavity. Cancer 1982;50:2388-405.
6. Austin JR, Cebrum H, Kesrshisnik MM, EC-Naggao AK, Garden AS, Demonte F, *et al*. Olfactory neuroblastoma and neuroendocrine carcinoma of the anterior skull base: Treatment results at the M.D Anderson Cancer centre. Skull Base Surgery 1996;6:1-8.
7. Chernov M, Demonte F. Skull base tumours. Soc Neuro onc.org 2001;e-12:300-19.
8. Powers JM, Horoupian DS. Central Nervous system. In: Damjanov I, Linder J, editors. Anderson's Pathology. 10th ed. Baltimore Mosby; 1996: 2758.

How to cite this article: Mohapatra SS, Tripathy P, Sahoo RK, Mohapatra D. Primary neuroendocrine carcinoma of brain radiologically mimicking high grade glioma: A case report and review of literature. Indian J Neurosurg 2013;2:288-90.

Source of Support: Nil, **Conflict of Interest:** None declared.

This document was downloaded for personal use only. Unauthorized distribution is strictly prohibited.