

Concomitant occurrence of vestibular schwannoma and epidermoid tumor

B. V. Savitr Sastri, H. V. Satish Babu

Department of Neurosurgery, Vydehi Institute of Medical Sciences and Research Centre, Bangalore, Karnataka, India

ABSTRACT

The occurrence of two tumors adjacent to each other at the same site is very rare. We present here, a patient with a vestibular schwannoma found adjacent to an epidermoid tumor in the cerebellopontine angle.

Key words: Cerebellopontine angle, epidermoid, schwannoma

INTRODUCTION

The coincidental occurrence of two tumors in the cerebellopontine angle is rare. We present a case of a vestibular schwannoma and epidermoid tumor in the same patient.

CASE REPORT

The patient was a 38-year-old male who complained of left sided hearing loss since 8 months which was insidious in onset and progressive in nature. The patient also had history of swaying to the left, 3 months prior to admission. There was no history of irritative symptoms such as facial pain or tinnitus. The patient demonstrated profound sensorineural hearing loss in the left ear and mild left cerebellar signs.

Magnetic resonance imaging (MRI) of the brain revealed a lesion isointense on T1 weighted and hyperintense on T2 weighted sequences in the left cerebellopontine (CP) angle, which was enhancing on contrast [Figure 1a-c].

Ventral to the lesion and the brainstem, occupying bilateral preponine cisterns and the right cerebellopontine cistern a second lesion was noted, which was hypointense on

T1 weighted, hyperintense on T2 weighted sequences. While the initial impression was that of an enlarged preponine cistern, the second lesion was partially inverting on FLAIR. It also showed restricted diffusion when compared to CSF [Figures 1a, b and 2a, b].

A diagnosis of concomitant vestibular schwannoma with epidermoid tumor was made.

The patient underwent a retromastoid suboccipital craniectomy and excision of the schwannoma. Ventral to this tumor, beyond the arachnoid, the pearly white appearance of the epidermoid was noted [Figure 3]. The second tumor was not decompressed since access to the same via the retromastoid approach was limited.

The patient recovered uneventfully with a Grade 2 House and Brackmann facial paresis and was discharged.

DISCUSSION

Vestibular schwannomas are the most common tumors of the cerebellopontine angle, accounting for 70-80% of all tumors seen in the region. Concomitant existence of two tumors however is rare. There have been two reported cases of a vestibular schwannoma coexisting with an epidermoid cyst as a single cerebellopontine angle mass.^[1,2] Saito *et al.* reported development of a vestibular schwannoma in a patient many years after excision of a cerebellopontine angle epidermoid.^[3] This is the fourth such case of a vestibular schwannoma growing adjacent to an epidermoid tumor.

There have been scattered reports of VII and VIII nerve schwannomas coexistent with ipsilateral arachnoid

Access this article online

Quick Response Code:



Website:

www.ijns.in

DOI:

10.4103/2277-9167.124237

Address for correspondence: Dr. B. V. Savitr Sastri,

Department of Neurosurgery, Vydehi Institute of Medical Sciences and Research Centre, Whitefield, Bangalore - 560 066, Karnataka, India.

E-mail: savitr@gmail.com

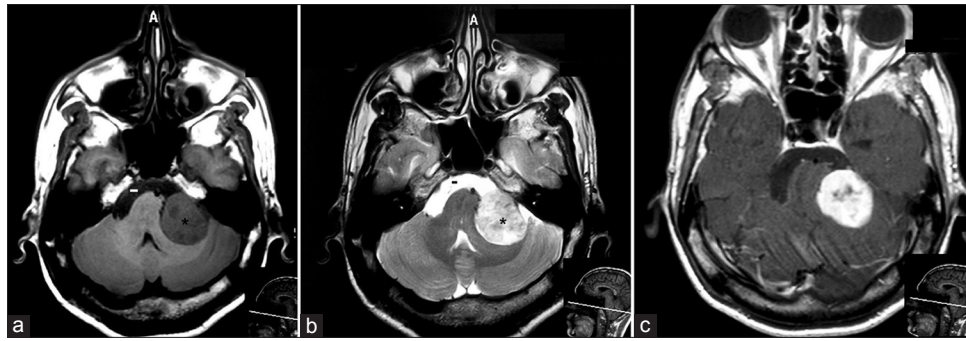


Figure 1: (a and b) T1 and T2 weighted MRI showing the schwannoma (*) and the epidermoid (-). (c) Contrast enhanced image where the schwannoma is enhancing

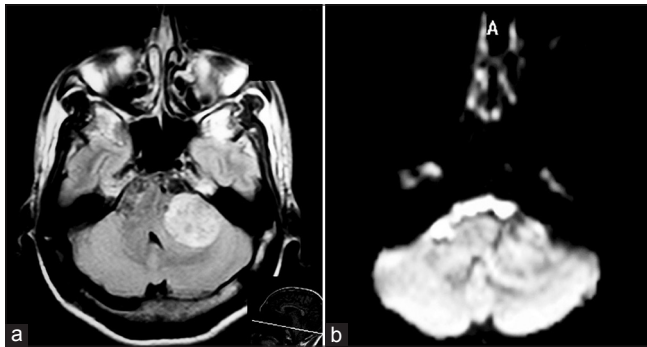


Figure 2: (a) FLAIR image with partial inversion of the epidermoid. (b) Diffusion weighted images showing restricted diffusion in the epidermoid

It is therefore difficult to explain how these two tumors exist simultaneously. Multiple histological types of primary brain tumors may be seen in phacomatoses or perhaps following cranial irradiation. Saito *et al.* postulated that perhaps the chronic irritation caused by the remnants of the epidermoid following the first surgery in their case may have caused the schwannoma to develop.^[3]

The evidence to prove a causality or association is however lacking and this may be a coincidental finding in all the above cases.

REFERENCES

1. Goodman RR, Torres RA, McMurtry JG 3rd. Acoustic schwannoma and epidermoid cyst occurring as a single cerebellopontine angle mass. *Neurosurgery* 1991;28:433-6.
2. Kleinpeter G, Matula C, Koos W. Another case of acoustic schwannoma and epidermoid cyst occurring as a single cerebellopontine angle mass: Possibly not so rare? *Surg Neurol* 1994;41:310-2.
3. Saito A, Sugawara T, Watanabe R, Akamatsu Y, Mikawa S, Seki H. Evolution of vestibular schwannoma after removal of epidermoid cyst of the same location: Case report. *Neurol Med Chir* 2009; 49:495-8.
4. Ebmeyer J, Gehl HB, Reineke U, Sudhoff H. Simultaneous ipsilateral epidermoid of the petrous apex combined with intracanalicular and extracanalicular facial schwannoma. *Otol Neurotol* 2009;30:575-6.
5. Muzumdar DP, Chagla AS, Goel A. Acoustic schwannoma and arachnoid cyst collocated in the cerebellopontine angle: Case report. *Neurol Med Chir* 2000;40:230-3.
6. Talacchi A, Giorgiutti F, Andrioli M, Turazzi S, Bricolo A. Intracranial coexistence of neurinoma with epidermoid cyst or cholesterol granuloma. Report of 2 cases. *J Neurosurg Sci* 1997;41:179-88.
7. Zhao AS, Lee HJ, Jyung RW. Concomitant, contralateral vestibular schwannoma and epidermoid cyst. *Laryngoscope* 2010;120 Suppl 4:S220.

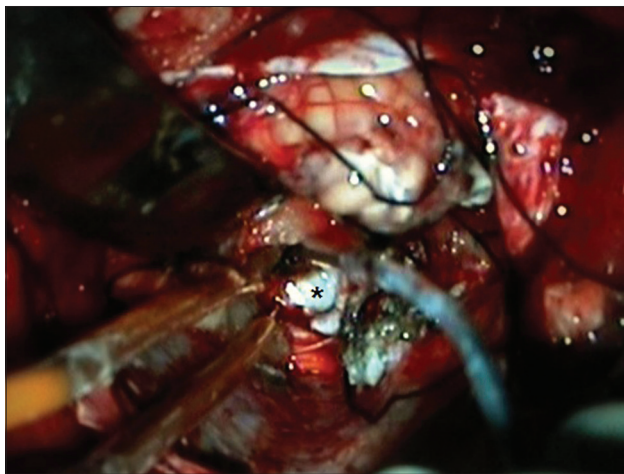

Figure 3: Intraoperative image showing the pearly white appearance of the epidermoid (*) seen after removal of the schwannoma

cysts and trigeminal, and VIII nerve schwannomas with contralateral epidermoids and cholesterol granulomas.^[4-7]

While epidermoid tumors are thought to originate in utero and are slow growing congenital neoplasms thought to arise from epidermal inclusions, vestibular schwannomas develop postnatally from the vestibular division of the 8th cranial nerve.

How to cite this article: Savitr Sastri BV, Satish Babu HV. Concomitant occurrence of vestibular schwannoma and epidermoid tumor. *Indian J Neurosurg* 2013;2:282-3.

Source of Support: Nil, **Conflict of Interest:** None declared.