

# Endovascular therapy of ruptured distal anterior choroidal artery aneurysm associated with moyamoya pattern collateralization secondary to middle cerebral artery occlusion

Hidenori Oishi, Yasuo Suga<sup>1</sup>, Senshu Nonaka<sup>1</sup>

Departments of Neurosurgery and Neuroendovascular Therapy, and <sup>1</sup>Neurosurgery, Juntendo University School of Medicine, Tokyo, Japan

## ABSTRACT

We report a case of a ruptured distal anterior choroidal artery (AChoA) aneurysm associated with moyamoya pattern collateralization secondary to the middle cerebral artery occlusion. Patient was successfully treated with the coil embolization of the distal AChoA. This case supports the feasibility and efficacy of the endovascular therapy for the distal AChoA aneurysms in patients with MCA occlusion with moyamoya pattern collateralization.

**Key words:** Coil embolization, distal anterior choroidal artery aneurysm, endovascular therapy

## INTRODUCTION

Distal anterior choroidal artery (AChoA) aneurysms are quite rare. We report a case of an endovascularly treated ruptured distal AChoA aneurysm associated with a moyamoya pattern of collateralization secondary to middle cerebral artery (MCA) occlusion.

## CASE REPORT

A 75-year-old woman presented with a sudden onset of loss of consciousness and left hemiplegia. She had medically uncontrolled hypertension. She was transferred to a stroke center near her house. Computed tomography showed an intracerebral hematoma in the right temporal lobe [Figure 1]. She underwent surgical evacuation of the hematoma to relief the mass effect on the day of admission and was transferred to our hospital after 1 month of rehabilitation with mild consciousness disturbance, severe left hemiparesis, and right homonymous hemianopsia. Catheter angiography showed a distal AChoA aneurysm, a moyamoya pattern of collateralization and MCA occlusion [Figure 2].

The aneurysm was proximal to the plexal point of the AChoA. Left internal carotid and vertebrobasilar angiograms showed no evidence of previously manifested moyamoya disease.

Endovascular therapy was performed under general anesthesia. Systemic heparinization was initiated to maintain the activated clotting time between 250 and 300 s throughout the procedure after the placement of the arterial introducer sheath and was stopped at the end of the procedure. Provocative testing was not scheduled because the patient's neurological condition was not appropriate for an accurate assessment. The triple coaxial system consisted of a 7-French (F) guiding catheter as the outer catheter, and a 4-F guiding catheter as the middle catheter was used to facilitate the microcatheter manipulation. The microcatheter (Excelsior SL-10, Striker, Fremont, CA, USA) was advanced into the right AChoA with the assistance of a microguidewire (GT Wire, Terumo, Tokyo, Japan). We failed to insert the microcatheter into the aneurysm because of the acute angulation and small caliber of the parent artery. Selective injection via the microcatheter positioned at the distal AChoA showed the aneurysm and collateral vessels [Figure 3]. Six detachable platinum coils (Four Axium coils: Ev3, Irvine, CA, USA; one target coil: Striker, Fremont, CA; and one ED coil: Kaneka, Osaka, Japan) were delivered to occlude the parent artery in as short of a segment as possible [Figure 4]. Post-treatment angiography including posterior circulation showed disappearance of the aneurysm with preservation of the

### Access this article online

#### Quick Response Code:



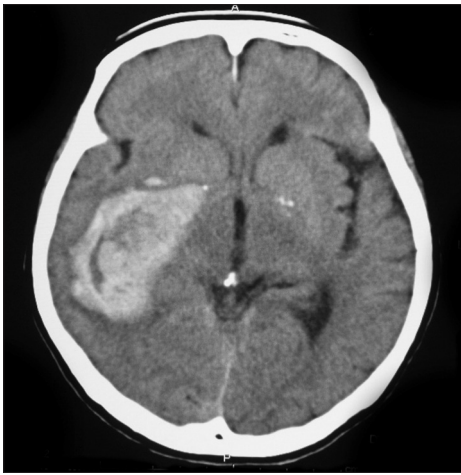
#### Website:

www.ijns.in

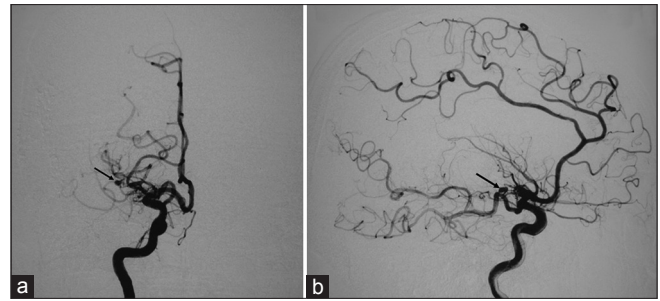
#### DOI:

10.4103/2277-9167.124236

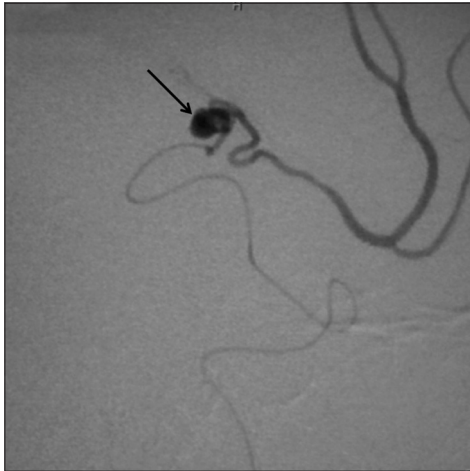**Address for correspondence:** Prof. Hidenori Oishi, 2-1-1, Hongo, Bunkyo-Ku, Tokyo, Japan. E-mail: ohishi@juntendo.ac.jp



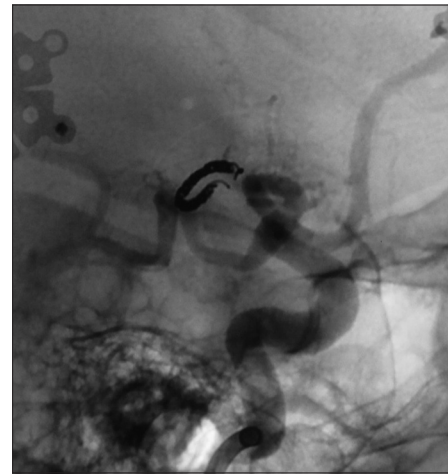
**Figure 1:** Computed tomography showing an intracerebral hematoma in the temporal lobe



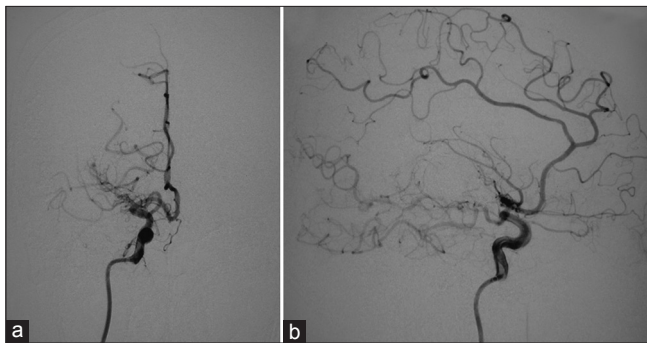
**Figure 2:** Right internal carotid angiogram, (a) frontal view and (b) lateral view showing a distal anterior choroidal artery aneurysm (arrow), moyamoya pattern collateralization, and middle cerebral artery occlusion



**Figure 3:** Selective injection via microcatheter showing the aneurysm (arrow)



**Figure 4:** Coils placed within the anterior choroidal artery



**Figure 5:** Post-treatment right internal carotid angiogram, (a) frontal view and (b) lateral view showing the disappearance of the aneurysm

moyamoya pattern of collateralization [Figure 5]. She was transferred to the rehabilitation center. At 3 months after the endovascular therapy, the patient was awake and alert, following commands briskly and verbalizing comprehensible words. Left severe hemiparesis partially improved to the Brunstrom stage III including fingers.

## DISCUSSION

Although aneurysms arising from the origin of the AChoA make up 2-5% of all intracranial aneurysms, distal AChoA aneurysms are quite rare.<sup>[1,2]</sup> The etiologies are moyamoya disease, idiopathic, iatrogenic, infection, dissection, trauma, and arteriovenous malformation.<sup>[2-4]</sup> Atherosclerosis has also been reported as a potent etiological factor due to the hemodynamic stress and degeneration of the arterial wall.<sup>[5,6]</sup> MCA occlusion may compensatorily increase the hemodynamic stress of the AChoA leading to a development of the distal aneurysm. To the best of our knowledge, only three cases of the distal AChoA aneurysm associated with the MCA occlusion have been reported.<sup>[7,8]</sup>

In the literature, most of the patients with ruptured distal AChoA aneurysms underwent an open surgery (clipping or trapping). However, the open surgery is technically challenging because of the difficulty of accurate localization of and clearly exposing the aneurysm due to the deep and narrow operating field,<sup>[9]</sup> and open surgery is also a more invasive procedure in presence of collateral vessels.

**Table 1: Distal anterior choroidal artery aneurysms treated with endovascular therapy**

Study (Ref. no.)	Year	Sex (F/M)	Presentation	Etiology	Embolitic agent	Outcome
Kim <i>et al.</i> <sup>[14]</sup>	2009	43/F	IVH	Moyamoya disease	Glue	Stationary
Yang <i>et al.</i> <sup>[3]</sup>	2010	56/F	Headache	Moyamoya disease	Glue	Good
		38/F	IVH, headache	Moyamoya disease	Coil	Good
Nishida <i>et al.</i> <sup>[7]</sup>	2011	84/F	IVH	MCA occlusion	Coil	Fair
Dolati <i>et al.</i> <sup>[4]</sup>	2012	55/M	IVH	Iatrogenic PCA occlusion	Glue	Good
Present case	2013	75/F	ICH	MCA occlusion	Coil	Fair

IVH - Intraventricular hemorrhage; ICH - Intracerebral hematoma; MCA - Middle cerebral artery; PCA - Posterior cerebral artery

Endovascular therapy has become an alternative treatment of ruptured intracranial aneurysms.<sup>[10]</sup> It has the advantages of minimal invasiveness and accurate localization of the aneurysm. To the best of our knowledge, only four studies with five patients with distal AChoA aneurysms were endovascularly treated [Table 1]. AChoA was divided into intracisternal and intraplexal segments.<sup>[11]</sup> The boundary is the so called plexal point at which the AChoA enters into the temporal horn of the lateral ventricle through the choroidal fissure. Marinković *et al.* reported that the embolization of intraplexal segment is safe because the main branches of the AChoA have diverged before the plexal point.<sup>[12]</sup> However, the embolization of intraplexal segment may cause ischemic symptoms because the plexal segment of AChoA has branches supplying the thalamus, an optic tract and a lateral geniculate body.<sup>[11,13]</sup>

Kim *et al.* advocated the feasibility of glue embolization rather than coil embolization because the AChoA is too small and fragile for safety advancement of a stiff microcatheter. The aneurysms are often small and may be pseudoaneurysms that makes a safe coil embolization difficult.<sup>[14]</sup> However, the glue embolization has a high risk of ischemic complications compared with the coil embolization because the glue can distally penetrate and occlude the collateral vessels.<sup>[15,16]</sup> Furthermore, skillful interventionalists are required to determine the appropriate glue dilution, which depends upon the catheter tip positioning and the blood flow. Nishida *et al.* first reported coil embolization of a ruptured distal AChoA aneurysm associated with a moyamoya pattern of collateralization secondary to an MCA occlusion. They occluded the aneurysm itself and the distal AChoA without compromise of the moyamoya pattern of collateralization.<sup>[7]</sup> Although the microcatheter could not be advanced within the aneurysm in the present case, the blood flow of the aneurysm was successfully stopped with the coil embolization of the distal AChoA in as short of a segment as possible. The development of microcatheters and coils will make safe coil embolization of distal aneurysms possible.

## CONCLUSION

Endovascular therapy is feasible and effective for ruptured AChoA aneurysms with a moyamoya pattern of collateralization secondary to a MCA occlusion.

## REFERENCES

- Friedman JA, Pichelmann MA, Piepgras DG, Atkinson JL, Maher CO, Meyer FB, *et al.* Ischemic complications of surgery for anterior choroidal artery aneurysms. *J Neurosurg* 2001; 94:565-72.
- Inci S, Arat A, Ozgen T. Distal anterior choroidal artery aneurysms. *Surg Neurol* 2007;67:46-52.
- Yang S, Yu JL, Wang HL, Wang B, Luo Q. Endovascular embolization of distal anterior choroidal artery aneurysms associated with moyamoya disease. A report of two cases and a literature review. *Interv Neuroradiol* 2010;16:433-41.
- Dolati P, Sutherland G, Wong J, Hudon M, Goyal M. Distal anterior choroidal artery aneurysm following iatrogenic posterior cerebral artery occlusion: A case report and review of literature. *Acta Neurochir (Wien)* 2012;154:53-7.
- Knuckey NW, Epstein MH, Haas R, Sparadeo F. Distal anterior choroidal artery aneurysm: Intraoperative localization and treatment. *Neurosurgery* 1988;22:1084-7.
- Papo I, Salvolini U, Caruselli G. Aneurysm of the anterior choroidal artery with intraventricular hematoma and hydrocephalus. Case report. *J Neurosurg* 1973;39:255-60.
- Nishida A, Tokunaga K, Hishikawa T, Sugiu K, Date I. Endovascular coil embolization of a ruptured distal anterior choroidal artery aneurysm associated with ipsilateral middle cerebral artery occlusion: Case report. *Neurol Med Chir (Tokyo)* 2011;51:716-9.
- Oishi H, Shimizu T, Nakai K, Miyajima M, Arai H. Successful treatment of a thrombosed posterior cerebral artery aneurysm causing obstructive hydrocephalus. *J Clin Neurosci* 2008;15:199-202.
- Kaku Y, Yamashita K, Kokuzawa J, Hatsuda N, Andoh T. Treatment of ruptured cerebral aneurysms-Clip and coil, not clip versus coil. *Acta Neurochir Suppl* 2010;107:9-13.
- Molyneux A, Kerr R, Stratton I, Sandercock P, Clarke M, Shrimpton J, *et al.* International Subarachnoid Aneurysm Trial (ISAT) of neurosurgical clipping versus endovascular coiling in 2143 patients with ruptured intracranial aneurysms: A randomised trial. *Lancet* 2002;360:1267-74.
- Morandi X, Brassier G, Darnault P, Mercier P, Scarabin JM, Duval JM. Microsurgical anatomy of the anterior choroidal artery. *Surg Radiol Anat* 1996;18:275-80.
- Marinković S, Gibo H, Brigante L, Nikodijević I, Petrović P. The surgical anatomy of the perforating branches of the anterior choroidal artery. *Surg Neurol* 1999;52:30-6.
- Fujii K, Lenkey C, Rhoton AL Jr. Microsurgical anatomy of the choroidal arteries: Lateral and third ventricles. *J Neurosurg* 1980;52:165-88.
- Kim SH, Kwon OK, Jung CK, Kang HS, Oh CW, Han MH, *et al.* Endovascular treatment of ruptured aneurysms or pseudoaneurysms on the

collateral vessels in patients with moyamoya disease. *Neurosurgery* 2009;65:1000-4.

15. Konishi Y, Kadowaki C, Hara M, Takeuchi K. Aneurysms associated with moyamoya disease. *Neurosurgery* 1985;16:484-91.
16. Furuse S, Matsumoto S, Tanaka Y, Ando S, Sawa H, Ishikawa S. Moyamoya disease associated with a false aneurysm: Case report and review of the literature. *No Shinkei Geka* 1982;10:1005-12.

**How to cite this article:** Oishi H, Suga Y, Nonaka S. Endovascular therapy of ruptured distal anterior choroidal artery aneurysm associated with moyamoya pattern collateralization secondary to middle cerebral artery occlusion. *Indian J Neurosurg* 2013;2:278-81.

**Source of Support:** Nil, **Conflict of Interest:** None declared.

### "Quick Response Code" link for full text articles

The journal issue has a unique new feature for reaching to the journal's website without typing a single letter. Each article on its first page has a "Quick Response Code". Using any mobile or other hand-held device with camera and GPRS/other internet source, one can reach to the full text of that particular article on the journal's website. Start a QR-code reading software (see list of free applications from <http://tinyurl.com/yzlh2tc>) and point the camera to the QR-code printed in the journal. It will automatically take you to the HTML full text of that article. One can also use a desktop or laptop with web camera for similar functionality. See <http://tinyurl.com/2bw7fn3> or <http://tinyurl.com/3ysr3me> for the free applications.