

# Endovascular coil embolization for recurrence of intracranial aneurysms more than 10 years after clipping

Naoya Takeda, Keiji Kidoguchi, Kazuya Matsuo, Masamitsu Nishihara

Department of Neurosurgery, Nishi-Kobe Medical Center, 5-7-1, Kouji-dai, Nishi-ku, Kobe City, Japan

## ABSTRACT

We report three cases of endovascular coil embolization for recurrent cerebral aneurysm after neck clipping more than 10 years previously. In two cases, their first subarachnoid hemorrhage was treated in other hospitals and the details of follow-up after discharge were unknown. After their second subarachnoid hemorrhage recurred 15 and 30 years, respectively. The remaining patient, who was treated in our center, was followed by magnetic resonance imaging 5 years after surgery but since then she didn't go to our center. She came to our center for follow-up examination 10 years after the first surgery. The digital subtraction angiography showed recurrence of clipped aneurysms in all patients. All of them underwent endovascular coil embolization and total obliteration of the aneurysms without complications related to the procedures. Endovascular coil embolization is an alternative modality to direct surgery for cerebral aneurysms, especially for recurrence after clipping. Endovascular coil embolization of residual aneurysms after surgery may be the treatment of choice because of the difficulties in second direct surgery. We conclude that it is necessary to perform follow-up evaluations after surgery, even if the complete obliteration of aneurysms is performed. Current medical literature does not provide recommendations for the duration of follow-up after aneurysm clipping. The authors suggest that this period perhaps be at least a decade.

**Key words:** Clipping, endovascular surgery, residual aneurysm, subarachnoid hemorrhage

## INTRODUCTION

Developments in microsurgical techniques have facilitated straightforward, safe and accurate cerebral aneurysm treatment. However, the recurrence or regrowth of residual aneurysms after neck clipping is not rare. We report three cases of endovascular coil embolization for recurrent cerebral aneurysm after neck clipping more than 10 years previously.

## CASE REPORTS

### Case 1

The present case report is about a 76-year-old female patient who presented with the left ptosis and diplopia and digital subtraction angiography (DSA) showed bilateral internal carotid artery-posterior communicating

artery (IC-PC) aneurysms [Figure 1, upper]. Emergency neck clipping of bilateral IC-PC aneurysms were performed in our center. At 2 months after the operation, oculomotor palsy had disappeared. Post-operative condition was favorable and she was followed-up by magnetic resonance imaging (MRI) 5 years after surgery but since then she didn't go to our center. At 10 years after surgery, she came to our center for follow-up to check for the recurrence of aneurysms. Multidetector computed tomography angiography (MDCTA) revealed the recurrence of cerebral aneurysm close to the clip at the left IC-PC [Figure 1, lower]. Endovascular coil embolization was performed under general anesthesia. A Tracker No.18 catheter was advanced into the aneurysm sac and Guglielmi detachable coils (Stryker, Fremont, CA, USA) were placed, resulting in complete obliteration of the aneurysm [Figure 2]. The post-embolization course was uneventful.

### Case 2

The second case was a 61-year-old female patient had suffered *subarachnoid hemorrhage* (SAH) due to a ruptured anterior communicating aneurysm, which was treated with clipping at another hospital. Post-operative course was uneventful. However, since then, she didn't undergo a follow-up study. 15 years after clipping, she

Access this article online	
Quick Response Code:	Website: www.ijns.in
	DOI: 10.4103/2277-9167.124234

**Address for correspondence:** Dr. Naoya Takeda, Department of Neurosurgery, Nishi-Kobe Medical Center, 5-7-1, Kouji-dai, Nishi-ku, Kobe City, Japan. E-mail: takedake@ai.wakwak.com

presented with acute onset and persistent headache for 4 days. A computed tomography (CT) scan revealed another subarachnoid hemorrhage (Fisher group III) [Figure 3, left]. The DSA showed recurrence of the anterior communicating aneurysm close to the clip [Figure 3, right]. Subsequently, endovascular treatment was performed, with total obliteration of the aneurysm [Figure 4]. She was discharged without neurological deficits.

### Case 3

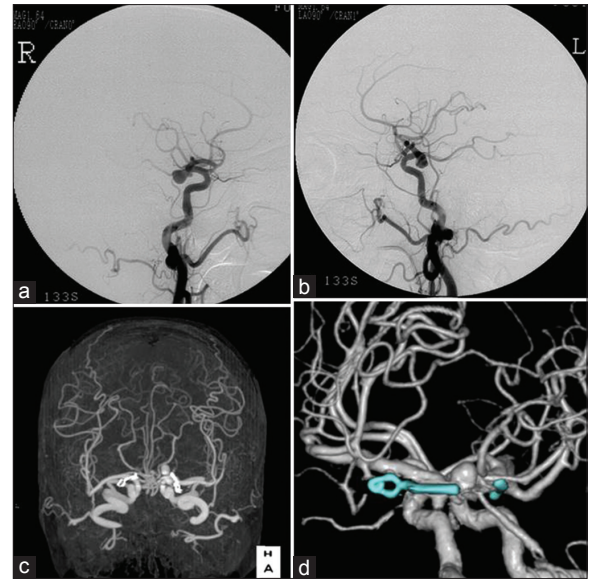
This was a third case report of a 61-year-old male patient who had suffered SAH caused by aneurysmal rupture of the right middle cerebral artery bifurcation and was treated by clipping at another hospital. Since then, he was favorable but the details of follow-up examinations were unknown. At 30 years later, he was admitted to our center due to sudden unconsciousness and left hemiparesis followed by deterioration into a coma with a dilated right pupil and decerebrate posture. A CT scan revealed diffuse subarachnoid hemorrhage with intracerebral hematoma (Fisher's grade IV) followed by MDCTA, showing right middle cerebral artery bifurcation aneurysm (16 mm × 14 mm) close to the clip applied previously [Figure 5]. Immediately after admission, bilateral external ventricular drainage was performed followed by total obliteration of the aneurysm by endovascular coil embolization [Figure 6]. At 2 months later, ventriculoperitoneal shunting was performed. However, he was in a vegetative state due to the damage caused by the SAH.

## DISCUSSION

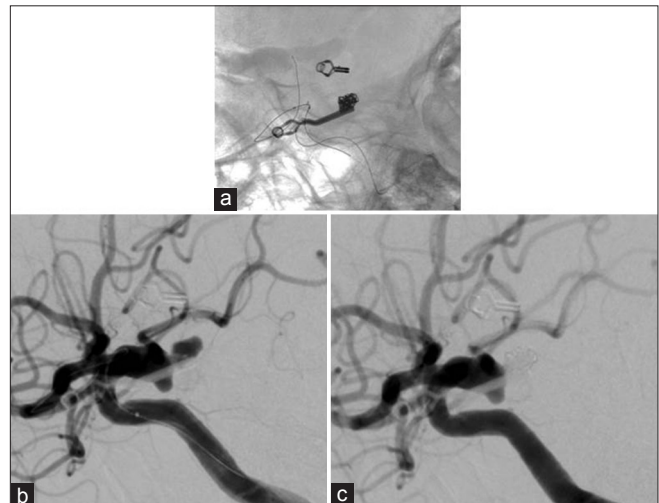
Neck clipping of cerebral aneurysms is now safe and accurate owing to the development of microsurgical techniques. However, the natural history of cerebral aneurysms after neck clipping has not been sufficiently documented. El-Beltagy *et al.*<sup>[1]</sup> in their study have reported that cerebral aneurysms recurred  $13.3 \pm 7.8$  years on average after surgery (0.02%/year) in 9 out of 1,016 patients who underwent complete clipping. In seven of these, recurrence was detected more than 10 years after surgery (mean: 16.7 years, ranging from 10 to 25 years).

In an article in 1998, Tsutsumi *et al.*<sup>[2]</sup> reported that the cumulative recurrence rate of SAH after the complete obliteration of aneurysms was 2.2% at 10 years and 9.0% at 20 years after the original treatment. The rate increased with time. They stated that patients with ruptured aneurysms still carry high risks for SAH over a long-term period, even after complete obliteration.

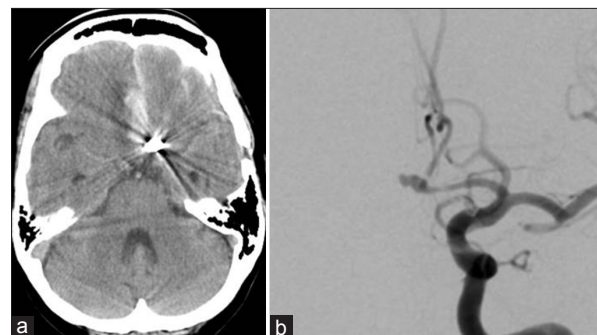
The rate of the incomplete obliteration of aneurysms



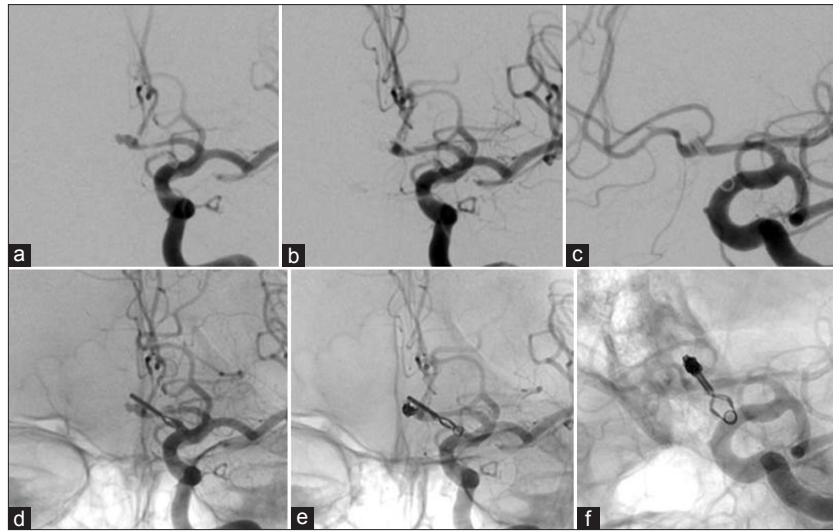
**Figure 1:** Case 1 - Digital subtraction angiography 10 years earlier showing bilateral internal carotid artery-posterior communicating artery (IC-PC) aneurysms (upper) and multidetector computed tomography angiography showing the recurrence of left IC-PC aneurysm close to the applied clip of the first surgery (lower)



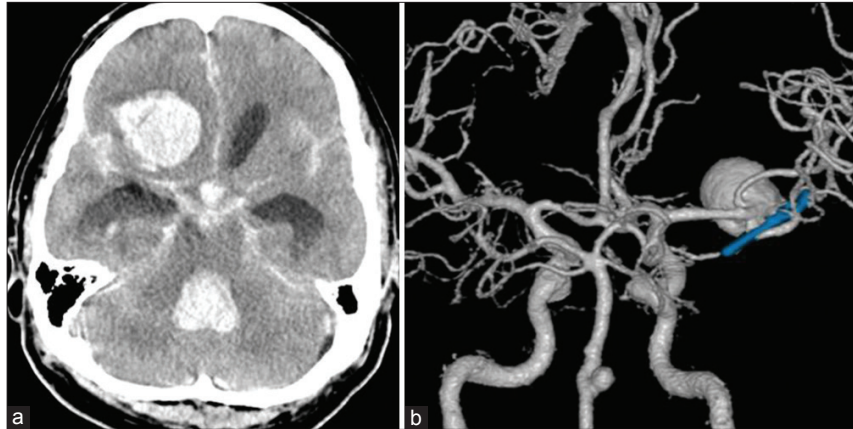
**Figure 2:** Digital subtraction angiography (DSA) showing a left internal carotid artery-posterior communicating artery saccular aneurysm (lower left) and post-embolization DSA showing total obliteration of the aneurysm (lower right) and embolized coils (upper)



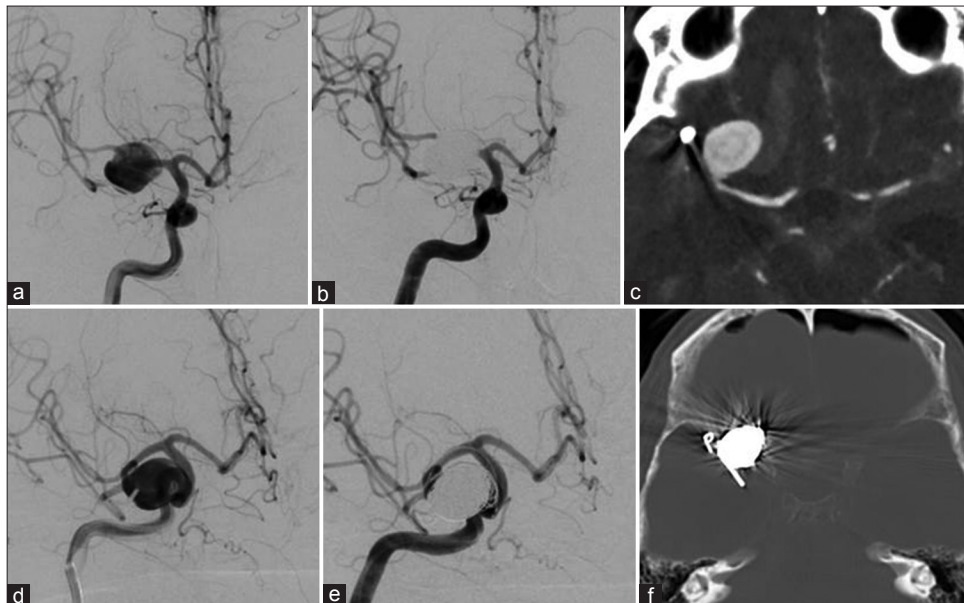
**Figure 3:** Case 2 - Computed tomography scan on admission revealing subarachnoid hemorrhage and intracerebral hematoma (left) and pre-embolization digital subtraction angiography showing recurrence of an anterior communicating aneurysm close to the clip (right)



**Figure 4:** Pre-(left) and post-embolization digital subtraction angiography showing complete obliteration of an aneurysm in an A-P view (middle) and oblique view (right)



**Figure 5:** Case 3 - Computed tomography scan on admission revealing subarachnoid hemorrhage (left) and multidetector computed tomography angiography showing a right middle cerebral artery bifurcation aneurysm completely dislocating from the clip (right)



**Figure 6:** Pre-embolization digital subtraction angiography (DSA) showing recurrence of an aneurysm close to the clip (left), the post-embolization DSA showing total obliteration of the aneurysm (middle) and computed tomography scan revealing embolized coils close to the clip (right)

after clipping on immediate post-operative angiography has been estimated at 3.8%<sup>[3]</sup> and 6.7% respectively.<sup>[4]</sup>

How is the natural history of residual aneurysms?

A study by Feuerberg *et al.*<sup>[3]</sup> stated that one in 27 patients with incomplete clipping (3.7%) developed SAH from increased residua 5 years after the first surgery, but the other residua obliterated spontaneously in 5 patients, decreased in size in 2 and were unchanged in 13, resulting in an annual risk of rebleeding from residua of 0.8%.

They also stated that the rate of recurrent SAH in aneurysms with residua is higher compared with those without residua.

However, in many of the neurosurgical centers, a follow-up imaging study after clipping to detect recurrent or residual aneurysms was not necessarily performed.

In all our patients, post-operative angiography or MDCTA was not performed at least more than 10 years after surgery (10, 15 and 30 years). It is not suitable for MRI to detect the recurrence of cerebral aneurysm due to artifacts of applied clips. It is controversial whether angiography or MDCTA should be performed for all patients irrespective of clipping or not.

A study of Sakaki *et al.*<sup>[5]</sup> speculated that the causes of recurrence or regrowth of cerebral aneurysms were: (1) Damage of intima due to temporary clipping, (2) degeneration or fragility of arterial wall due to the permanent clip itself, (3) microscopic residual of neck, (4) original existence of a small bulging or thin-walled portion of the artery around the aneurysm and or clip and (5) slippage of the clip.

The most common patterns of aneurysm recurrence with respect to the clip application was that arising distal to the clip tines (46.1%) and the inadequate attention to the basic surgical principle of ensuring that the clip tines completely straddle the aneurysm neck was suggested as one of the factors.<sup>[6]</sup>

The mean interval of confirming recurrent aneurysms after surgery was reported as long as 13.3 years<sup>[3]</sup> and 12.4 years.<sup>[6]</sup>

Optimal intervals of follow-up evaluation after surgery are not known.

Tsutsumi *et al.*<sup>[7]</sup> stated that, for patients with incompletely clipped aneurysms, more frequent follow-up angiography (e.g., every 3 years) may be indicated.

Wermer *et al.*<sup>[8]</sup> stated that follow-up evaluation might be recommended every 5 years, especially in young women with SAH.

Consequently, we suggest that follow-up DSA and/or MDCTA will be done 6 months after coil embolization for the confirmation of the obstruction of aneurysm and then at a 1-year interval for 3 years and every 2 years thereafter at least for 10 years.

Recently, advances in endovascular surgery have been marked and provide alternative modalities to neck clipping for cerebral aneurysms. Kang *et al.*<sup>[9]</sup> reported that recurrent aneurysms were embolized successfully in all 13 cases, resulting in total or near-total obliteration of aneurysms. All our three reported patients with recurrent cerebral aneurysms were also treated successfully with endovascular coil embolization.

It is controversial about the best management. We suggest that endovascular coil embolization of residual aneurysms after surgery may be the treatment of choice because of the difficulties in second direct surgery.

## REFERENCES

1. El-Beltagy M, Muroi C, Roth P, Fandino J, Imhof HG, Yonekawa Y. Recurrent intracranial aneurysms after successful neck clipping. *World Neurosurg* 2010;74:472-7.
2. Tsutsumi K, Ueki K, Usui M, Kwak S, Kirino T. Risk of recurrent subarachnoid hemorrhage after complete obliteration of cerebral aneurysms. *Stroke* 1998;29:2511-3.
3. Feuerberg I, Lindquist C, Lindqvist M, Steiner L. Natural history of postoperative aneurysm rests. *J Neurosurg* 1987;66:30-4.
4. Lee SH, Lim DJ, Kim SH, Kim SD, Hong KS, Park JY. Early postoperative cerebral angiography after clipping in patients with ruptured aneurysm: Its usefulness and indications. *Korean J Cerebrovasc Surg* 2011;13:201-5.
5. Sakaki T, Tominaga M, Miyamoto K, Tsunoda S, Hiasa Y. Clinical studies of de novo aneurysms. *Neurosurgery* 1993;32:512-6.
6. Spiotta AM, Hui F, Schuette A, Moskowitz SI. Patterns of aneurysm recurrence after microsurgical clip obliteration. *Neurosurgery* 2013;72:65-9.
7. Tsutsumi K, Ueki K, Morita A, Usui M, Kirino T. Risk of aneurysm recurrence in patients with clipped cerebral aneurysms: Results of long-term follow-up angiography. *Stroke* 2001;32:1191-4.
8. Wermer MJ, Greebe P, Algra A, Rinkel GJ. Incidence of recurrent subarachnoid hemorrhage after clipping for ruptured intracranial aneurysms. *Stroke* 2005;36:2394-9.
9. Kang HS, Han MH, Kwon BJ, Chang KH, Oh CW, Han DH. Endovascular treatment in post-surgical cerebral aneurysms. *J Korean Neurosurg* 2004;36:1-6.

**How to cite this article:** Takeda N, Kidoguchi K, Matsuo K, Nishihara M. Endovascular coil embolization for recurrence of intracranial aneurysms more than 10 years after clipping. *Indian J Neurosurg* 2013;2:271-4.

**Source of Support:** Nil, **Conflict of Interest:** None declared.