

# Controversies in neurosurgery: Irreducible basilar invagination and atlanto-axial dislocation: A trans-oral procedure may be avoided in a majority, but still may be required in some cases

P. Sarat Chandra

Department of Neurosurgery, All India Institute of Medical Sciences, New Delhi, India

## ABSTRACT

Basilar invagination (BI) and atlanto-axial dislocation (AAD) are mostly irreducible in nature and are quite complex pathologies to manage. Traditionally they required a trans-oral excision of odontoid process followed by a posterior instrumented fusion. This has been challenged recently, where a single staged posterior only procedure addresses both reduction and decompression in the same sitting. This evidence was based on earlier publication and also on the author's own experience, where he described a new technique (distraction, compression, extension and reduction), which performed for the 1<sup>st</sup> time a 2-axis movement in the cranio-vertebral junction (CVJ) allowing effective reduction of both AAD and BI. This technique has now become a standard in the author's armentarium for management of CVJ anomalies and allowed a single stage posterior only surgery for 95% of these pathologies managed by him. Although this technique could address a majority of cases of developmental BI and AAD, it becomes important to understand that a trans-oral excision of dens followed by a posterior instrumented fusion will still be required in some cases. These include certain cases of clival segmentation anomalies, very severe BI, infective pathologies like tuberculosis with circumferential compression and bony destruction and tumors. The following review article is based on the author's personal experience of over 500 cases and discusses the advantages and limitations of single staged surgery and the indications of trans-oral surgery in this rapidly evolving field.

**Key words:** Atlanto-axial dislocation, basilar invagination, compression, distraction, spacer

## INTRODUCTION

The past decade has seen remarkable improvements in development of innovative paradigms for management of basilar invagination (BI) and atlanto-axial dislocation (AAD). BI is characterized by telescoping of the upper cervical spine (more specifically the odontoid process) into the foramen magnum and may or may not be associated with AAD.<sup>[1-7]</sup>

Conventional strategies over the past three decades included a trans-oral excision of odontoid process followed by a posterior instrumented fixation.<sup>[8-13]</sup> This was based on the assumption if the BI and AAD do not reduce on traction, they are "irreducible" and the

only optimal option of treatment would be a "in situ" cervico-medullary decompression along with a spinal stabilization.

More recently, this concept has been changing. Cumulating evidence has been shown that distraction at the C1/C2 joints leads to a possibility of reduction of BI even in irreducible cases.<sup>[1,5-7,14-18]</sup> This has led to a possibility of considering the pathology of BI and AAD similar to "spondylolisthesis," which may be reduced through certain "specific" intra-operative manipulations. There have been a few studies where manipulations such as using distraction and other movements, has led to a satisfactory reduction.<sup>[14]</sup>

The following article briefly describes the developments, which have taken place till date. It will attempt to describe the advantages and limitations of the various posterior single staged reductions procedures. The article will also describe the current indications of trans-oral procedure followed by spinal stabilization. The main objective of the article would be to provide the readers an unbiased view of the various options available for the treatment of this complex pathology.

Access this article online	
Quick Response Code:	Website: www.ijns.in
	DOI: 10.4103/2277-9167.124228

**Address for correspondence:** Dr. P. Sarat Chandra,  
Department of Neurosurgery, All India Institute of Medical Sciences, New Delhi, India. E-mail: saratpchandra3@gmail.com

## THE DEVELOPMENT OF TREATMENT OF BI AND AAD

BI with or without AAD were earlier considered as irreducible. Before the introduction of trans-oral excision of odontoid process, they were practically “untreatable” and foramen magnum decompression along with “*in situ*” fixation with contoured Steinmann pin’s and wires were considered as the only available option.<sup>[19-27]</sup> Rodgers *et al.*<sup>[28]</sup> reviewing the earlier retrospective analysis of occipito-cervical fusions found several neurological complications as a result of “*in situ*” fixations with only foramen magnum decompression without ventral decompression of the cervico-medullary junction. This subsequently led to the development of trans-oral decompression of odontoid process and C2 for irreducible BI and AAD.

However, trans-oral procedures are not without limitations and complications. They require a prolonged learning curve. Since it involves surgery from a potentially contaminated space, it is prone to develop infection. In addition, performing two surgeries (trans-oral followed by posterior instrumented fixation) prolongs the duration of anesthesia. Dickman *et al.*<sup>[43]</sup> reported that the complication rate of trans-oral surgery, even in experienced hands, being 9.4% (14 of 148 patients). Complications included cerebrospinal fluid leakage, wound dehiscence, wound infection, pneumonia, etc.; death also occurred in 2% of patients (3 of 148 patients). In addition, a trans-oral procedure and “*in situ*” fixation is non-physiological as it does not reduce the deformity but rather decompresses the spinal cord and stabilizes the deformity. To overcome this, Wang *et al.* have also suggested a trans-oral release of the ligaments around the odontoid process<sup>[29-31]</sup> as the first stage of the treatment, followed by a posterior instrumented fixation in a second surgery. Our institute has followed a standard policy of trans-oral excision of odontoid process followed by posterior instrumented fixation for nearly three decades.<sup>[32]</sup>

To overcome the limitations of this procedure, various authors started exploring the options of attempting to reduce the deformity in a single staged posterior approach. Sonntag was among the first surgeon to demonstrate reduction of BI in pediatric patients utilizing distraction and extension.<sup>[28]</sup> This along with the contribution from Menezes *et al.*<sup>[33,34]</sup> demonstrated that distraction may be performed safely and effectively in children to reduce BI. Goel and Shah<sup>[16,33-40]</sup> in his well-known work demonstrated that placement of spacer in the C1/C2 joint or between occipito C1 and C2 complex leads effective reduction of BI. He preferred to call this technique as cranio-vertebral junction (CVJ)

re-alignment. However, this technique consisted of movement in only a single axis i.e. in a vertical direction. While this effectively corrected the BI, it corrected AAD in only some instances. Correcting AAD was a challenge especially in those cases where the C1 was occipitalized and there was a severe BI upward and posteriorly.

To overcome this problem the concept of techniques involving specific intra-operative manipulations were devised. Jian *et al.*<sup>[18]</sup> introduced a concept of intra-operative distraction of BI with assimilated C1 arch, where a rod was connected to a C2 pedicular screw and occipital screw following which, distraction was performed reducing both BI and AAD. They achieved satisfactory results. However, the shortcoming of this procedure was that, it could provide distraction only as a method of reduction for both AAD and BI. AAD for its optimal reduction also requires a forward movement of dens when compared with BI, which requires only a vertical distraction. This is reflected in their results, where BI could be reduced in almost all patients, but the AAD could be reduced completely in only 85% of their cases. In addition, distraction only without a spacer placement, carries a risk of re-settling, which also was reflected in some of their cases.

Hsu *et al.*<sup>[17]</sup> overcame this shortcoming by describing a novel technique in two cases of acquired (one infection and other in metastasis) occipito-cervical instability. Here, apart from intra-operative occipito-cervical distraction, they also provided an extension of neck by applying compression between the upper occipital screw and another screw tightened more superiorly on the rod, which resulted in correction of AAD. This technique clearly demonstrated that while distraction corrects BI, extension while maintaining distraction results in correction of AAD.

The author devised a new technique called distraction, compression and extensive reduction (DCER) (see below). This technique is novel in the sense that while we first used spacers to distract the joint to correct the BI, the spacers were then used as a fulcrum over which simultaneous compression and extension was provided, which then corrected the AAD. Since the procedure involved movements of distraction, compression and extension, we named it as DCER. This is different from the technique described by Goel *et al.*<sup>[16,37,41]</sup> as their technique utilizes distraction only, which corrects BI, but may or may not reduce the AAD. While the range of movements performed in our technique were same as Hsu *et al.*<sup>[17]</sup> i.e. involving both distraction and extension, DCER uses first a spacer followed by extension using the spacer as a pivot. In Hsu’s technique, distraction was

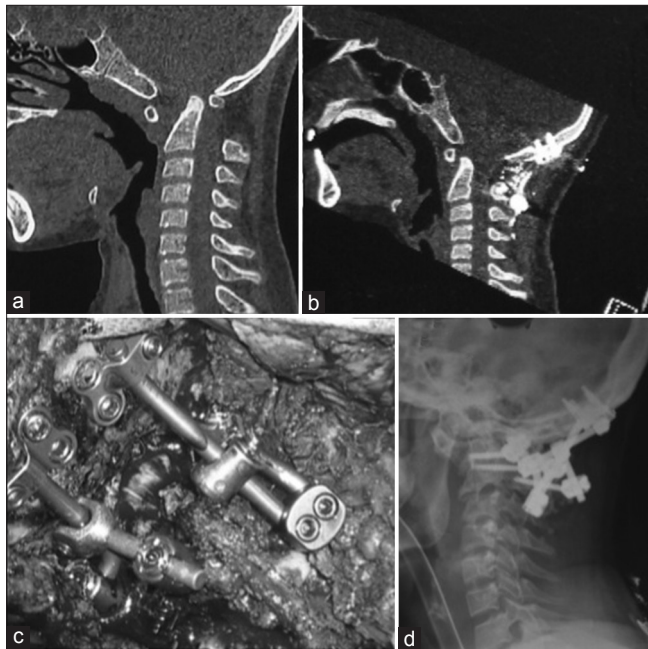performed without a spacer followed by extension that was provided by compressing the cranial screws. The latter technique while useful in acquired destructive pathologies of CVJ may be difficult in developmental anomalies with more rigid joints. In addition, resettling may occur over a period of time due attrition at the bone screw interface.

We have now performed DCER in over 100 patients with at least 6 months follow-up. We have noted mortality in two patients, both likely having developed delayed vertebral artery thrombosis. These were noted in the initial learning curve. However, manipulation of vertebral artery especially in the dominant side is to be performed with care as its partial injury can result in thrombosis or dissection. Using the technique of DCER, we were able to reduce the AAD completely in 94% cases and BI satisfactorily in all cases. We feel that this technique may be used satisfactorily in all cases of BI and AAD [Figures 1 and 2].

DCER is quite different from the procedure described by Goel *et al.* The differences are enumerated below.<sup>[42]</sup>

#### Producing an additional movement of extension

Providing active intraoperative compression between the C2 trans-laminar screw heads and a temporary screw placed on the occiput provides an additional movement of extension, which is important to correct AAD. Distraction alone may correct the AAD to a great extent



**Figure 1:** (a) Severe atlanto-axial dislocation with basilar invagination; (b) following reduction after the author's technique (distraction, compression and extensive Reduction); (c and d) Utilisation of 2 pars screws along with 2 laminar screws to enhance the strength of the cervical screws

in the majority of cases; however, complete correction does not occur, especially with severe AAD associated with BI [Figure 1a and b]. Hence it becomes essential to provide this additional axis of motion to correct AAD. Such intraoperative maneuvers were not described the Goel procedure.

#### Occipital purchase and C2 trans-laminar screws

None of the cases described by Dr. Goel ever had an occipital or a C2 trans-laminar screw purchase. The reason we preferred this kind of bony access is that both of these accesses provide the longest possible distance from the center of the spacer, which now acts as the fulcrum of a type II pivot joint. This significantly reduces the amount of strain at the screw/bone interface as per the law of levers.

Thus, such a situation provides an opportunity to perform active compression and extension to reduce AAD after the BI has been corrected by distraction. Before performing this procedure on patients, we undertook a short study in about five cadavers (unpublished) in which an active compression was attempted with an occipital and C2 pars screw. In all cases, the C2 screws sheared away from bone in a lateral direction because of the immense force being applied at the screw/bone interface as a result of the short lever length (the entry point of screw at C2 pars is just a few millimeters from the fulcrum, unlike the entry point at the C2 lamina, which was usually around 23-26 mm). Thus, the C2 lamina was the only entry point, which was farthest away from the fulcrum.

#### Concerns about the strength of C2 trans-laminar screw

The concern about the strength of C2 trans-laminar is relevant, even though studies have shown almost equal pullout strengths of trans-laminar screws compared with pars or pedicle screws. We would be cautious of using this screw access in geriatric patients and those with osteoporosis. In such cases or other cases in which we feel that a C2 trans-laminar screw alone may not provide optimal strength, we prefer to take an additional access from the C3 lateral mass. We also place two additional screws through the pars and connect them to the trans-laminar screws using connectors and dominos [Figure 1]. We also feel that the use of a spacer ventrally helps in the transmission of the weight, thus reducing the stress burden on the C2 trans-laminar screw, unlike a situation in which the latter may be used alone, when the stress on the screw bone interface would be much higher. In addition, the most common indication for the use of a trans-laminar screw in our setting is a developmental CVJ anomaly. In most of these cases, the C1 arch is usually fused with occiput and the lamina of the C2 is quite bulky, which provides a very good purchase for a screw.

In an ongoing study (unpublished), we found a significant reduction in morbidity, hospital stay (mean,  $4.2 \pm 2.3$  compared with  $9.4 \pm 3.4$  days;  $P < 0.01$ ) and blood loss (mean:  $230 \pm 94$  compared with  $340 \pm 120$  mL;  $P < 0.01$ ) compared with an equal number of age- and sex-matched patients who underwent a trans-oral procedure by the same author followed by posterior instrumented fusion.<sup>[42]</sup> We of course advice a hard Philadelphia collar in all patients until a good bone fusion is demonstrated.

### CURRENT INDICATIONS OF TRANS-ORAL PROCEDURES

Following the above discussion, our experience and that from others clearly indicate that a single posterior only approach is sufficient for most of the pathologies with BI with or without AAD. The definition of “reducible” versus

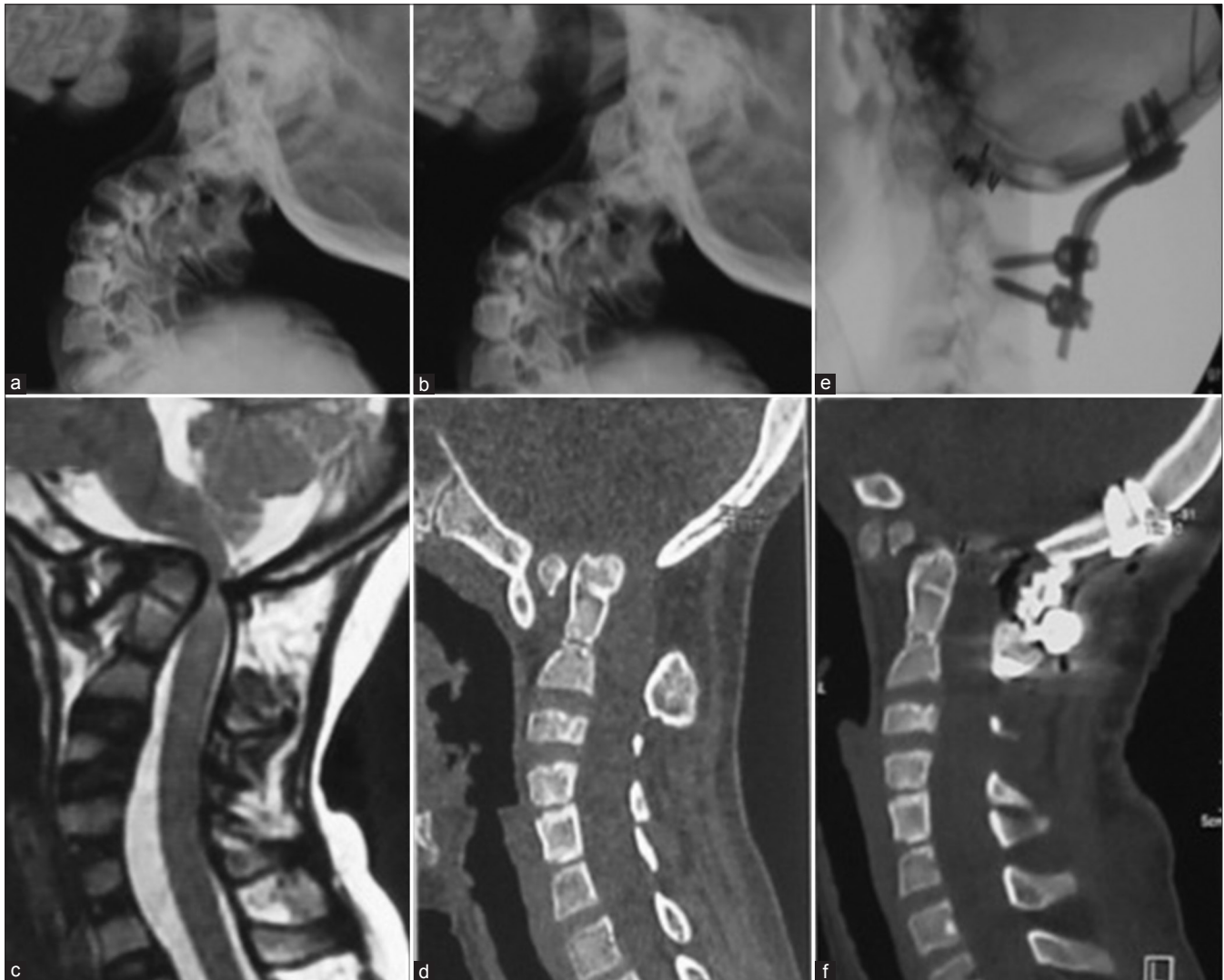“irreducible” becomes blurred in the conventional sense. Joint manipulation, distraction and specific intra-operative maneuvers DCER reduces BI and also corrects AAD in over 94% of cases. However, a trans-oral procedure may be still required for some indications. These include [Figure 3].

#### Very severe BI

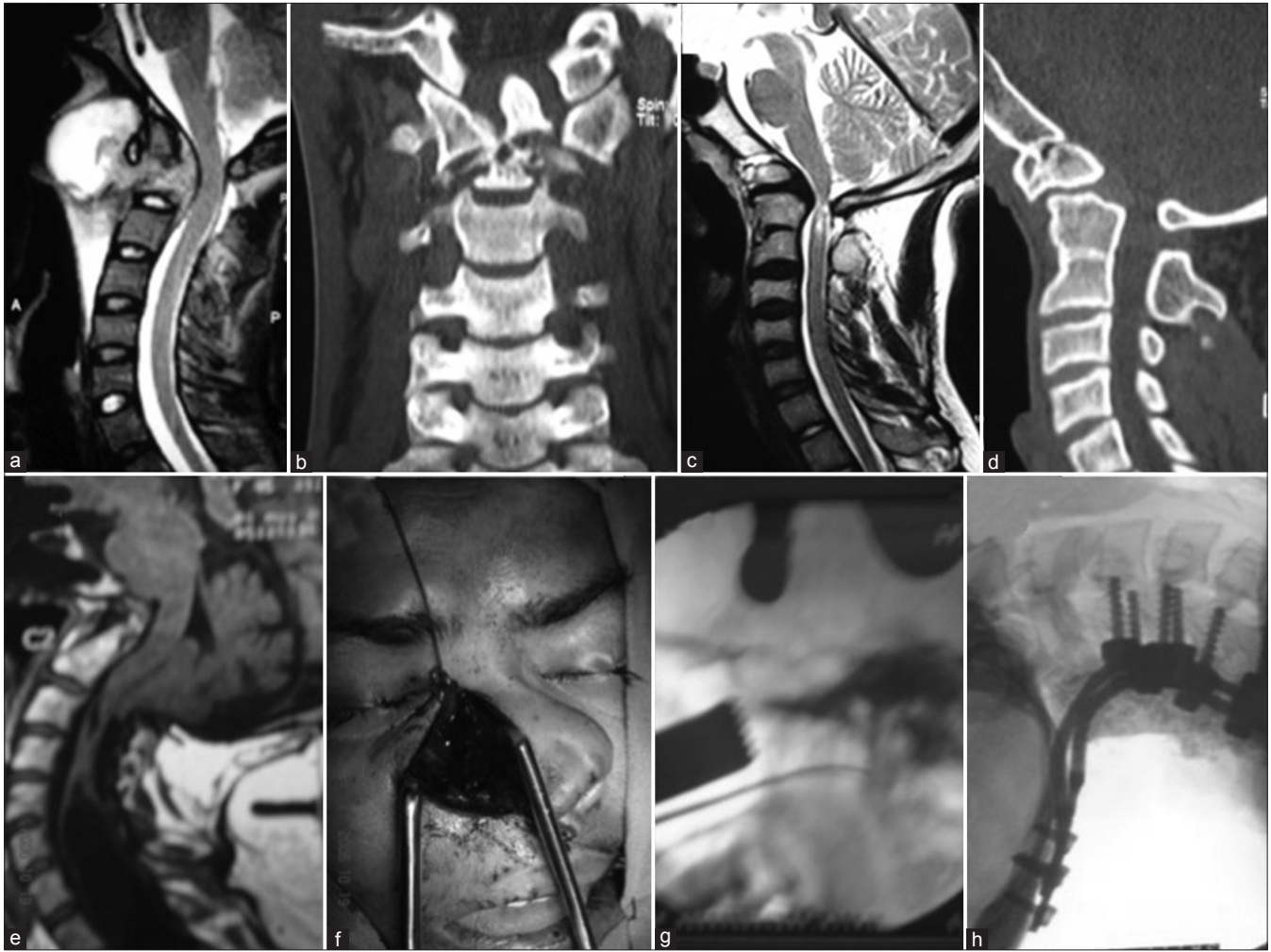
In certain cases, associated with Paget’s disease or achondroplasia, there may be presence of severe BI. These cases may require a skull base approach to remove the odontoid process (e.g. Le Fort maxillotomy or a paranasal approach).

#### Clival segmentation anomalies

There are certain clival segmentation anomalies, where the entire clival-dens complex is bulky; hence a trans-oral procedure may be the only option.



**Figure 2:** (a-d) Patient with basilar invagination (BI) and atlanto-axial dislocation with a small os-odontoideum. Following the author’s technique distraction, compression and extensive reduction, the dens has shifted inferiorly below the os-odontoideum correcting the BI and also has moved anteriorly also correcting the AD (e and f)



**Figure 3:** Few indications for the current role of a trans oral procedure followed by posterior stabilisation: (a and b) Tuberculosis of cranio vertebral junction with both ventral and dorsal involvement. (c) Clival segmentation anomaly with ventral compression due to expanded odontoid and clivus complex (MRI) (d) CT of same patient as in (c). (e) Severe basilar invagination with chiari with a holocord syringomyelia, which required a paranasal approach (f) For performing the trans oral excision of the dens (g) and long segment posterior fixation (h)

### Infective pathologies like tuberculosis

In such cases, there may be circumferential destruction of the CVJ complex; hence a trans-oral decompression followed by posterior decompression along with an instrumented fixation will be required.

### Tumors

Of course tumors such as chordomas, chondromas etc., require a trans-oral decompression and instrumented fixation.

## CONCLUSION

We are currently in the era where it is being realized that specific intra-operative manipulations may be performed, which may reduce both BI and AAD. While a trans-oral procedure may be avoided in a majority of cases, it is still to be remembered that it may be still required for certain indications. A neurosurgeon/spine surgeon trained to

operate this area must still keep trans-oral procedure as one of the options for surgery and it should not be discarded completely.

## REFERENCES

1. Chandra PS, Kumar A, Chauhan A, Ansari A, Mishra NK, Sharma BS. Distraction, compression, and extension reduction of basilar invagination and atlantoaxial dislocation: A novel pilot technique. *Neurosurgery* 2013;72:1040-53.
2. Ding X, Abumi K, Ito M, Sudo H, Takahata M, Nagahama K, *et al.* A retrospective study of congenital osseous anomalies at the craniocervical junction treated by occipitocervical plate-rod systems. *Eur Spine J* 2012;21:1580-9.
3. Fenoy AJ, Menezes AH, Fenoy KA. Craniocervical junction fusions in patients with hindbrain herniation and syringohydromyelia. *J Neurosurg Spine* 2008;9:1-9.
4. Furlan JC, Kalsi-Ryan S, Kailaya-Vasan A, Massicotte EM, Fehlings MG. Functional and clinical outcomes following surgical treatment in patients with cervical spondylotic myelopathy: A prospective study of 81 cases. *J Neurosurg Spine* 2011;14:348-55.
5. Goel A. Treatment of basilar invagination by atlantoaxial joint distraction and direct lateral mass fixation. *J Neurosurg Spine* 2004;1:281-6.

6. Goel A. Progressive basilar invagination after transoral odontoidectomy: Treatment by atlantoaxial facet distraction and craniovertebral realignment. *Spine (Phila Pa 1976)* 2005;30:E551-5.
7. Goel A. Double insurance atlantoaxial fixation. *Surg Neurol* 2007;67:135-9.
8. Landeiro JA, Boechat S, Christoph Dde H, Gonçalves MB, Castro Id, Lapenta MA, *et al*. Transoral approach to the craniovertebral junction. *Arq Neuropsiquiatr* 2007;65:1166-71.
9. Menezes AH. Complications of surgery at the craniovertebral junction – Avoidance and management. *Pediatr Neurosurg* 1991;17:254-66.
10. Menezes AH. Craniovertebral junction anomalies: Diagnosis and management. *Semin Pediatr Neurol* 1997;4:209-23.
11. Menezes AH. Pathogenesis, dynamics, and management of os odontoides. *Neurosurg Focus* 1999;6:e2.
12. Menezes AH. Craniovertebral junction neoplasms in the pediatric population. *Childs Nerv Syst* 2008;24:1173-86.
13. Menezes AH. Craniocervical developmental anatomy and its implications. *Childs Nerv Syst* 2008;24:1109-22.
14. Chandra PS. Irreducible basilar invagination and atlanto-axial dislocation: Are they really “irreducible”? *Indian J Neurosurg* 2012;1:101-4.
15. Goel A. Basilar invagination, Chiari malformation, syringomyelia: A review. *Neurol India* 2009;57:235-46.
16. Goel A, Shah A. Atlantoaxial joint distraction as a treatment for basilar invagination: A report of an experience with 11 cases. *Neurol India* 2008;56:144-50.
17. Hsu W, Zaidi HA, Suk I, Gokaslan ZL, Wolinsky JP. A new technique for intraoperative reduction of occipitocervical instability. *Neurosurgery* 2010;66:319-23.
18. Jian FZ, Chen Z, Wrede KH, Samii M, Ling F. Direct posterior reduction and fixation for the treatment of basilar invagination with atlantoaxial dislocation. *Neurosurgery* 2010;66:678-87.
19. Wackenheim A. *Roentgen Diagnosis of the Cranio-Vertebral Region*. New York, NY: Springer-Verlag, 1974.
20. Allison FG, Penner DW. Paget’s disease of skull with basilar invagination (platybasia) and internal hydrocephalus. *Can Med Assoc J* 1951;65:476-8.
21. Dastur DK, Wadia NH, Desai AD, Sinh G. Medullospinal compression due to atlanto-axial dislocation and sudden haematomyelia during decompression. Pathology, pathogenesis and clinical correlations. *Brain* 1965;88:897-924.
22. El-Khoury GY, Wener MH, Menezes AH, Dolan KD, Kathol ME. Cranial settling in rheumatoid arthritis. *Radiology* 1980;137:637-42.
23. Goodbody RA, Roberts LV. Basilar invagination in Paget’s disease. *Lancet* 1950;1:809-11.
24. Mateos Gomez JH, Dorfsman figueroa J. Basilar invagination. *Rev Med Hosp Gen (Mex)* 1961;24:181-5.
25. Mcgreger M. The significance of certain measurements of the skull in the diagnosis of basilar impression. *Br J Radiol* 1948;21:171-81.
26. Mcrae DL, Barnum AS. Occipitalization of the atlas. *Am J Roentgenol Radium Ther Nucl Med* 1953;70:23-46.
27. Wadia NH. Myelopathy complicating congenital atlanto-axial dislocation. (A study of 28 cases). *Brain* 1967;90:449-72.
28. Rodgers WB, Coran DL, Emans JB, Hresko MT, Hall JE. Occipitocervical fusions in children. Retrospective analysis and technical considerations. *Clin Orthop Relat Res* 1999;364:125-33.
29. Wang C, Yan M, Zhou HT, Wang SL, Dang GT. Open reduction of irreducible atlantoaxial dislocation by transoral anterior atlantoaxial release and posterior internal fixation. *Spine (Phila Pa 1976)* 2006;31:E306-13.
30. Wang J, Vokshoor A, Kim S, Elton S, Kosnik E, Bartkowski H. Pediatric atlantoaxial instability: Management with screw fixation. *Pediatr Neurosurg* 1999;30:70-8.
31. Wang T, Zeng B, Xu J. Transoral reduction of irreducible posteriorly displaced odontoid fracture. *Eur Spine J* 2011;20 Suppl 2:S227-30.
32. Yerramneni VK, Chandra PS, Kale SS, Lythalling RK, Mahapatra AK. A 6-year experience of 100 cases of pediatric bony craniovertebral junction abnormalities: Treatment and outcomes. *Pediatr Neurosurg* 2011;47:45-50.
33. Menezes AH, Traynelis VC. Anatomy and biomechanics of normal craniovertebral junction (a) and biomechanics of stabilization (b). *Childs Nerv Syst* 2008;24:1091-100.
34. Menezes AH, Traynelis VC, Gantz BJ. Surgical approaches to the craniovertebral junction. *Clin Neurosurg* 1994;41:187-203.
35. Goel A, Pareikh S, Sharma P. Atlantoaxial joint distraction for treatment of basilar invagination secondary to rheumatoid arthritis. *Neurol India* 2005;53:238-40.
36. Goel A, Shah A. Reversal of longstanding musculoskeletal changes in basilar invagination after surgical decompression and stabilization. *J Neurosurg Spine* 2009;10:220-7.
37. Goel A, Shah A, Gupta SR. Craniovertebral instability due to degenerative osteoarthritis of the atlantoaxial joints: Analysis of the management of 108 cases. *J Neurosurg Spine* 2010;12:592-601.
38. Goel A, Shah A, Rajan S. Vertical mobile and reducible atlantoaxial dislocation. Clinical article. *J Neurosurg Spine* 2009;11:9-14.
39. Goel A, Sharma P. Craniovertebral realignment for basilar invagination and atlantoaxial dislocation secondary to rheumatoid arthritis. *Neurol India* 2004;52:338-41.
40. Goel A, Sharma P. Craniovertebral junction realignment for the treatment of basilar invagination with syringomyelia: Preliminary report of 12 cases. *Neurol Med Chir (Tokyo)* 2005;45:512-7.
41. Goel A, Shah A. Vertical atlantoaxial dislocation as a cause of failure of midline fixation. *J Clin Neurosci* 2010;17:1345-6.
42. Chandra PS. Reply to the Comment on the Article ‘Distraction, Compression, and Extension Reduction of Basilar Invagination and Atlantoaxial Dislocation: A Novel Pilot Technique’ *Neurosurgery* 2013 (Epub ahead of print).
43. Dickman CA, Locantoro J, Fessler RG. The influence of transoral odontoid resection on stability of the craniovertebral junction. *Journal of neurosurgery* 1992;77:525-30.

**How to cite this article:** Chandra PS. Controversies in neurosurgery: Irreducible basilar invagination and atlanto-axial dislocation: A trans-oral procedure may be avoided in a majority, but still may be required in some cases. *Indian J Neurosurg* 2013;2:234-9.

**Source of Support:** Nil, **Conflict of Interest:** None declared.