Neurothekeoma of petrous apex: A rare entity

Zarina Abdul Assis, Sunitha P. Kumaran, Nandita Ghosal[1], Saikiran Narayanam[2], Sanjaya Viswamitra

Departments of Radiology, [1]Pathology and [2]Neurosurgery, Sri Sathya Sai Institute of Higher Medical Sciences, Whitefield, Bangalore, Karnataka, India

ABSTRACT

Intraosseous nerve sheath tumors are very rare tumors accounting for lesser than 0.2% of primary bone tumors. We present an 18-year-old female who presented with left facial paresis for the last 1 year. Magnetic resonance imaging (MRI) demonstrated expansile, multiseptated, enhancing bony lesion in the left petrous apex. There was also abnormal enhancement of the 7-8th nerve complex within the internal auditory canal. Tumor was excised by subtemporal extradural approach. The lesion was diagnosed as intraosseous neurothekeoma on histopathology. This is an extremely rare tumor and its MRI appearance in this location is being described for the first time in literature.

Key words: Expansile, lytic, intraosseous, neurothekeoma, petrous apex

INTRODUCTION

Petrous apex lesions can be categorized as non-neoplastic, primary neoplastic and secondary neoplastic lesions. Primary neoplastic lesions of the petrous apex are relatively rare. Intraosseous nerve sheath tumor of the petrous apex is extremely rare. Imaging of only two cases of petrous apex intraosseous schwannoma have been reported in literature in the past.[1,2] We hereby present the magnetic resonance imaging (MRI) features of the first case of petrous apex intraosseous neurothekeoma (i.e., schwannoma with predominant myxomatous degeneration). Our case also showed that abnormal enhancement of the ipsilateral 7th and 8th cranial nerves, which to the best of our knowledge, is also being reported for the 1st time in the literature.

CASE REPORT

An 18-year-old female patient presented with the history of deviation of face to right side and inability to close the left eye for 1 year. Examination revealed left lower motor neuron facial paresis. Rest of the neurological and clinical examination was normal.

Access this article online	
Quick Response Code:	Website: www.ijns.in
	DOI: 10.4103/2277-9167.118135

MRI brain demonstrated a well-defined, lobulated, multicystic, extra-axial bony lesion in the region of the petrous apex. The lesion showed predominant T2 hyperintensity, partially inverting on fluid-attenuated inversion-recovery (FLAIR) sequences [Figure 1a and c]. On T1-weighted sequence, the lesion showed hypointense signals [Figure 1b]. There was no evidence of restriction of diffusion. The cortex of the petrous bone appeared to be thinned out, but intact. Posteriorly, the lesion was seen to abut the cochlea. The semicircular canals were not involved. The middle ear structures and mastoid air cells appeared normal. Anteriorly, the lesion was extending into the Meckel's cave. On post-contrast study, the lesion showed heterogeneous enhancement [Figure 1d]. Another peculiar finding on post-contrast study was abnormal enhancement of the left 7th and 8th nerve complex within the internal auditory canal (IAC) [Figure 2]. The left internal carotid artery was displaced medially by the lesion, without any luminal compromise. Based on the MRI findings, differential diagnosis of chondromyxoid fibroma, giant cell tumor, aneurysmal bone cyst and chondrosarcoma were considered.

Lesion was excised by subtemporal extradural approach. The lesion was completely extradural destroying the petrous part of left temporal bone. Near total excision of the lesion was performed except for the part diffusely involving the petrous apex. Post-operative course was uneventful except for persisting 7th nerve paresis.

Address for correspondence: Dr. Zarina Abdul Assis,
Department of Radiology, Sri Sathya Sai Institute of Higher Medical Sciences, EPIP Area, Whitefield, Bangalore - 560 066, Karnataka, India.
E-mail: drzarinaaziz@gmail.com

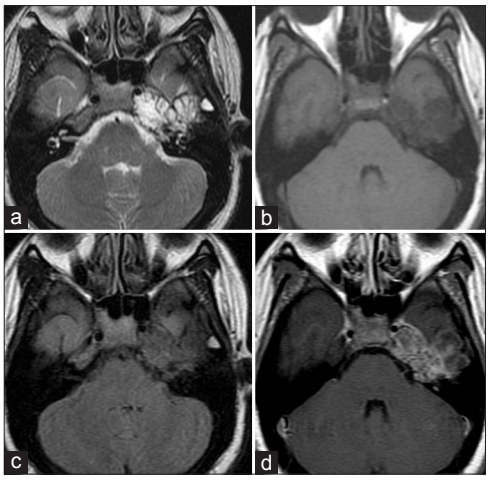

Figure 1: (a) T2-weighted (w) axial image showing a well-defined, multiseptated hyperintense expansile lesion in the left petrous apex. (b) T1-W axial showing that the lesion is hypointense on T1. (c) Fluid-attenuated inversion-recovery axial image showing partial suppression of signals. (d) Post-contrast T1-W image showing heterogeneous enhancement

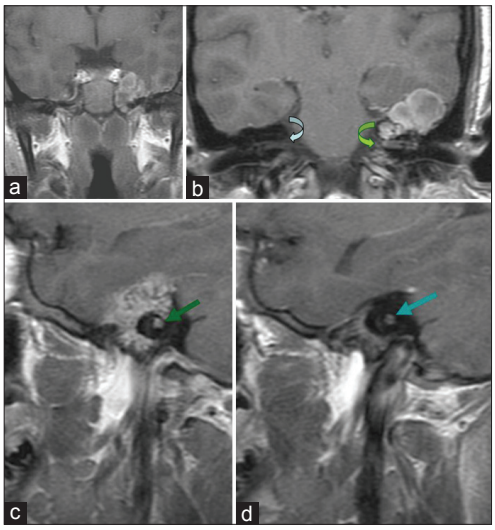

Figure 2: (a) Coronal post-contrast T1-weighted (w) image showing involvement of the left Meckel's cave. (b) Coronal post-contrast T1-W image showing subtle abnormal enhancement of the left 7-8th cranial nerve complex (shown by green curved arrow) as compared to the normal non-enhancing right sided 7-8th nerve complex (shown by blue curved arrow). (c) Sagittal post-contrast T1-W image showing enhancing 7-8th nerves within the internal acoustic canal (shown by straight green arrow). (d) Post-contrast T1-W image showing non-enhancing 7-8th nerves within the contralateral internal auditory canal (shown by blue straight arrow)

Histopathology sections examined from the lesion showed a tumor composed of prominent myxoid extracellular matrix with scattered spindle shaped cells, some showing serpentine nuclei and wispy cytoplasmic processes. Interspersed thin capillaries were seen; however, no thick walled vessels were seen. No chondroid matrix was seen. Immunohistochemistry for S-100 protein was positive in the tumor cells [Figure 3]. On the overall histomorphology, a diagnosis of intraosseous neurothekeoma was rendered.

DISCUSSION

Expansile lytic lesions of the petrous apex are commonly encountered in day-to-day clinical practice. Primary neoplasms of the petrous apex are rare and include eosinophilic granuloma, chondroma, chondrosarcoma, fibrous dysplasia, chondromyxoid fibroma, chordoma etc., most of which would present as expansile lytic lesions.[3]

Diagnostic imaging with computed tomography (CT) and MRI is highly useful in characterization of these lesions and usually provide a definitive diagnosis prior to histological examination.[3,4] Intraosseous nerve sheath tumors are rare benign neoplasms accounting for < 0.2% of primary bone tumors.[5] Schwannomas usually arise from sensory nerves.[6] Intraosseous schwannoma is thought to originate from schwann cells of the paravasal nerves that travel with the nutrient arteries.[7] There is low density of sensory nerves within bone, accounting for the rarity of intraosseous schwannomas.[8] However, it has been observed that there is a relatively high density of sensory nerve fibers in the head and neck regions.[9] Mandible is the most common site reported.[10] Other less common reported sites include humerus,[11] femur,[12] tibia,[13] ulna,[14] vertebral bodies,[15] rib and sacrum.[5] Primary intraosseous schwannoma in the petrous apex is believed to arise from the deep petrosal nerve of the periarterial carotid plexus.[16]

A review of the literature revealed only two cases of primary petrous apex intraossoeus schwannomas reported in the past by Solodnik *et al.*[1] in 1986 and Goiney *et al.*[2] in 2011. Solodnik *et al.* described only the CT findings. Goiney *et al.* described both CT and MRI findings in a 48-year-old female who presented with headache and decreased sensation on the left side of the face, which underwent gross total excision with subtemporal approach. They concluded that intraosseous schwannoma should be considered as differential diagnosis in case of a T2 hyperintense, T1 isointense, expansile, minimally erosive bony lesion showing solid homogeneous enhancement. There was no post-operative neurological deficit in the patient as in our case.

Neurothekeoma is nothing but a benign nerve sheath tumor with extensive myxoid degeneration that commonly arises from small cutaneous nerves and has a predilection for the head, neck and shoulders.[17] Until date only four cases of intracranial neurothekeomas (all extraosseous) have been reported, located in the prepontine cistern,[18] posterior fossa,[19] parasellar region[20] and deep white matter in the middle cranial fossa.[21] All these cases showed predominant T1 hypointensity and T2 hyperintensity with heterogeneous

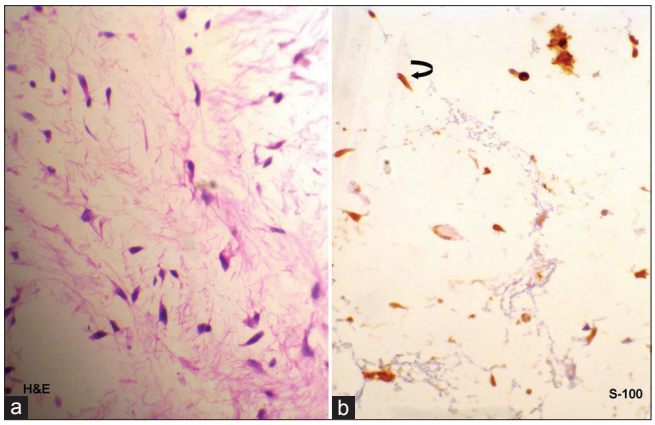

Figure 3: Paraffin section of neurothekeoma showing (a) spindle shaped cells dispersed in myxoid background with wispy cytoplasmic projections (H and E, ×400) and (b) immunopositivity for S-100 protein (curved arrow) (Avidin Biotin complex immunoperoxidase, ×400)

post-contrast enhancement. There was no mention of the adjacent cranial nerve enhancement in any of these reports.

We report the MRI features of the first case of intracranial intraosseous neurothekeoma. Our case showed a similar pattern of imaging findings as the previously reported extraosseous neurothekeomas, with T1 hypointense and T2 hyperintense signals and heterogeneous post-contrast enhancement. However, our case showed a multicystic-septated appearance, which is not described in earlier cases. Furthermore, the presence of associated ipsilateral 7th and 8th cranial nerves enhancement observed in our case is a new finding. Reason for this type of nerve enhancement is not clear. The association between the tumor and cranial nerve enhancement may be incidental. However, we postulate that this pattern of enhancement could probably suggest reactive inflammatory changes in the parent nerve (in this case the facial nerve) or retrograde spread of the tumor along the neural axis (less likely as it is a benign entity) or presence of multiple nerve sheath tumors.

Although no specific pathognomic MRI feature of intraosseous neurothekeoma were seen, which can help to differentiate this condition from others; however, expansile lytic, heterogeneously enhancing cystic bony lesion along with enhancement of the adjacent cranial nerves should likely suggest the possibility.

Complete surgical excision or curettage is the treatment of choice for intraosseousnerve sheath with less recurrence rates.[15] Near total excision of the lesion was performed in the present case without any additional morbidity.

CONCLUSION

Intraosseous neurothekeoma is an extremely rare entity. It can be considered in the differential diagnosis for petrous apex expansile lytic lesions. It has non-specific MRI features. Associated 7th and 8th cranial nerve enhancement in the IAC could suggest the probable diagnosis.

REFERENCES

1. Solodnik P, Som PM, Shugar JM, Sachdev VP, Sacher M, Lanzieri CF, *et al*. Intraosseous petrous apex neuroma: CT findings. J Comput Assist Tomogr 1986;10:1027-9.
2. Goiney C, Bhatia R, Auerbach K, Norenberg M, Morcos J. Intraosseous schwannoma of the petrous apex. J Radiol Case Rep 2011;5:8-16.
3. Isaacson B, Kutz JW, Roland PS. Lesions of the petrous apex: Diagnosis and management. Otolaryngol Clin North Am 2007;40:479-519, viii.
4. Razek AA, Huang BY. Lesions of the petrous apex: Classification and findings at CT and MR imaging. Radiographics 2012;32:151-73.
5. Fawcett KJ, Dahlin DC. Neurilemmoma of bone. Am J Clin Pathol 1967;47:759-66.
6. Goyal R, Saikia UN, Vashishta RK, Gulati G, Sharma RK. Intraosseous schwannoma of the frontal bone. Orthopedics 2008;31:281.
7. Flügel M, Lentzen B, Geldmacher J. Intraosseous neurinoma. Handchirurgie 1977;9:3-5.
8. de la Monte SM, Dorfman HD, Chandra R, Malawer M. Intraosseous schwannoma: Histologic features, ultrastructure, and review of the literature. Hum Pathol 1984;15:551-8.
9. Samter TG, Vellios F, Shafer WG. Neurilemmona of bone. Report of 3 cases with a review of the literature. Radiology 1960;75:215-22.
10. Agha FP, Lilienfeld RM. Roentgen features of osseous neurilemmoma. Radiology 1972;102:325-6.
11. Gross P, Bailey FR, Jacox HW. Primary intra medullary neurofibroma of the humerus. Arch Pathol 1939;28:716-8.
12. Morrison MJ, Ivins JC. Case report. Skeletal Radiol 1978;2:177.
13. Gordon EJ. Solitary intraosseous neurilemmoma of the tibia: Review of intraosseous neurilemmoma and neurofibroma. Clin Orthop Relat Res 1976;117:271-82.
14. Peers JH. Primary intramedullary neurogenic sarcoma of the ulna: Report of a case. Am J Pathol 1934;10:811-20.3.
15. Choudry Q, Younis F, Smith RB. Intraosseous schwannoma of D12 thoracic vertebra: Diagnosis and surgical management with 5-year follow-up. Eur Spine J 2007;16 Suppl 3:283-6.
16. Horn KL, Hankinson HL, Nissen AJ, McDaniel SL. Primary schwannoma of the petrous apex. Skull Base Surg 1995;5:261-8.
17. Vered M, Fridman E, Carpenter WM, Buchner A. Classic neurothekeoma (nerve sheath myxoma) and cellular neurothekeoma of the oral mucosa: Immunohistochemical profiles. J Oral Pathol Med 2011;40:174-80.
18. Erdem Y, Koktekir E, Bayar MA, Yilmaz A, Caydere M. Characterization of an intracranial neurothekeoma: Case report. Turk Neurosurg 2012;22:109-12.
19. Alexandru D, Satyadev R, So W. Neurothekeoma in the posterior fossa: Case report and literature review. Perm J 2012;16:63-4.
20. Paulus W, Warmuth-Metz M, Sörensen N. Intracranial neurothekeoma (nerve-sheath myxoma). Case report. J Neurosurg 1993;79:280-2.
21. Pal L, Bansal K, Behari S, Sagar BC, Gupta RK, Gupta RK, *et al*. Intracranial neurothekeoma – A rare parenchymal nerve sheath myxoma of the middle cranial fossa. Clin Neuropathol 2002;21:47-51.

How to cite this article: Assis ZA, Kumaran SP, Ghosal N, Narayanam S, Viswamitra S. Neurothekeoma of petrous apex: A rare entity. Indian J Neurosurg 2013;2:210-2.
Source of Support: Nil, **Conflict of Interest:** None declared.