Single channel pial arteriovenous fistula with large venous varix

Sir,

Single-channel pial arteriovenous fistulas (AVFs) are rare vascular lesions of the brain accounting for 1.6% of all cerebral vascular malformations.[1] These lesions are composed of one or more direct arterial connection to a single venous channel without true intervening nidus and usually have associated venous varix. Only disconnection of the feeding artery is sufficient to decompress the lesion, because the varices might shrink and immediately lose the mass effect.[2] However, if the varices have a thick and hard calcified wall, only disconnection of the feeding artery might not reduce the volume. Here, we report a rare case of intracerebral giant venous varix with calcified walls and mass effect, secondary to a single-channel pial AVF in a 24-year-old man. Direct surgical flow disconnection followed by removal of large varix resulted in complete disappearance of pial AVF without complication.

A 24-year-old man presented with 6-year history of medically resistant generalized tonic-clonic seizure. On examination, he was found to be alert without any focal neurological deficit and had normal electroencephalogram. On computed tomography (CT) scan, a large round well-circumscribed vividly enhancing lesion with peripheral calcification was found in left frontal lobe [Figure 1a], causing mass effect with midline shift. A left frontal well-defined flow void of size 60 × 66 mm communicating with the superior sagittal sinus (SSS) through dilated cortical vein with feeder supply from left anterior cerebral artery (ACA) was observed in the cranial magnetic resonance imaging (MRI) with angiogram [Figure 2]. Cerebral CT angiography (CTA)

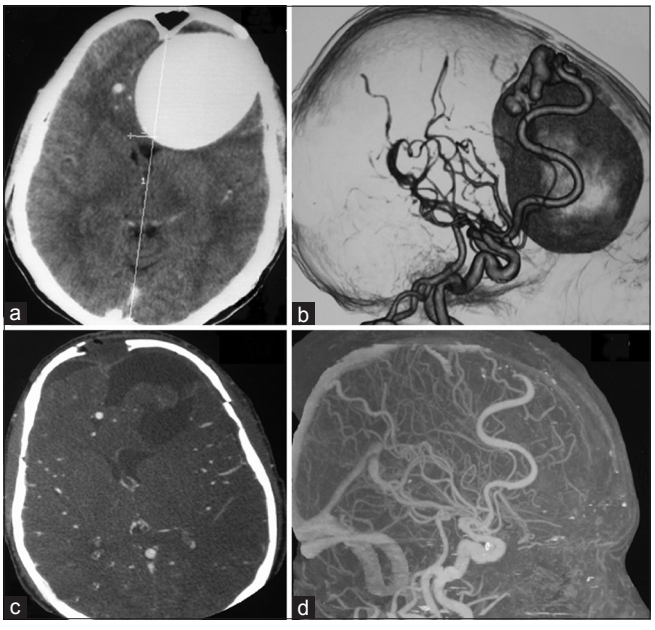

Figure 1: (a) CT scan of brain axial view showing left frontal well-circumscribed large vividly enhancing lesion with midline shift; (b) CTA demonstrates left frontal varix of size 6.5 cm in association with arteriovenous fistula supplied by the distal left anterior cerebral artery; (c) Postoperative CT scan and (d) CTA demonstrates complete obliteration of the AVF and reconstitution of the distal ACA

This document was downloaded for personal use only. Unauthorized distribution is strictly prohibited.

revealed left frontal AVF associated with large venous varix supplied by the distal left ACA [Figure 1b]. On left frontal craniotomy, a globular soft pinkish pulsatile varix (≈6 × 6 cm) was encountered superficially in left frontal lobe [Figure 3a and b] with dilated vein draining into the SSS. A fistulous connection between the mass and left ACA was noted which confirmed the presence of AVF. As the mass was posing significant mass effect with very hard and thick wall, simple occlusion of feeding artery did not resulted in disappearance of the AVF. So, total excision of the AVF mass along with the venous varix was performed [Figure 3c] after ligating the primary feeding artery. The patient had an unremarkable postoperative course with no fresh neurological deficit. Postoperative CTA demonstrated complete obliteration of the AVF and reconstitution of the distal ACA [Figure 1c and d]. On 6- month follow-up, the patient was found seizure-free on daily dose of 300 mg of phenytoin.

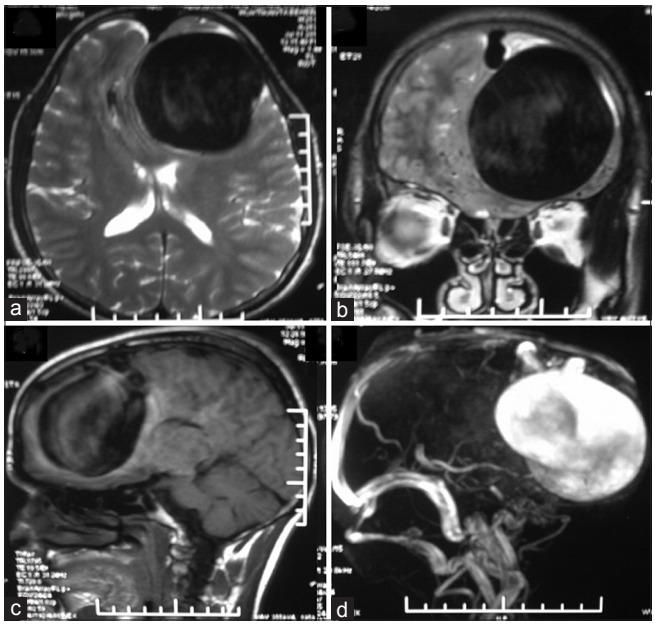

Figure 2: (a) T2 axial; (b) T2 coronal; (c) T1 sagittal and (d) MR angiogram; sequence of cerebral magnetic resonance imaging reveals a left frontal well defined flow void of size 60 × 66 mm communicating with the superior sagittal sinus through dilated cortical vein with feeder supply from left anterior cerebral artery

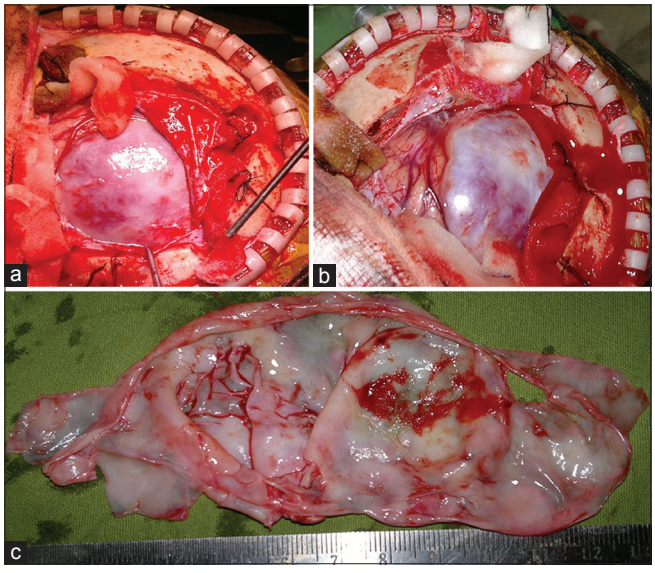

Figure 3: Intraoperative photograph showing the large venus varix (a and b) with cut open gross section of the variceal sac (c) after excision

Single-channel pial AVFs have recently been recognized as distinct vascular anomalies, different from cerebral arteriovenous malformations (AVMs).[3] They consist of one or more direct arterial connection to a single venous channel without true intervening nidus.[2] They differ from dural AVFs as they acquire feeders from pial or cortical arteries and are not located within the leaflets of the dura.[1,4] A fistulous communication between feeding artery and single draining vein can produce venous dilatation, varix, and even aneurysms by turbulent high flow.[2,5] Pial AVFs can result from trauma or may be congenital.[1,4] The pathophysiologic mechanisms giving rise to these lesions are still not clear.[6] Hoh *et al.*,[2] postulated that a misstep in embryological development of the cerebrovasculature could produce these lesions. Alternatively, abnormal angiogenesis and associated vascular growth factors and cytokine may play a role. Pial AVFs come to clinical attention with seizures, hemorrhage, headache, focal neurological deficit, symptoms of increased intracranial pressure, and intracranial bruit.[2,6] They can be diagnosed with cerebral CTA, especially three-dimensional (3D) angiograms. 3D angiograms can delineate complex angioarchitecture well because of its inherent capability of obtaining reconstruction images at any angles. Treatment strategies of pial AVFs are different than that of cerebral AVMs. Simple disconnection of arteriovenous shunting is considered enough in most cases, either by microsurgery or endovascular embolization, without resection of entire vascular malformation.[2] This strategy is based on the characteristic high-flow nature of pial AVFs produced by the communication between an arterial feeder and a single draining vein without an intervening tangle of vessels. Thus, removal of the varix is not necessary unless the malformation is associated with hematoma and mass effect. Obliteration of the fistula by an endovascular route, avoiding the risks associated with craniotomy, should always be considered especially when the lesion is deep-seated or the risk of neurological deficit with surgery is high.[2]

Intracerebral pial AVFs with large venous varix are rare vascular malformations that can be successfully managed surgically with good outcome. Though endovascular occlusion of feeding arteries offers a simple and safe option, direct surgical removal should be considered in

This document was downloaded for personal use only. Unauthorized distribution is strictly prohibited.

rare cases of superficially located intracerebral large pial AVF with calcified wall and mass effect.

Sudhansu Sekhar Mishra, Souvagya Panigrahi, Srikant Das, Deepak Kumar Parida

Department of Neurosurgery, S.C.B. Medical College and Hospital, Cuttack, Odisha, India.
E-mail: souvagya.ms@gmail.com

REFERENCES

1. Halbach VV, Higashida RT, Hieshima GB, Hardin CW, Dowd CF, Barnwell SL. Transarterial occlusion of solitary intracerebral arteriovenous fistulas. AJNR Am J Neuroradiol 1989; 10:747-52.
2. Hoh BL, Putman CM, Budzik RF, Ogilvy CS. Surgical and endovascular flow disconnection of intracranial pial single-channel arteriovenous fistulae. Neurosurgery 2001;49:1351-63.
3. Lasjaunias P, Manelfe C, Chiu M. Angiographic architecture of intracranial vascular malformations and fistulas: Pretherapeutic aspects. Neurosurg Rev 1986;9:253-63.
4. Santosh C, Teasdale E, Molyneux A. Spontaneous closure of an intracranial middle cerebral arteriovenous fistula. Neuroradiology 1991;33:65-6.
5. Viñuela F, Drake CG, Fox AJ, Pelz DM. Giant intracranial varices secondary to high-flow arteriovenous fistulae. J Neurosurg 1987;66:198-203.
6. Lv X, Li Y, Jiang C, Wu Z. Endovascular treatment of brain arteriovenous fistulas. AJNR Am J Neuroradiol 2009;30:851-6.

Access this article online

Quick Response Code:

Website: www.ijns.in

DOI: 10.4103/2277-9167.110228

This document was downloaded for personal use only. Unauthorized distribution is strictly prohibited.