

# Giant tentorial dural arteriovenous fistula treated by a combination of trans-arterial embolization and surgery

Türker Karancı, Hidayet Akdemir, Kubilay Aydın<sup>1</sup>

Department of Neurosurgery, Medicana International Istanbul Hospital, Beylikdüzü, <sup>1</sup>Department of Interventional Neuroradiology, Istanbul University, School of Medicine, Istanbul, Turkey

## ABSTRACT

Tentorial dural arteriovenous fistulae are uncommon lesions but can be life-threatening. A 34-year-old male presented with intractable headache, seizures, and visual disturbance. Three-dimensional computed tomography (CT) angiography and digital subtraction angiography demonstrated a right tentorial dural arteriovenous fistula supplied by both internal and external carotid systems and draining into a giant venous ampula. Transarterial embolization of the external carotid feeders with Onyx (TM, ev3, Irvine, CA) was carried out. Postembolization angiography revealed persistence of a portion of the fistula supplied by the temporo-occipital branch of right middle cerebral artery. The patient underwent right temporo-occipital craniotomy, division of the feeders and resection of the entire fistula and coagulation of the leptomeningeal arterialized veins. Complete elimination of the fistula was demonstrated by angiography. Postoperative recovery was uneventful; the patient did not develop any fresh neurologic deficits. We review the relevant literature and discuss the rationale for managing these lesions.

**Key words:** Surgery, tentorial dural arterio-venous fistula, trans-arterial embolization

## INTRODUCTION

Intracranial dural arterio-venous fistulas (DAVFs) account for 10–15% of all arterio-venous malformations (AVMs) of the brain. A DAVF may have a single or multiple fistulae with a nidus that lies entirely within the dura.<sup>[1,2]</sup> Tentorial DAVFs (TDAVF) comprise 4–8% of all DAVFs.<sup>[1-6]</sup> These lesions are located in the tentorium and are supplied by feeders arising from the meningo-hypophyseal trunk, middle meningeal artery, or occipital artery. The venous drainage is variable and depends on the location of the fistula. Some TDAVFs with leptomeningeal venous drainage or drainage into the vein of Galen may present with behavioral changes, hemorrhage, or progressive neurological deficits.<sup>[1]</sup> Some of these lesions may be located at the tentorial hiatus; this deep location, multiple sources of arterial input and large draining veins make them difficult lesions to manage.<sup>[1,4,7-11]</sup> We describe a patient with a

postsurgical TDAVF with superficial and deep venous drainage.

## CASE REPORT

A 34-year-old male presented with intractable headache, visual disturbance, and seizures. He had undergone craniotomy for evacuation of an intracerebral hematoma 7 years previously. Physical examination and neurologic assessment were unremarkable. Cranial computed tomography (CT) showed a hyperdense nodular lesion with surrounding gliosis in the right temporal lobe [Figure 1]. A diagnosis of arterio-venous malformation (AVM) was considered and CT angiography (CTA) and digital subtraction angiography (DSA) were performed [Figures 2 and 3]. DSA demonstrated a large tentorial DAVF fed by the right occipital, posterior auricular, superficial temporal, and middle meningeal branches of right external carotid artery (ECA) [Figure 3a]. The lesion was also supplied by the internal carotid system (ICA) through the temporo-occipital branch of right middle cerebral artery (MCA) [Figure 3b]. The cortical veins over the temporal lobe were dilated and arterialized. DSA also demonstrated a venous reflux into the fronto-parietal cortical veins due to increased venous pressure. A diagnosis of tentorial DAVF, Cognard type IV was made.<sup>[4]</sup>

Access this article online	
Quick Response Code:	Website: www.ijns.in
	DOI: 10.4103/2277-9167.102285

**Address for correspondence:** Dr. Türker Karancı,  
Department of Neurosurgery, Medicana International Istanbul Hospital, Beylikdüzü Cad, No. 3, Beylikdüzü, Istanbul, Turkey.  
E-mail: drkaranci@gmail.com

In the first stage, we planned to embolize the ECA feeders to the DAVF. Under general anesthesia, a 6F guiding catheter was inserted into the right common carotid artery. Through the guiding catheter, the right preauricular artery, occipital artery, and the parietal branch of superficial temporal artery were selectively catheterized using flow-directed microcatheters (Ultraflow, ev3, Irvine, CA). The portions of the DAVF deriving supply from these branches of the ECA were embolized by injecting a liquid embolic agent (ONYX, ev3, Irvine, CA). Postembolization DSA revealed residual fistula nidus being fed by the temporo-occipital branch of the right MCA [Figure 3c].

The neurologic status of the patient remained unchanged after the procedure. Two days after the embolization procedure, the patient underwent craniotomy and excision of the residual fistula. Surgery was performed with the patient positioned in the left lateral position, via a right posterior temporo-occipital approach. A fresh right temporo-occipital craniotomy was made, posterior to the previous craniotomy opening. All the dural feeders were coagulated and the dura surrounding the venous ampulla was excised. The MCA feeder to the fistula was clipped using a medium sized titanium Ligaclip and cut (Teleflex medical, RTP, NC, 27709 USA). The lax venous ampulla was then excised [Figure 4]. 3D-CTA [Figure 5] and DSA [Figure 6] on the 5<sup>th</sup> postoperative day demonstrated complete elimination of the DAVF.

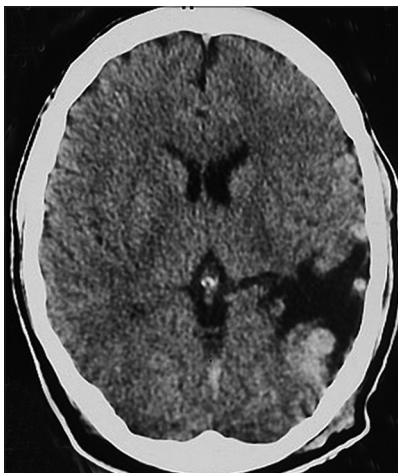## DISCUSSION

Tentorial DAVFs are an uncommon and angioarchitecturally distinct subset of dural AVFs.<sup>[4]</sup> TDAVFs often have exclusive leptomeningeal venous drainage without any efflux into the dural sinuses. This leads to chronic venous hypertension of the cortical veins

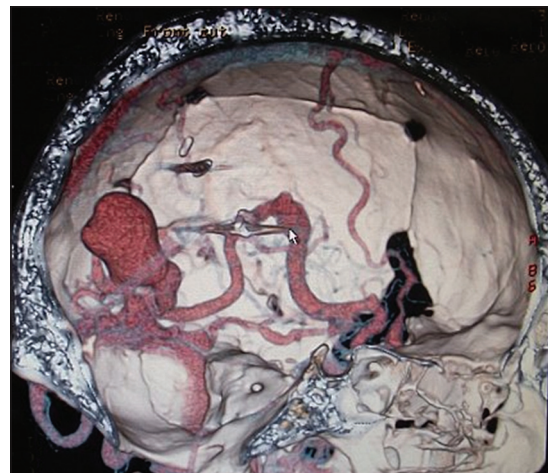and patients may present with progressive neurological deficits, behavioral changes (79–92%) or intracranial hemorrhage (ICH) (38–74%).<sup>[1,4,7,10,12-14]</sup> The TDAVF may have been responsible for the intracerebral hematoma that occurred in this patient 7 years ago. Another possibility is that the hematoma occurred due to unrelated causes and the surgery may have been responsible for creating the DAVF as has been described in literature.

Two angiographic classification systems are widely employed for TDAVFs. They were described by Borden–Shucart and Cognard. Both systems highlight the importance of cortical venous drainage in DAVFs.<sup>[4,12,15]</sup> In the present patient, there was a large venous varix that drained into the leptomeningeal veins. Lewis *et al.* reported that 57.4% of TDAVFs may be associated with a venous varix and up to 74% may present with ICH.<sup>[14]</sup> Borha *et al.*<sup>[16]</sup> reported one case of TDAVF with giant venous ampullae managed with a combination of embolization and surgery. The risk of spontaneous hemorrhage is estimated to be 1.8 % per year.<sup>[16]</sup> The source of hemorrhage is usually not the fistula itself but the distended leptomeningeal veins and venous varices.<sup>[6]</sup> Awad *et al.*<sup>[11]</sup> identified the presence of leptomeningeal venous drainage and the presence of venous varices as the most important risk factors for aggressive behavior. Aggressive lesions may present with progressive neurological deficit, behavioral changes, increased intracranial pressure, or spontaneous ICH.<sup>[11,16-20]</sup>

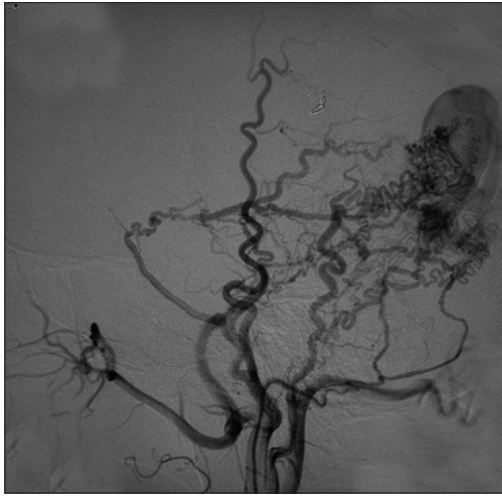
High-grade intracranial DAVFs usually have leptomeningeal venous drainage and early treatment is warranted. The fistulae with retrograde cortical venous drainage are associated with a high risk of early rebleed (35%), often within 2 weeks of the first hemorrhage.<sup>[21]</sup> Therefore, in those DAVFs that present with ICH and are found to have



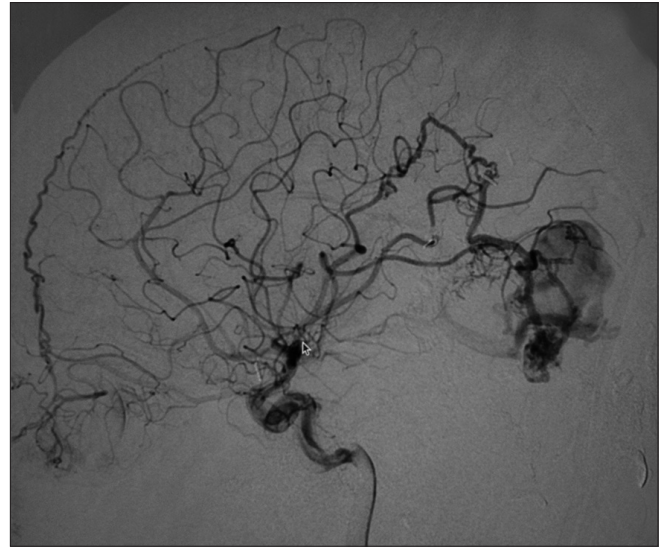
**Figure 1:** Tomography on admission, demonstrating an encephalomalacia with hyperdense lesion and artifact of multiple ligation clips



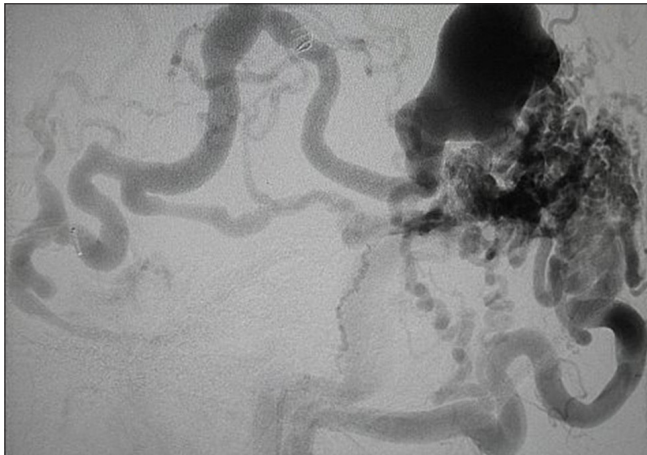
**Figure 2:** Station 3-D CT angiography, showing huge ampullae and leptomeningeal cortical draining veins of the fistula



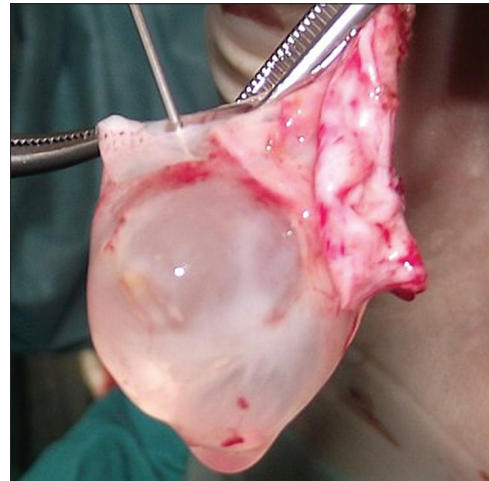
**Figure 3a:** Cerebral artery angiograms: Right external cerebral angiograms showing multiple arterial supplies to the fistula from right external carotid artery, occipital artery, posterior auricular, superficial temporal and middle meningeal branches



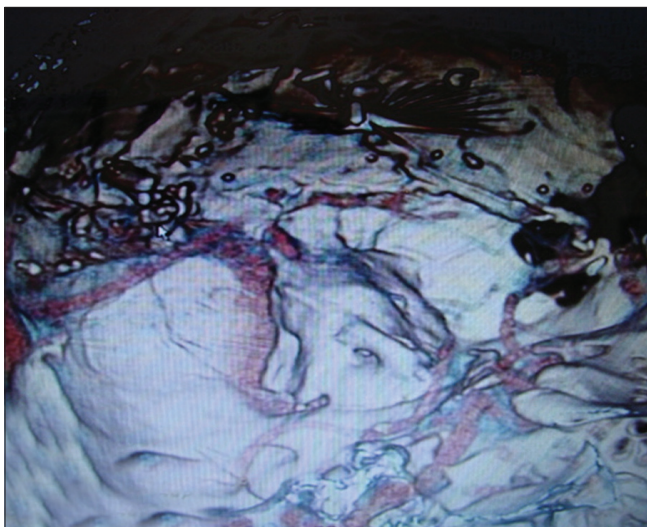
**Figure 3b:** Right internal carotid lateral view demonstrating arterial supply to the fistula from middle cerebral artery



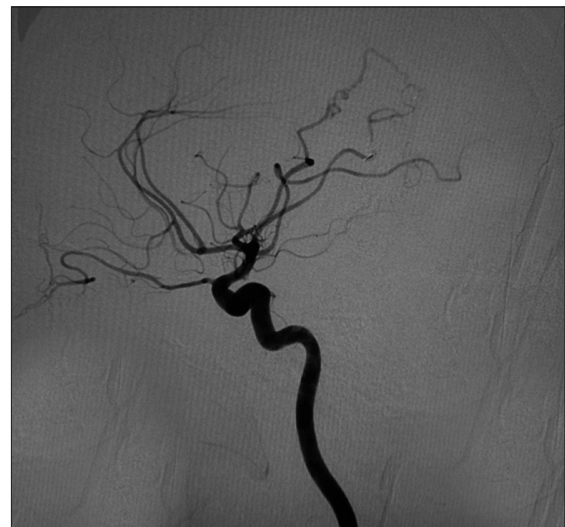**Figure 3c:** Post-embolisation cerebral angiograms showing residual fistulas and venous dilations



**Figure 4:** The surgical specimen of the venous ampulae of the fistula



**Figure 5:** Post-operative 3-D CT angiography showing complete and permanent occlusion of the fistula



**Figure 6:** Post-operative cerebral angiography showing complete and permanent occlusion of the fistula

retrograde leptomeningeal venous drainage, early treatment is an absolute imperative.<sup>[21]</sup>

The goal of treatment is permanent and complete obliteration of flow through the arteriovenous shunt. Several different treatment modalities have been proposed, including excision of the fistula, surgical skeletonization of the dural sinus, surgical interruption of leptomeningeal veins,<sup>[6,11,12,22,23]</sup> endovascular trans-arterial and/or transvenous embolization,<sup>[22,24-26]</sup> and radiation therapy (conventional or stereotactic radiosurgery).<sup>[14,18,27-29]</sup> Although endovascular therapy is currently considered the mainstay of treatment, complete obliteration may not always be achieved with endovascular techniques alone. The management paradigm for high grade DAVFs in general and TDAVFs in particular is a matter of controversy. Surgery may often be a component of the treatment strategy. This is because of the pattern of venous drainage of these lesions, which is into the cortical veins rather than into venous sinuses.<sup>[6,30,31]</sup> Where endovascular embolization fails to completely obliterate the DAVF, surgery is used as a complementary strategy. Transarterial embolization as a standalone therapy results in complete and permanent obliteration of the DAVFs in less of 50% of cases.<sup>[23]</sup> In many instances, recanalization of embolized vessels occurs.

Owing to the complexity of the angioarchitecture of the TDAVF in the present instance, endovascular occlusion of the ECA feeders was planned as the first stage in treatment. Trans-arterial embolization led to a significant reduction of the blood flow through the DAVF and was instrumental in reducing the turgor of the venous varix. A combination of endovascular embolization and microsurgical techniques is required to adequately manage most high grade tentorial DAVFs.

## CONCLUSION

Tentorial dural arteriovenous fistulas with leptomeningeal drainage and venous varices are rare lesions that have an aggressive behavior. Patients may present progressive neurological deficits. Treatment of these lesions is challenging and is best accomplished by a combination of endovascular and surgical approaches, depending on the anatomy of the lesion.

## REFERENCES

- Awad IA, Little JR, Akarawi WP, Ahl J. Intracranial dural arteriovenous malformation: Factors predisposing to an aggressive neurological course. *J Neurosurg* 1990;72:839-50.
- Zhou LF, Chen L, Song DL, Gu YX, Leng B. Tentorial dural arteriovenous fistulas. *Surg Neurol* 2007;67:472-82.
- Benndorf G, Schmidt S, Sollmann WP, Kroppenstedt SN. Tentorial dural arteriovenous fistula presenting with various visual symptoms related to anterior and posterior visual pathway, dysfunction. Case report. *J Neurosurg* 2003;53:222-6.
- Cognard C, Gobin YP, Pierot L, Bailly AL, Houdart E, Casasco A, et al. Cerebral dural arteriovenous fistulas: Clinical and angiographic correlation with a revised classification of venous drainage. *Radiology* 1995;194:671-80.
- Zhou LF, Chen L, Song DL, Gu YX, Leng B. Tentorial dural arteriovenous fistulas. *Surg Neurol* 2007;67:472-82.
- Liu JK, Dogan A, Ellegala DB, Carlson J, Nesbit GM, Barnwell SL, et al. The role of surgery for high-grade intracranial dural arteriovenous fistulas: Importance of obliteration of venous outflow. *J Neurosurg* 2008;110:913-20.
- Davis MA, Ter Brugge K, Willinsky RA, Wallace MC. The natural history and management of intracranial dural arteriovenous fistulae: Part 2, Aggressive lesions. *Int Neuroradiol* 1997;3:303-11.
- Hoh BL, Choudhri TF, Connolly ES Jr, Solomon RA. Surgical management of high-grade intracranial dural arteriovenous fistulas: Leptomeningeal venous disruption without nidus excision. *Neurosurgery* 1998;42:796-805.
- Liu JK, Dogan A, Ellegala DB, Carlson J, Nesbit GM, Barnwell SL, et al. The role of surgery for high-grade intracranial dural arterio-venous fistulas: Importance of obliteration of venous outflow. *J Neurosurg* 2009;110:913-20.
- Kallmes DF, Jensen ME, Cloft HJ, Kassell NF, Dion JE. Percutaneous transvenous coil embolisation of a Djindjian type 4 tentorial dural arteriovenous malformation. *Am J Neuroradiol* 1997;18:673-6.
- Malik GM, Pearce JE, Ausman JI, Mehta B. Dural arteriovenous malformations and intracranial hemorrhage. *Neurosurgery* 1984;15:332-9.
- Borden JA, Wu JK, Shucart WA. A proposed classification for spinal and cranial dural arteriovenous fistulous malformations and implications for treatment. *J Neurosurg* 1995;82:166-79.
- Deasy NP, Gholkar AR, Cox TC, Jeffree MA. Tentorial dural arteriovenous fistulae: Endovascular treatment with transvenous coil embolisation. *Neuroradiology* 1999;41:308-12.
- Lewis AI, Tomsick TA, Tew JM Jr. Management of tentorial dural arteriovenous malformations: Transarterial embolisation combined with stereotactic radiation or surgery. *J Neurosurg* 1994;81:851-9.
- Davies MA, Ter Brugge K, Willinsky R, Coyne T, Saleh J, Wallace MC. The validity of classification for the clinical presentation of intracranial dural arteriovenous fistulas. *J Neurosurg* 1996;85:830-7.
- Borha A, Emery E, Courtheoux P. Tentorial dural fistulas with giant venous ampullae treated with embolisation and surgery. A case report. *Acta Neurochir* 2010;152:1745-53.
- Awad IA, Barnett GH. Neurological deterioration in a patient with a spinal arteriovenous malformation following lumbar puncture. Case report. *J Neurosurg* 1990;72:650-3.
- Chandler HC Jr, Freidman WA. Successful radio surgical treatment of a dural arterio-venous malformation. Case report. *Neurosurgery* 1993;33:139-42.
- Enker SH. Progression of a dural arteriovenous malformation resulting in an intracerebral hematoma: A case report. *Angiology* 1979;30:198-204.
- Thompson BG, Doppman JL, Oldfield EH. Treatment of cranial dural arteriovenous fistulae by interruption of leptomeningeal venous drainage. *J Neurosurg* 1994;80:617-23.
- Duffau H, Lopes M, Janosevic V, Sichez JP, Faillot T, Capelle L, et al. Early rebleeding from intracranial dural arteriovenous fistulas: Report of 20 cases and review of the literature. *J Neurosurg* 1999;90:78-84.
- Barnwell SL, Halbach VV, Higashida RT, Hieshima G, Wilson CB. Complex dural arteriovenous fistulas. Result of combined endovascular and neurosurgical treatment in 16 patients. *J Neurosurg* 1989;71:352-8.
- Collice M, D'Aliberti G, Talamonti G, Branca V, Boccardi E, Scialfa G, et al. Surgical interruption of leptomeningeal drainage as treatment for intracranial dural arteriovenous fistulas without dural sinus drainage. *J Neurosurgery* 1996;84:810-7.
- Halbach VV, Higashida RT, Hieshima GB, Goto K, Norman D, Newton TH. Dural fistulas involving the transverse and sigmoid sinuses: Results of treatment in 28 patients. *Radiology* 1987;163:443-7.

25. Hardy RW, Costin JA, Weinstein M, Berlin AJ Jr, Gutman FA. External carotid cavernous fistula treated by transfemoral embolisation. *Surg Neurol* 1978;9:255-6.
26. Vinuela FV, Debrun GM, Fox AJ, Kan S. Detachable calibrated-leak balloon for super selective angiography and embolisation of dural arteriovenous malformations. *J Neurosurg* 1983;58:817-23.
27. Freidman JA, Pollock BE, Nicholas DA, Gorman DA, Foote RL, Stafford SL. Results of combined stereotactic radiosurgery and trans-arterial embolisation for dural arterio-venous fistulas of the transverse and sigmoid sinuses. *J Neurosurg* 2001;94:886-91.
28. Link MJ, Coffey RJ, Nichols DA, Gorman DA. The role of radiosurgery and particulate embolisation in the treatment of dural arteriovenous fistulas. *J Neurosurg* 1996;84:804-9.
29. Pan DH, Chung WY, Guo WY, Wu HM, Liu KD, Shiau CY, *et al.* Stereotactic radiosurgery for the treatment of dural arteriovenous fistulas involving the transverse-sigmoid sinus. *J Neurosurg* 2002;96:823-9.
30. Iwamuro Y, Nakahara I, Higashi T, Iwaasa M, Watanabe Y, Hirata E *et al.* Tentorial dural arteriovenous fistula presenting symptoms due to mass effect on the dilated draining vein. Case report. *Surg Neurol* 2005;65:511-5.
31. Pannu Y, Shownkeen H, Nockels RP, Origitano TC. Obliteration of a tentorial dural arteriovenous fistula causing spinal cord myelopathy using the cranio-orbito zygomatic approach. *Surg Neurol* 2004;62:463-7.

**How to cite this article:** Karanci T, Akdemir H, Aydin K. Giant tentorial dural arteriovenous fistula treated by a combination of trans-arterial embolization and surgery. *Indian J Neurosurg* 2012;1:144-8.

**Source of Support:** Nil, **Conflict of Interest:** None declared.

### "Quick Response Code" link for full text articles

The journal issue has a unique new feature for reaching to the journal's website without typing a single letter. Each article on its first page has a "Quick Response Code". Using any mobile or other hand-held device with camera and GPRS/other internet source, one can reach to the full text of that particular article on the journal's website. Start a QR-code reading software (see list of free applications from <http://tinyurl.com/yzlh2tc>) and point the camera to the QR-code printed in the journal. It will automatically take you to the HTML full text of that article. One can also use a desktop or laptop with web camera for similar functionality. See <http://tinyurl.com/2bw7fn3> or <http://tinyurl.com/3ysr3me> for the free applications.