

CASE REPORT

Acinetobacter baumannii bacteremia, a rare complication of endoscopic retrograde cholangiopancreatography!

Hadoun Jabri, Devang Sanghavi, Sarbajit Mukherjee, Ema Dzaka-Dizdarevic, Nkemakolam Iroegbu

Department of Internal Medicine, Saint Joseph Hospital, Chicago, IL, USA

Access this article online

Website: www.avicennajmed.com

DOI: 10.4103/2231-0770.130344

Quick Response Code:



ABSTRACT

Bacteremia is a severe and sometimes fatal complication following endoscopic retrograde cholangiopancreatography (ERCP). Several bacteria have been implicated, with *Enterobacteriaceae* being the most common. We report a case of post-ERCP multi-drug resistant *Acinetobacter baumannii* bacteremia.

Key words: *Acinetobacter baumannii* bacteremia, hospital acquired infections, post-endoscopic retrograde cholangiopancreatography bacteremia

INTRODUCTION

Acinetobacter baumannii is a Gram-negative rod that can be isolated in nature from water and soil. It is becoming an important cause of resistant nosocomial infections as it was found to be a causative agent in ventilator associated pneumonia, central line associated blood stream infection, catheter associated urinary tract infection and surgical site infection. Community acquired infections such as community acquired pneumonia has also been seen. Even though this bacterium has been well reported in literature to cause hospital acquired infections, its association with post-endoscopic retrograde cholangiopancreatography (ERCP) bacteremia and sepsis has not been well studied.

A. baumannii is an unusual cause of post-ERCP bacteremia and as shown in our patient, the infection may be fatal. This case emphasizes the need for appropriate precautions and consideration of unusual pathogens in patients with bacteremia or sepsis post-ERCP.

CASE REPORT

The present case report is about an 85-year-old female patient with a history of diverticular disease, hypertension,

left hip arthroplasty and gout was admitted to our hospital with a 1-week history of jaundice, lethargy, confusion and multiple episodes of falls. She denied any fever or abdominal pain.

Her initial vital signs were: Blood pressure 92/68 mmHg, temperature 98.0°F and pulse rate 86/min. Icteric sclera was noted. The rest of the physical examination including neurological system, skin, throat, chest and abdomen was normal. Murphy's sign was absent.

Significant laboratory findings included white blood cell count, 13,400/ μ L (4-11/ μ L) (differential counts of 81% neutrophils, 8% lymphocytes, 6% monocytes); hemoglobin, 13.8 g/dL (12-15.3 g/dL); platelet count, 268,000/mL (150-450/mL); blood urea nitrogen 39mg/dL(6-26mg/dL);creatinine1.57mg/dL(0.5-1mg/dL);total bilirubin 6.2 mg/dL (0-1 mg/dL); aspartate aminotransferase 248 U/L (0-32 U/L); alanine aminotransferase 185 U/L (0-40 U/L); and alkaline phosphatase 617 U/L (35-104 U/L).

A computed tomography scan of the abdomen [Figures 1 and 2] revealed a 1.8 cm obstructing stone in a distal common bile duct. The patient was empirically started on intravenous levofloxacin and metronidazole. Two days after her admission, she underwent ERCP. The procedure was

Address for correspondence: Dr. Hadoun Jabri, Saint Joseph Hospital, 2900 North Lakeshore Drive, Chicago, IL, USA.

E-mail: hodoonjabri85@hotmail.com

terminated due to profuse bleeding following papillotomy. The stone was not extracted. Initial blood cultures did not grow any pathogen.

At 4 days after her hospitalization, the patient underwent a second ERCP [Figure 3]. Pieces of stones were extracted and a stent was placed in the common bile duct. One day later, the patient became lethargic and developed a fever of 100.8F. The next morning, the patient deteriorated further with a blood pressure of 76/46 mmHg, pulse rate of 104 beats/min, respiratory rate of 25 breaths/min and oxygen saturation was 94% on 6 L nasal cannula with other clinical evidence of shock believed to be secondary to sepsis.

Antibiotics were switched to intravenous meropenem 500 mg twice daily with intravenous levofloxacin 750 mg. The next day, blood cultures revealed Gram-negative rods.

On day 9, she required intubation and mechanical ventilation for respiratory failure with the addition of maximum vasopressor support for refractory shock. Percutaneous cholecystostomy was performed on day 10 and 5 mL of thick brown fluid was aspirated.

5 out of 5 sets of blood cultures as well as culture of biliary fluid grew *A. baumannii*, resistant to almost all antibiotics including piperacillin/tazobactam, meropenem and levofloxacin. Intravenous tigecycline 50 mg every 12 h was added and parenteral colistin 75 mg every 12 h replaced meropenem based on the final sensitivity reports. Blood cultures drawn after the administration of colistin remained sterile. However, the patient did not recover from septic shock. After discussing the goals of care, her family opted for withdrawing medical management and pursuing comfort measures instead.

DISCUSSION

Bacteremia as a complication of ERCP has been well studied and reported in the literature. It is considered a severe complication that can be fatal if not promptly recognized and treated.^[1] In a retrospective study done in Korea by Kwak *et al.*,^[1] patients going for ERCP with no prior signs of infection were selected and investigated for the development of post-procedure bacteremia. 70 patients developed post-ERCP bacteremia mostly due to *Enterobacteriaceae* and those represented 3.1% of the study population. This study also suggested that elevated serum alkaline phosphatase and a prior liver transplant are independent risk factors for post-ERCP bacteremia.

Another study done by Anderson *et al.*^[2] showed that blood stream infections were detected in 46 out of the 2052 patients

who got ERCP, calculating incidence of 2.24%. The most common organisms were *Enterobacteriaceae* (29%) followed by Enterococci (22%).

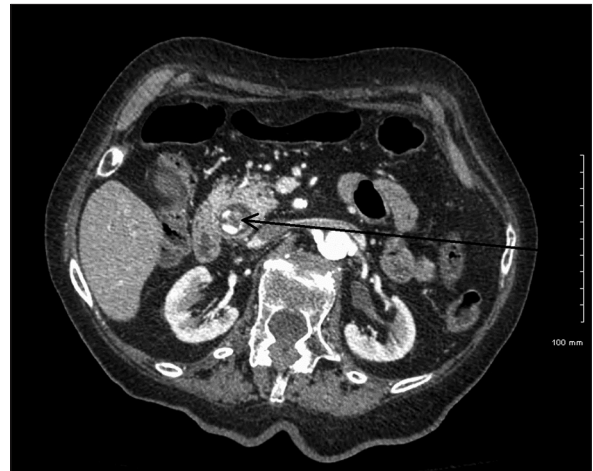

Figure 1: Transverse section from a Computed tomography scan of the abdomen showing a stone in the common bile duct. Arrow pointing to the stone

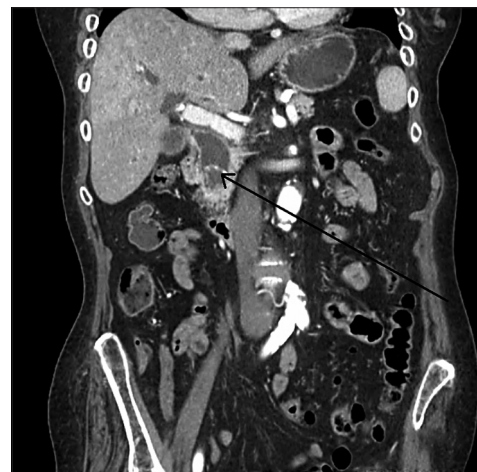

Figure 2: Coronal section from a Computed tomography scan of the abdomen showing the same stone in the common bile duct. Arrow pointing to the stone

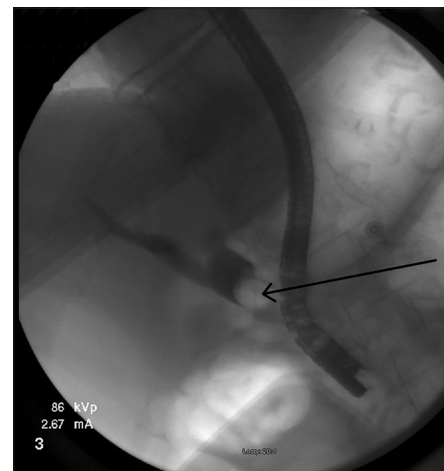


Figure 3: Endoscopic retrograde cholangiopancreatography showing a defect representing a stone in the common bile duct

Early and appropriate antibiotic coverage in bacteremic patients improves mortality. The antibiotic regimen in cases of post-ERCP bacteremia should cover Gram-negative and anaerobic bacteria, however, there is no consensus on the best regimen and antibiotics should be modified based on the culture results.

Acinetobacter bacteremia was reported previously in a 46-year-old female as a complication of ERCP.^[3] However, the identified species in that case was *ursingii*.

A. baumannii is a Gram-negative bacillus that is known to affect those with compromised immune system. However, it is becoming an important nosocomial infection causing sepsis and pneumonia in ventilated and non-ventilated patients.^[4,5] More attention has been given to this bacterium following the emergence of multi drug resistant (MDR) clones.^[6]

Treatment of *A. baumannii* starts empirically with a broad-spectrum cephalosporin, a combination of beta-lactam/beta-lactamase inhibitor or a carbapenem.^[7] When the sensitivity of the bacteria becomes available, more directed therapy should be initiated. In MDR cases, colistin, Polymyxin B or Tigecycline can be used.^[8,9] Antibiotic therapy was tailored based on culture and susceptibility reports, but the outcome in our patient was poor.

There have been some studies looking at measures to reduce the risk of post-ERCP bacteremia and sepsis but the results were somehow controversial. In a study done in Texas, Gentamycin incorporated into the contrast material was successful in reducing the rates of post-ERCP bacteremia.^[10] In another study, antibiotics were used parenterally prior to ERCP but failed to produce any significant change in the incidence of bacteremia.^[11]

CONCLUSION

Bacteremia and sepsis are potentially fatal complications of ERCP. We believe that physicians should be aware of *A. baumannii* as a possible cause of post-ERCP bacteremia. There is an increase in the rate of the MDR strains, which

require empiric broad spectrum antibiotics. Treatment is best directed by the culture and sensitivity of body fluids and delay in treatment is associated with worse outcome.

REFERENCES

1. Kwak MS, Jang ES, Ryu JK, Kim YT, Yoon YB, Park JK. Risk factors of post endoscopic retrograde cholangiopancreatography bacteremia. *Gut Liver* 2013;7:228-33.
2. Anderson DJ, Shimpi RA, McDonald JR, Branch MS, Kanafani ZA, Harger J, et al. Infectious complications following endoscopic retrograde cholangiopancreatography: An automated surveillance system for detecting postprocedure bacteremia. *Am J Infect Control* 2008;36:592-4.
3. de la Tabla Ducasse VO, González CM, Sáez-Nieto JA, Gutiérrez F. First case of post-endoscopic retrograde cholangiopancreatography bacteraemia caused by *Acinetobacter ursingii* in a patient with choledocholithiasis and cholangitis. *J Med Microbiol* 2008;57:1170-1.
4. Simonetti A, Ottaiano E, Diana MV, Onza C, Triassi M. Epidemiology of hospital-acquired infections in an adult intensive care unit: Results of a prospective cohort study. *Ann Ig* 2013;25:281-9.
5. Baranzelli A, Wallyn F, Nseir S. Lower respiratory tract infections related to *Stenotrophomonas maltophilia* and *Acinetobacter baumannii*. *Rev Pneumol Clin* 2013;69:250-9.
6. Fariñas MC, Martínez-Martínez L. Multiresistant Gram-negative bacterial infections: *Enterobacteria*, *Pseudomonas aeruginosa*, *Acinetobacter baumannii* and other non-fermenting Gram-negative bacilli. *Enferm Infecc Microbiol Clin* 2013;31:402-9.
7. American Thoracic Society, Infectious Diseases Society of America. Guidelines for the management of adults with hospital-acquired, ventilator-associated, and healthcare-associated pneumonia. *Am J Respir Crit Care Med* 2005;171:388-416.
8. Lim SK, Lee SO, Choi SH, Choi JP, Kim SH, Jeong JY, et al. The outcomes of using colistin for treating multidrug resistant *Acinetobacter* species bloodstream infections. *J Korean Med Sci* 2011;26:325-31.
9. Príncipe L, Capone A, Mazzarelli A, D'Arezzo S, Bordi E, Di Caro A, et al. *In vitro* activity of doripenem in combination with various antimicrobials against multidrug-resistant *Acinetobacter baumannii*: Possible options for the treatment of complicated infection. *Microb Drug Resist* 2013;19:407-14.
10. Ramirez FC, Osato MS, Graham DY, Woods KL. Addition of gentamicin to endoscopic retrograde cholangiopancreatography (ERCP) contrast medium towards reducing the frequency of septic complications of ERCP. *J Dig Dis* 2010;11:237-43.
11. Llach J, Bordas JM, Almela M, Pellisé M, Mata A, Soria M, et al. Prospective assessment of the role of antibiotic prophylaxis in ERCP. *Hepatogastroenterology* 2006;53:540-2.

Cite this article as: Jabri H, Sanghavi D, Mukherjee S, Dzaka-Dizdarevic E, Iroegbu N. *Acinetobacter baumannii* bacteremia, a rare complication of endoscopic retrograde cholangiopancreatography!. *Avicenna J Med* 2014;4:37-9.

Source of Support: Nil, **Conflict of Interest:** None declared.