

Innovative approach for prevention and treatment of post subarachnoid hemorrhage vasospasm: A preliminary report

Neelam K. Venkataramana, Shailesh A. V. Rao, Arun L. Naik, Kishore Shetty, Papparaja Murthy, Abhilash Bansal, Christos Panotopoulos¹

Department of Neurosurgery, Advanced Neuro Science Institute, BGS Global Hospital, Bangalore, Karnataka, India, ¹Visiting Consultant Neurosurgeon, Mediterraneo Hospital, Athens, Greece

ABSTRACT

More than one third of patients with subarachnoid hemorrhage (SAH) develop clinically significant vasospasm, as a leading morbidity and mortality factor for these patients. It is widely accepted that a) Degradation products of blood are the causative factors of vasospasm b) The amount of subarachnoid blood seen on admission CT is correlated to the risk of vasospasm c) Reducing the subarachnoid clot burden at the time of surgery reduces the risk of vasospasm. But there is no existing method to clear the blood from subarachnoid spaces satisfactorily. We have evaluated safety and feasibility of fluid exchange catheter system in SAH, to achieve this goal. We were successful in clearing cisternal blood in three patients with aneurysmal rupture with fluid exchange catheter system. Baseline CT scan of brain was performed immediately after the surgery and then at the end of irrigation. The amount of subarachnoid blood was evaluated. This innovative, fluid exchange catheter system infuses and aspirates micro volumes of drug solution in a cyclic mode, ensuring isobaric exchange of fluids. The result is good clearance of blood in subarachnoid spaces were seen in all the patients. Also, significant improvement in neurological deficits secondary to vasospasm was seen. We conclude that the fluid exchange catheter system is safe and adoptable in neurosurgical practice.

Key words: Cisternal blood, flux irrigation system, subarachnoid hemorrhage, vasospasm

Introduction

The outcome of subarachnoid hemorrhage (SAH) is often complicated by the occurrence of vasospasm. Angiographic vasospasm is seen in 30-70% of patients with aneurysmal SAH.^[1,2] Of these symptoms of cerebral ischemia with high risk of debilitating stroke and mortality, clinically significant spasms can occur in 20-30% of patients.^[3] Many theories have been proposed and several treatment regimens have been tried to treat vasospasm. Till date, there is no satisfactory

method to adequately treat vasospasm. Among the several variables, the amount of subarachnoid blood has significant correlation to the development of spasm.^[4,5] It is also well known that clearing of blood from the cisterns during surgery helps in reducing the incidence and severity of vasospasm. Technically, it may be difficult and invasive to clear all the blood satisfactorily.

Innovation

We have used a fluid exchange catheter system (FLUX) which infuses and aspirates micro volumes of fluid and drug solution in a cyclic mode. This is done in an isobaric exchange of fluids and can clear cisternal blood after aneurysm surgery.

Clinical Data

With scientific and ethical approval, as well as with written informed consent from the patient and/or legally acceptable representative, FLUX catheter was placed in the subarachnoid space after aneurysm clipping in three patients with severe SAH (Fisher grade 3). We used an average of five liters of Ringer's Lactate with papavarine at a concentration of 8×10^{-5} M, for 72 hours, starting immediately after surgery. CT scan performed at the end of this period showed no residual

Access this article online	
Quick Response Code:	Website: www.asianjns.org
	DOI: 10.4103/1793-5482.98650

Address for correspondence:

Dr. Neelam K. Venkataramana, Neurosurgeon, Founder-Comprehensive Trauma Consortium, BGS Health and Education City, No. 67, Uttarahalli Road, Kengeri, Bangalore - 560 060, Karnataka, India. E-mail: drnkvr@gmail.com

blood in the subarachnoid spaces in all the three patients. Patient 1 did not develop any vasospasm and was discharged with intact neurological status [Figure 1a and b]. Patients' 2 and 3, who had already severe vasospasm on admission, improved significantly, clinically, over four to six weeks, and was also discharged with no neurological deficit [Figure 2a and b].

Discussion

More than one third of patients with subarachnoid hemorrhage (SAH) develop clinically significant vasospasm, as a leading morbidity and mortality factor for these patients.^[6] It is widely accepted that a) Degradation products of blood are the causative factors of vasospasm^[7,8] b) The amount of subarachnoid blood seen on admission CT is correlated to the risk of vasospasm^[9] c) Reducing the subarachnoid clot burden at the time of surgery reduces the risk of vasospasm.

Clearing the subarachnoid blood from cisterns following aneurysm rupture remains a technical challenge. Neurosurgeons

adopted variety of irrigation methods and drains intra- and post-operative period, respectively. Risk of increasing intracranial pressure (ICP) in adequate clearance and infection were the usual risks. We have over come these problems with FLUX double lumen catheter which infuses and simultaneously aspirates fluid. Since it is a volume regulated and pressure controlled system through a built-in programmed soft ware, there in risk of increasing ICP. In our experience, 72 hours are more than sufficient, and hence, risk of infection is negligible. We have not only found it effective, but also have found the advantage of infusing a drug in micro quantities and deriving the best therapeutic benefit in addition. In our preliminary experience, there were no notable complications, safe and user friendly. The clinical benefits associated are very much encouraging to make this method as part of SAH treatment protocol.

Conclusion

The FLUX fluid exchange system is an effective method for

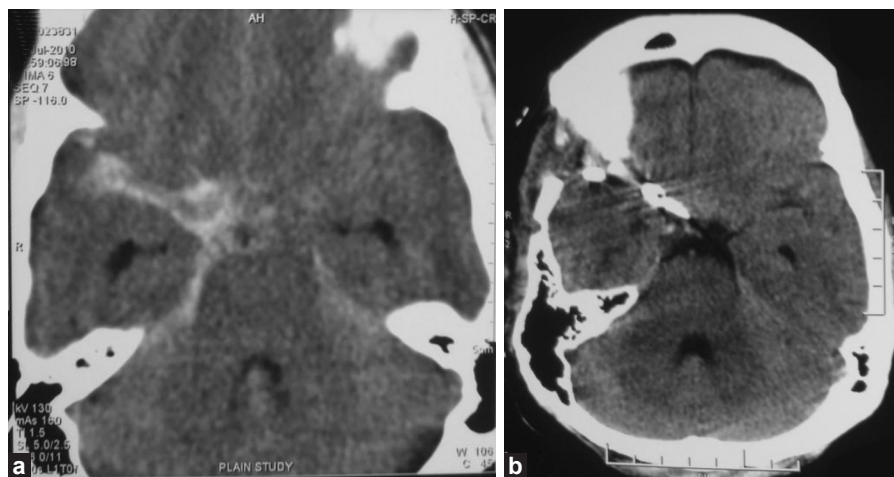


Figure 1: (a) Preoperative CT brain scan showing SAH in Rt. sylvian fissure and Rt. ambient cistern (b) CT brain scan showing clearance of subarachnoid blood (post-FLUX use)

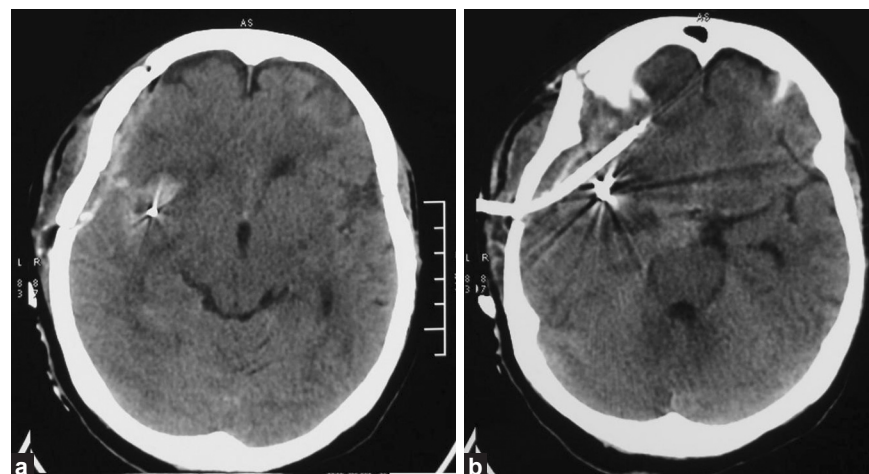


Figure 2: (a) CT brain scan showing hematoma and subarachnoid blood in right ambient cistern, immediately after clipping (b) Seventy two hours post-irrigation CT brain scan showing clearance of subarachnoid blood, FLUX catheter *in situ*

clearing blood in the subarachnoid spaces with the infusion of drug, leading to either prevention or clearance of vasospasm with clinical benefit. This is a safe and adoptable method in neurosurgical practice.

References

1. Dorsch NW. Cerebral arterial spasm – A clinical review. *Br J Neurosurg* 1995;9:403-12.
2. Heros RC, Zervas NT, Varsos V. Cerebral vasospasm after subarachnoid hemorrhage: An update. *Ann Neurol* 1983;14:599-608.
3. Lazaridis C, Naval N. Risk factors and medical management of vasospasm after subarachnoid hemorrhage. *Neurosurg Clin N Am* 2010;21:353-64.
4. Claassen J, Bernardini GL, Kreiter K, Bates J, Du YE, Copeland D, *et al.* Effect of Cisternal and ventricular blood on risk of delayed cerebral ischemia after subarachnoid hemorrhage; the fisher scale revisited. *Stroke* 2001;32:2012-20.
5. Fronstera JA, Claassen J, Schmidt JM, Wartenberg KE, Temes R, Connolly ES Jr, *et al.* Prediction of symptomatic vasospasm after subarachnoid hemorrhage: The modified fisher scale. *Neurosurgery* 2006;59:21-7.
6. Qureshi AI, Sung GY, Suri MA, Straw RN, Guterman LR, Hopkins LN. Prognostic value and determinants of ultra-early vasospasm after aneurysmal subarachnoid hemorrhage. *Neurosurgery* 1999;44:967-74.
7. Kolia AG, Sen J, Belli AJ. Pathogenesis of cerebral vasospasm following aneurysmal subarachnoid hemorrhage. Putative mechanisms and novel approaches. *Neurosci Res* 2009;87:1-11.
8. Macdonald RL, Weir BK. A review of hemoglobin and the pathogenesis of cerebral vasospasm. *Stroke* 1991;22:971-82.
9. Fisher CM, Kistler JP, Davis JM. Relation of cerebral vasospasm to subarachnoid hemorrhage visualized by computerized tomographic scanning. *Neurosurgery* 1980;6:1-9.

How to cite this article: Venkataramana NK, Rao SA, Naik AL, Shetty K, Murthy P, Bansal A, *et al.* Innovative approach for prevention and treatment of post subarachnoid hemorrhage vasospasm: A preliminary report. *Asian J Neurosurg* 2012; 7:78-80.

Source of Support: Nil, **Conflict of Interest:** None declared.