Article published online: 2022-09-27

CASE REPORT

Intra-axial CNS dermoid cyst

Vernon L. Velho, Shadma W. Khan, V. Agarwal, M. Sharma
Department of Neurosurgery, Grant Medical College and Sir J.J. Group of Hospitals, Byculla, Mumbai, Maharashtra, India

ABSTRACT

Intracranial dermoid cysts are rare tumors. They constitute 0.3% of intracranial tumors. These are commonly seen in the midline and sylvian area. Intraaxial lesions are extremely rare. We report the case of a 35-years-old female with a large intraaxial dermoid cyst, which was reported as oligodendroglioma on imaging studies done preoperatively, but was confirmed to be a dermoid cyst intra-operatively and on histopathological examination; thus highlighting a diagnostic dilemma. Patient did well post operatively and there is no recurrence in the one year follow-up. To conclude, dermoid cysts are rare benign tumors, and intraaxial lesions are still rarer. Complete surgical excision may become difficult due to adherence to nerves and vessels.

Key words: Dermoid, intraaxial, oligodendroglioma, pterional

Introduction

Intracranial dermoid cysts are rare tumors.[1,2] They constitute 0.3% of intracranial tumors. These are commonly seen in the midline and sylvian area.[3] Intra-axial lesions are extremely rare.[4-6] We report the case of a 35-year-old female with a large intra-axial dermoid cyst.

Case Report

A 35-year-old, right-handed house-wife presented to the hospital with complaints of headache and generalized tonic clonic seizures of three years duration. On neurological examination, the patient was conscious, oriented, with normal higher mental functions, no cranial, motor or sensory nerve deficit.

Computed tomography (CT) scan showed an iso- to hypo-dense lesion in the right temporal region which was intraaxial, having a calcified rim [Figure 1].

Magnetic resonance imaging (MRI) findings were suggestive of an iso- to hyper-intense lesion in the right temporal lobe with mixed intensity, having a peripheral calcified rim, without much perilesional edema [Figure 2-5].

CT scan and MRI findings were diagnostic of oligodendroglioma.

Patient was operated by a right pterional craniotomy with transsylvian approach [Figure 6].

Operative findings: Tumor was intraaxial, pearly white, soft, and suckable, and had pultaceous material with hair and calcified hard tissue inside.

The tumor capsule was excised totally, leaving behind the calcified hard bony part which was adherent to the middle cerebral artery.

Post operatively, the patient recovered well. Post operative scan showed minimal residual lesion, the calcified part which was deliberately left behind.

The patient was discharged on 10th post operative day, without any neurological deficit. Neuropathological diagnosis was suggestive of dermoid cyst [Figure 7].

Discussion

Dermoid cysts are rare, slow growing, and benign tumors commonly seen in the midline.[1-3] Of these rare tumors, the intracranial intraaxial variety is exceptional, with only few case reports in literature,[5,6] that too in the posterior fossa region. Our case of an intracranial intraaxial supratentorial lesion is a very rare one, not reported in isolation or as part of case series in the literature. They are congenital inclusion cysts which arise from more than one germ layer and at a later stage, may contain fat, keratin, hair, bone, cartilage, sebaceous, and sweat glands.[7] These tumors present with headache, seizures, neurological deficits and

Access this article online	
Quick Response Code:	Website: www.asianjns.org
	DOI: 10.4103/1793-5482.95700

Address for correspondence:
Dr. Vivek Agrawal, Department of Interventional neuroradiology, Zurich University Hospital , Switzerland and Department of Neurosurgery, Grant Medical College, Mumbai, India. Email: neuro.vi@gmail.com

Figure 1: Pre operative CT scan brain

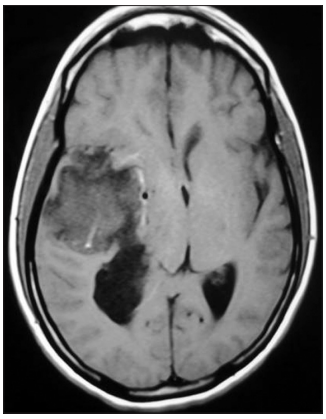

Figure 2: MRI T1W axial image

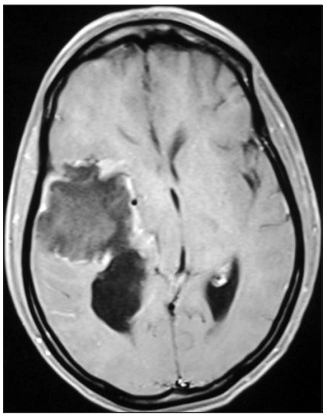

Figure 3: MRI brain T1W contrast image

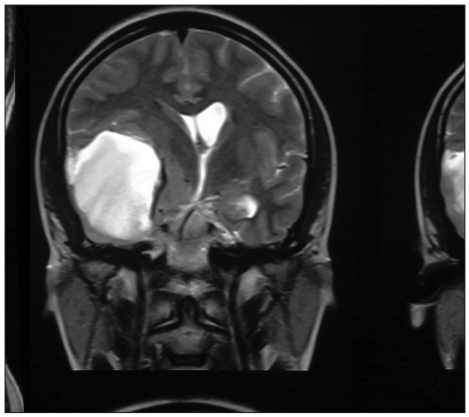

Figure 4: T2W images

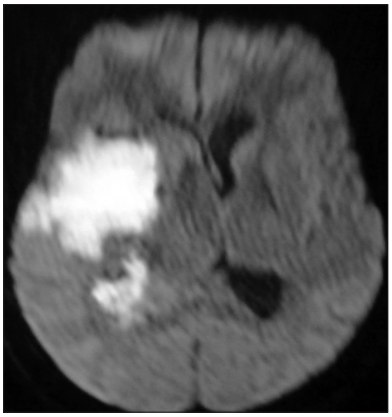

Figure 5: Diffusion image

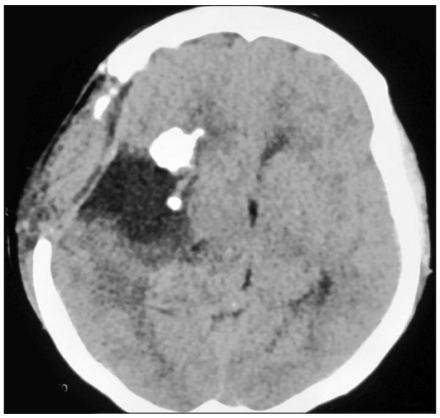

Figure 6: Post operative CT scan brain

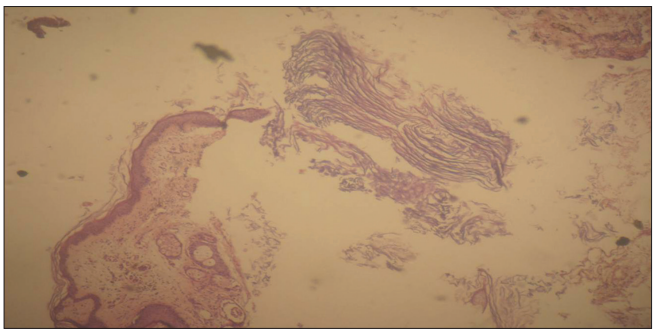

Figure 7: Histopathological slide

aseptic meningitis, and ventriculitis, if rupture occurs.[7,8] Radiological diagnosis at times is difficult unless fat particles and calcification can be demonstrated.[9] Intraoperative diagnosis is the only sure means of detecting a dermoid, after careful examination of the contents, though newer imaging techniques like use of fat suppression images may help in making an accurate diagnosis, preoperatively.

Surgical excision of the tumor is the treatment of choice. However, adherence of the wall to important structures like vessels, makes the complete removal challenging. As

intracranial dermoids are rare tumors, there is no data available on long term follow-up of patients in whom the cysts have been partially excised.

Our patient has been attending regular follow-up, and at the end of one year, has not shown any increase in the size of the residual lesion.

References

1. Love J, Kernohan J. Dermoid and epidermoid tumors of CNS. JAMA 1936;107:1876-83.
2. Gormley WB, Tomecek FJ, Qureshi N. Craniocerebral epidermoid and dermoid tumors-a review of 32 cases. Acta Neurochir (Wien) 1994;128:1115-21.
3. Caldarelli M, Massimi L. Intracranial midline dermoid and epidermoid in children. J Neurosurg 2005;102:135-7.
4. Zimmerman JR, Raila FA, Russell WA, Smith RR. Case report - CT and MRI of intracranial dermoid causing headache. J Miss State Med Assoc 1996; 37:509-12.
5. Caldarelli M, Colosimo C, Di Rocco C. Intra-axial dermoid/epidermoid tumors of the brainstem in children. Surg Neurol 2001;56:97-105.
6. Pant I, Joshi SC. Cerebellar intra-axial dermoid cyst - a case of unusual location. Childs Nerv Syst 2008;25:395-6.
7. Dias MS, Walker ML. Embryogenesis of complex dysraphic malformations - A disorder of ? Gastrulation. Pediatr Neurosurg 1992; 18:229-53.
8. Detweiler MB, David E, Arif S. Ruptured Intracranial Dermoid Cyst Presenting With Neuropsychiatric Symptoms - A Case Report. South Med J 2009;102:98-100.
9. Sharma NC, Chandra T, Sharma A, Bajaj M, Kundu R. Long segment intramedullary spinal dermoid. Indian J Radiol Imaging 2009;19:148-50.

How to cite this article: Velho VL, Khan SW, Agarwal V, Sharma M. Intra-axial CNS dermoid cyst. Asian J Neurosurg 2012;7:42-4.

Source of Support: Nil, **Conflict of Interest:** None declared.