

Intracranial Hypotension-associated Cerebral Swelling following Cranioplasty: Report of Two Cases

Abstract

Cranioplasty is a comparatively simple neurosurgical procedure, and fatal complications are rare. This report describes two cases of critical brain swelling after otherwise uneventful cranioplasty. Both cases had subarachnoid hemorrhage and extremely similar clinical courses. They underwent decompressive craniotomy and clipping in the acute phase and had cranioplasty in the chronic phase, resulting in serious cerebral swelling and death. Deep venous sinus thrombosis was revealed in the autopsy for one case. Although no venous occlusion was identified in the other case, radiological findings suggested venous congestion. In both cases, intraoperative cerebrospinal fluid leakage was massive and was prolonged by a drain; therefore, we hypothesized that intracranial hypotension (IH) caused stagnation of venous flow. Neurosurgeons should be aware that fatal venous congestion induced by IH may occur after cranioplasty. To avoid this, tight dural closure should be obtained, and avoidance of the use of subcutaneous drains should be considered.

Keywords: Brain swelling, cranioplasty, intracranial hypotension

Introduction

Cranioplasty is a relatively simple neurosurgical procedure, and fatal complications are rarely reported. In a reported series of 239 cases, the overall complication rate was 23.8% and no deaths occurred.^[1] Here, we report two rare cases of cerebral swelling and subsequent death following otherwise uneventful cranioplasty and discuss the possible pathophysiology underlying this phenomenon.

Case Reports

A total of 299 cranioplasties were performed in Tokyo Metropolitan Tama Medical Center between 2000 and 2013. Of these cases, 2 patients (0.67%) had similar courses resulting in death.

Case 1

A 43-year-old male was admitted to our hospital with subarachnoid hemorrhage (SAH) due to a ruptured middle cerebral artery (MCA) bifurcation aneurysm. The patient underwent decompressive craniectomy in which the aneurysm was clipped and related normal arteries were preserved. A postoperative computed tomography (CT) scan showed brain swelling. As the brain edema worsened,

lobectomy and duraplasty with artificial dura mater were performed. On day 46 after the first operation, he underwent cranioplasty with an autologous bone flap. Before cranioplasty, all blood tests were normal, and a brain CT scan revealed subcutaneous cerebrospinal fluid (CSF) [Figure 1a and b]. As the skin was incised, an excessive amount of CSF was released. The procedure uneventfully ended with placement of a subgaleal drain. Soon after surgery, we observed a large amount of bloody CSF in the closed vacuum drainage system. A postoperative CT scan showed massive cerebral swelling [Figure 1c and d]. Angiography demonstrated a marked delay of cerebral circulation. The patient died within 72 h. Anoxia during anesthesia was excluded by the operative chart. Although the deep venous system was not evaluated, the autopsy revealed no evidence of vessel occlusion.

Case 2

A 73-year-old man presented with SAH with left temporal lobe hematoma, and angiography demonstrated a left MCA aneurysm. The patient underwent decompressive craniectomy and definitive aneurysm clipping. Two days later, brain swelling developed, and thus expansion

**Masashi Nomura,
Takahiro Ota,
Mitsugu Ishizawa¹,
Shinsuke Yoshida,
Takayuki Hara²**

Departments of Neurosurgery and ¹Pathology, Tokyo Metropolitan Tama Medical Center, ²Department of Neurosurgery, Toranomom Hospital, Tokyo, Japan

Address for correspondence:
Dr. Masashi Nomura,
Department of Neurosurgery,
Tokyo Metropolitan Tama
Medical Center, 2-8-29,
Musashi-dai, Fuchu City, Tokyo,
183-8524, Japan.
E-mail: nomura-m@umin.ac.jp

Access this article online

Website: www.asianjns.org

DOI: 10.4103/1793-5482.185070

Quick Response Code:



How to cite this article: Nomura M, Ota T, Ishizawa M, Yoshida S, Hara T. Intracranial hypotension-associated cerebral swelling following cranioplasty: Report of two cases. *Asian J Neurosurg* 2017;12:794-6.

This is an open access article distributed under the terms of the Creative Commons Attribution-NonCommercial-ShareAlike 3.0 License, which allows others to remix, tweak, and build upon the work non-commercially, as long as the author is credited and the new creations are licensed under the identical terms.

For reprints contact: reprints@medknow.com

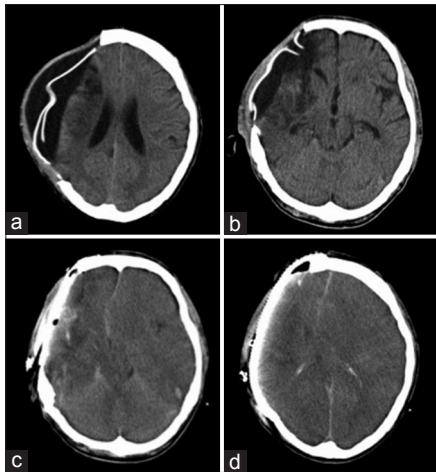


Figure 1: Computed tomography scans in case 1 (a and b) preoperative axial computed tomography scan showing distinct subcutaneous fluid collection and subdural space. (c and d) Postoperative axial computed tomography scan showing whole brain swelling and midline shift

of the craniectomy and lobectomy was performed. During surgery, the lateral ventricle was opened and packed with gelatin sponge. Artificial dura mater was used for dural closure. On day 41 after the first surgery, cranioplasty was performed. The preoperative blood test results were in the normal range, except for a slight elevation of white blood cells and C-reactive protein [Table 1]. A CT scan revealed massive subcutaneous and subdural fluid accumulation [Figure 2a and b]. In the operation, an excessive amount of CSF was released and the brain was collapsed. A subgaleal tube was placed and fluid accumulation drained spontaneously. Although the vital signs were stable during anesthesia, the systolic blood pressure elevated to 190 mmHg just after the end of the operation. His pupils became dilated, and a CT scan confirmed massive cerebral swelling with spotty hemorrhaging in the contralateral basal ganglia [Figure 2c and d]. Angiography revealed slow flow, and the deep venous system was not clearly visualized. Postoperative blood tests revealed increased fibrin degradation products and D-dimer [Table 1]. The patient died within 24 h. The autopsy revealed thrombus and damaged endothelial cells in the deep venous sinus, and thus deep venous sinus thrombosis was diagnosed [Figure 3a and b].

Discussion

Both cases developed severe brain swelling just after otherwise uneventful cranioplasty, resulting in death. We suspect that the same pathophysiological process was responsible for these unfortunate outcomes. In the case 2, autopsy revealed deep venous sinus thrombosis. To the best of our knowledge, this is the first reported case of cerebral venous thrombosis (CVT) as a postoperative complication of cranioplasty.

CVT is a rare cerebrovascular disease. In the large International Study on Cerebral Vein and Dural Sinus Thrombosis (ISCVT) cohort, neurosurgery contributed

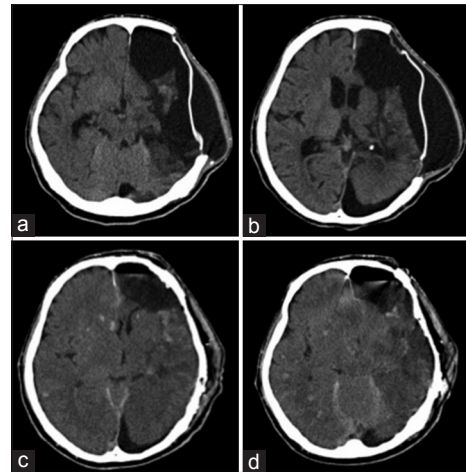


Figure 2: Computed tomography scans in case 2 (a and b) preoperative axial computed tomography scan showing distinct subcutaneous fluid collection and subdural space communication with the ventricle. (c and d) Postoperative axial computed tomography scan showing diffuse brain swelling, midline shift, and scattered petechial hemorrhaging

in 0.6% of the 624 CVT patients.^[2] Ventriculoperitoneal shunting or spinal surgery was reported as causes of CVT.^[3,4] Intracranial hypotension (IH) induced by decreased CSF is hypothesized to damage of cerebral veins by stretching and dilation, thus triggering CVT.

Pseudohypoxic brain swelling (PHBS) results from similar pathogenic mechanisms. As proposed in 2003 by Van Roost *et al.*, it is a rapid and fatal postoperative complication after otherwise uneventful intracranial surgery, in which the morphological findings mimic those of hypoxic brain.^[5-7] Radiological findings include the changes which are also present after venous occlusion by internal CVT.^[8,9] IH resulting from vacuum suction drainage of CSF in the presence of a dura that was not sutured to be entirely watertight is proposed as the most likely cause. In the past, 22 cases of PHBS were reported.^[5-8,10]

Concerning the cause of CVT in case 2, the patient might have had a hypercoagulable hematologic condition because he was bedridden and susceptible to dehydration.^[11] The other risk factors for CVT mentioned in ISCVT, including thrombophilia, puerperium, infection, drugs, malignancy, and pregnancy, were not identified.^[2,12] In case 1, venous sinus occlusion was not identified, but the bilateral brain swelling was suggestive of venous congestion.

We hypothesized that IH induced severe brain swelling in both of the current cases. Postoperative over-drainage of CSF might have induced IH and resulted in the catastrophic deterioration.^[10] According to the Monro-Kellie doctrine, a decrease in CSF volume and subsequent IH cause venous congestion and can secondarily lead to venous infarction or CVT.^[4,6,8,13,14] It is reported that outflow impairment occurs mainly in the great cerebral vein as it enters the tentorial sinus.^[13] The endothelial cell injury revealed in the autopsy of case 2 may have been induced by IH. When the ventricle has been opened or artificial dura (which is more difficult

Table 1: Blood tests data of case 1

	Preoperation	Postoperation	Normal range	Unit
White blood cell count (WBC)	10.3	17.2	(3.9-9.0)	×10 ³ /μL
Hemoglobin (HGB)	13.1	13.2	(13.5-17.4)	g/dL
Platelet (PLT)	32.2	30.8	(13.0-40.0)	×10 ⁴ /μ
Blood urea nitrogen (BUN)	14.7	19.0	(7.0-20.0)	mg/dL
Creatinine (Cre)	0.33	0.56	(0.6-1.3)	mg/dL
C-reactive protein (CRP)	1.24	1.73	(<0.3)	mg/dL
International normalized ratio of prothrombin time (PT-INR)	1.08	1.07	(0.82-1.18)	
Activated partial thromboplastin time (APTT)	36.0	31.7	(27.0-34.0)	sec
D-dimer		23.6	(<1.0)	μg/dL
Fibrin degradation products (FDP)		45.4	(8.0-22.0)	μg/dL
Protein C activity		93	(64-146)	%
Protein C antigen		146	(70-150)	%
Protein S activity		104	(60-150)	%
Protein S antigen		124	(65-135)	%

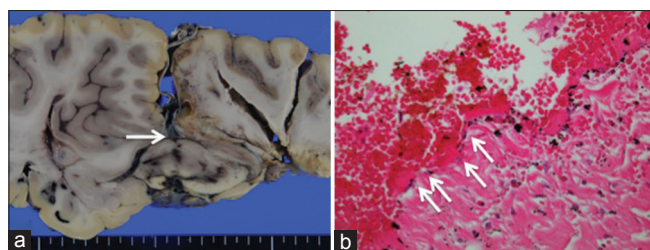


Figure 3: Autopsy findings in case 2 (a) macroscopic examination reveals thrombus in deep venous sinus (arrowhead). (b) Histological examination of an affected deep venous sinus. Linear structure of endothelial cells is unclear with thrombus formation along luminal surface (arrows) (H and E, ×40)

to close perfectly than autogenous material) has been used, IH-associated CSF leakage could occur.

These cases highlight the fact that cranioplasty can lead to the development of devastating venous congestion as a rare complication. To prevent this complication, artificial dura mater should be tightly closed or sutures should be added at cranioplasty. Moreover, massive subcutaneous fluid accumulation before cranioplasty suggests that the subcutaneous space communicates with the CSF space. This finding should prompt neurosurgeons to consider avoiding the use of subcutaneous drains.

Financial support and sponsorship

Nil.

Conflicts of interest

There are no conflicts of interest.

References

- Walcott BP, Kwon CS, Sheth SA, Fehnel CR, Koffie RM, Asaad WF, et al. Predictors of cranioplasty complications in stroke and trauma patients. *J Neurosurg* 2013;118:757-62.
- Ferro JM, Canhão P, Stam J, Bousser MG, Barinagarrementeria F; ISCVT Investigators. Prognosis of cerebral vein and dural sinus thrombosis: Results of the international study on cerebral vein and dural sinus thrombosis (ISCVT). *Stroke* 2004;35:664-70.
- Matsubara T, Ayuzawa S, Aoki T, Ikeda G, Shiigai M, Matsumura A. Cerebral venous thrombosis after ventriculoperitoneal shunting: A case report. *Neurol Med Chir (Tokyo)* 2014;54:554-7.
- Lourenço Costa B, Shamasna M, Nunes J, Magalhães F, Peliz AJ. Cerebral venous thrombosis: An unexpected complication from spinal surgery. *Eur Spine J* 2014;23 Suppl 2:253-6.
- Van Roost D, Thees C, Brenke C, Oettel F, Winkler PA, Schramm J. Pseudohypoxic brain swelling: A newly defined complication after uneventful brain surgery, probably related to suction drainage. *Neurosurgery* 2003;53:1315-26.
- Parpaley Y, Urbach H, Kovacs A, Klehr M, Kristof RA. Pseudohypoxic brain swelling (postoperative intracranial hypotension-associated venous congestion) after spinal surgery: Report of 2 cases. *Neurosurgery* 2011;68:E277-83.
- Yokota H, Yokoyama K, Miyamoto K, Nishioka T. Pseudohypoxic brain swelling after elective clipping of an unruptured anterior communicating artery aneurysm. *Clin Neurol Neurosurg* 2009;111:900-3.
- Hadzizadeh DR, Kovács A, Tschampa H, Kristof R, Schramm J, Urbach H. Postsurgical intracranial hypotension: Diagnostic and prognostic imaging findings. *AJNR Am J Neuroradiol* 2010;31:100-5.
- Keller E, Flacke S, Urbach H, Schild HH. Diffusion- and perfusion-weighted magnetic resonance imaging in deep cerebral venous thrombosis. *Stroke* 1999;30:1144-6.
- Evins AI, Boeris D, Burrell JC, Ducati A. Postoperative intracranial hypotension-associated venous congestion: Case report and literature review. *Clin Neurol Neurosurg* 2013;115:2243-6.
- Yang XY, Gao S, Ding J, Chen Y, Zhou XS, Wang JE. Plasma D-dimer predicts short-term poor outcome after acute ischemic stroke. *PLoS One* 2014;9:e89756.
- Bousser MG, Ferro JM. Cerebral venous thrombosis: An update. *Lancet Neurol* 2007;6:162-70.
- Savoirdo M, Minati L, Farina L, De Simone T, Aquino D, Mea E, et al. Spontaneous intracranial hypotension with deep brain swelling. *Brain* 2007;130(Pt 7):1884-93.
- Mokri B. The Monro-Kellie hypothesis: Applications in CSF volume depletion. *Neurology* 2001;56:1746-8.