

A Rare Case of Aggressive, Huge Primary Orbital Lymphoma with Intracranial Extension and Bone Invasion

Abstract

Primary orbital lymphoma is a rare entity with only 1% of extranodal lymphomas. They usually present to ophthalmologist and surgical reserved for biopsy or tissue diagnosis. We present a patient who was referred to neurosurgery for a rapid growing orbital lymphoma. It grows from a small nodule in the eyelid to a huge, aggressive, disfiguring lesion invading bone and dura with intracranial extension within 3 months. The patient was treated with total surgical excision followed by systemic chemotherapy.

Keywords: *Diffuse large B-cell lymphoma, lymphoma excision, orbital lymphoma, orbital reconstruction*

Prabu Rau Sriram

*Department of Neurosurgery,
Queen Elizabeth Hospital, Kota
Kinabalu, Sabah, Malaysia*

Introduction

Orbital lymphoma is the most common orbital malignancy seen. However, primary orbital lymphoma is a rare entity. They mainly present as proptosis or eyelid swelling. It is generally regarded as slowly enlarging tumor. Radiotherapy and chemotherapy are treatment options in lymphoma while surgery has been reserved for obtaining tissue diagnosis and not recommended as standalone treatment. Histopathological subtypes have different behavior and prognosis. Diffuse large B-cell lymphoma (DLBCL) is known to be aggressive. Orbital lymphomas are seen and treated mainly by ophthalmologist and not many by neurosurgeons. This is indicated by a small amount of orbital lymphoma literature in neurosurgical journals. We report a patient who presented with a small nodular swelling, which grows in a couple of months to a size extending up to the nasal bridge and frontal bone with intracranial extension. This huge, aggressive, and extensive lesion is very disfiguring for the patient. An inconclusive frozen section has led to the doubt of sarcoma or other cancerous lesion; thus, total excision was done with reconstructive cranioplasty.

Case Report

A 45-year-old lady presented with left supraorbital firm swelling for 3 months

which started as a nodule of the size of a grain of rice. Swelling increases in size rapidly involving eyelid, entire orbit, and subsequently to the forehead. It also becomes intermittently painful. She started to lose her left eye vision gradually until it completely lost one month later. The patient presented to the ophthalmology clinic where further investigations were done. On examination, there was a huge soft to firm lesion involving entire left orbit extending to nasal bridge and forehead as shown in Figure 1. Right eye vision is 6/12 with no visual field loss but left eye completely blind. There is no nodal involvement or organomegaly. Further detailed investigations ruled out systemic involvement. Computed tomography (CT) orbit and CT brain done as shown in Figure 2. Due to the intracranial extension of the tumor, magnetic resonance imaging brain was done as shown in Figure 3 and the patient was referred to neurosurgical. The patient was planned for surgery electively 2 weeks later. On the day of admission 1 day before surgery, the tumor size has doubled compared to its size in clinic review 2 weeks prior. The patient subjected to craniotomy with total tumor excision and reconstructive cranioplasty approached through a bifrontal incision.

Intraoperatively, the tumor is fleshy, friable, well defined, and highly vascular. The tumor noted to originate from orbital adnexa but sparing the globe. There is an

Address for correspondence:

*Dr. Prabu Rau Sriram,
No. 17, Lorong Austral 11,
Austral Park, 88200 Kota
Kinabalu, Sabah, Malaysia.
E-mail: praburau@gmail.com*

Access this article online

Website: www.asianjns.org

DOI: 10.4103/1793-5482.185055

Quick Response Code:



How to cite this article: Sriram PR. A rare case of aggressive, huge primary orbital lymphoma with intracranial extension and bone invasion. *Asian J Neurosurg* 2017;12:766-8.

This is an open access article distributed under the terms of the Creative Commons Attribution-NonCommercial-ShareAlike 3.0 License, which allows others to remix, tweak, and build upon the work non-commercially, as long as the author is credited and the new creations are licensed under the identical terms.

For reprints contact: reprints@medknow.com

invasion of bone and dura over the frontal lobe with 2 cm by 2 cm intracranial extra-axial tumor in the left frontal convexity. The frozen section was sent intraoperatively and reported as malignant tumor unable to rule out lymphoma. Thus, complete excision of the tumor was done including the bone, dura, and the intracranial tumor. Nasal bridge, frontal bone, and left eye orbital wall completely eroded by tumor, thus, needing reconstructive cranioplasty with titanium mesh, nasal bridge repair with sugar mesh, and orbital wall repair with orbital mesh. Normal anatomical shape of orbit and skull restored.

Postoperation, the patient was extubated well with no new or worsening neurological deficit. CT brain done postsurgery as shown in Figure 4. Right eye vision still preserved. Histopathology finding reported as DLBCL of the orbit. The patient was referred to hemato-oncologist d

started on Cyclophosphamide, Doxorubicin, Vincristine, and Prednisolone regime chemotherapy.

Discussion

Orbital tumors can be benign or malignant and can arise from the globe or its adnexa. Orbital lymphoma is the most common malignant tumor found in the orbit ranging 4 to 13%.^[1,2] However, primary orbital lymphoma remains a rare entity, comprising only about 1% of non-Hodgkin lymphomas.^[3] Primary orbital lymphoma is when the patient presents with no other concurrent systemic lymphoma or prior history of lymphoma. It typically presents in patients older than 50 years which is almost similar to mean age group of orbital lymphoma in general who is 50–70 years old.^[1,3]

The common presentation of orbital lymphomas is eyelid mass, proptosis, globe displacement, diplopia, visual symptoms, and tearing.^[1,2] Gerbino *et al.* in his analysis of twenty orbital lymphomas, found 14 of them presents with proptosis while Madge *et al.* in 37 cases of DLBCL, found 51.4% present with orbital or eyelid mass. Orbital lymphomas are characterized by slow, enlarging, painless mass which is an opposite of what our patient present with.^[1]

The classification of lymphoma has been mainly histological base on the Revised European-American Lymphoma Classification, which takes into account molecular genetics,

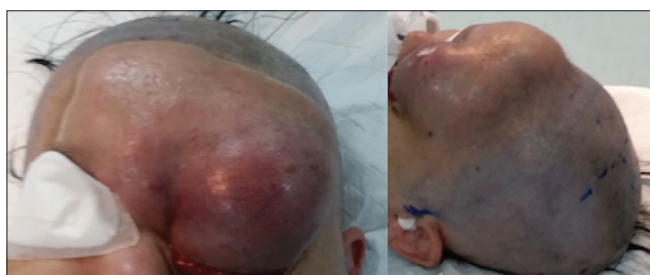

Figure 1: Photograph of the patient on the day of surgery taken with permission from the patient. Showing aggressive tumor from left orbit to frontal bone, nasal bridge, and right medial orbital wall

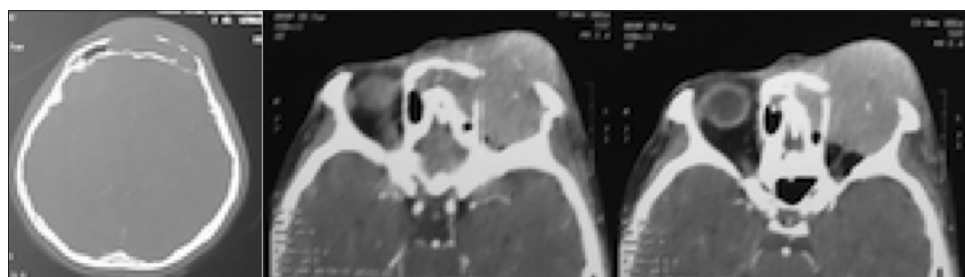


Figure 2: Computed tomography brain bone setting and computed tomography orbit showing left orbital aggressive lesion, contrast enhancing with retro-orbital extension involving left optic nerve and frontoethmoidal sinuses

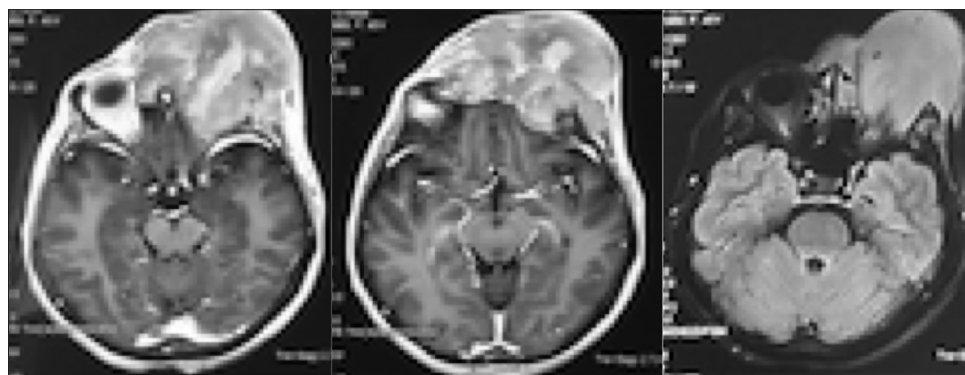


Figure 3: Magnetic resonance imaging T1 with gadolinium enhancement and fluid-attenuated inversion recovery sequence showing extensive tumor bigger than seen in computed tomography scan done in Figure 1. Intracranial extension of the tumor can be seen in this image. Tumor heterogeneously enhances and seen extending to left optic nerve and superior ophthalmic vein

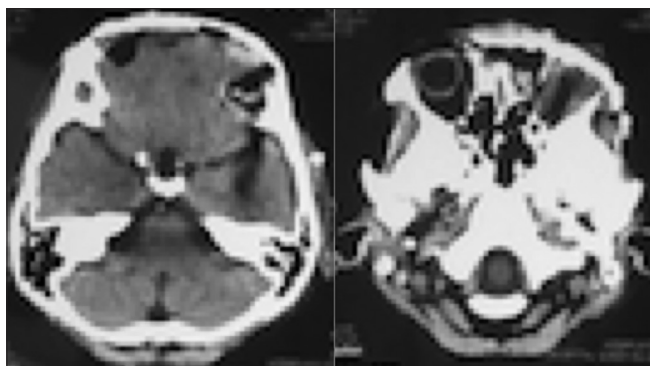


Figure 4: Postsurgery computed tomography brain showing titanium mesh reconstruction which has restored normal anatomy of the orbit and skull vault

immunophenotyping, and clinical grounds. DLBCL is one of the histological subtypes of lymphoma which represents about 7–21% of primary orbital lymphoma and 31% of non-Hodgkin lymphoma. Overall, DLBCL is known to be aggressive in behavior but responsive to treatment.^[4] Most common subtype in orbital adnexal lymphoma are extranodal marginal zone lymphoma of mucosa-associated lymphoid tissue (35–80%), followed by follicular lymphoma, DLBCL (8%), and less commonly mantle cell lymphoma, small lymphocytic lymphoma, and lymphoplasmacytic lymphoma.^[5,6]

No common consensus or guidelines available for orbital lymphoma. Especially primary malignant lymphoma with orbit and cranial vault involvement is a rare malignancy with controversial treatment.^[7] However, three modalities, which include surgical, radiotherapy, and chemotherapy, are an option either alone in combination. Choice of treatment differs based on the histological subtype, extent of disease, visual function, and disease-related prognostic factors. Surgical treatment as only treatment in lymphoma is not recommended due to the high rate of local relapse. Thus, surgical treatment mainly has been a tool to obtain diagnosis. Eckardt *et al.* reported 0% local relapse-free survival rate in 10 years with surgery alone. Some authors commented surgical treatment has no role in orbital lymphoma except for biopsy.^[5,6,8]

In our patient, surgery has been done with aim for total excision in view of the unconvincing report in the frozen section which has raised doubt of possibility of other malignant lesions, especially sarcomas in view of rapid growth of the tumor in a short period of time. Thus, complete excision was done to reduce the risk of metastases, seeding, and local growth in the event if histopathology reported as sarcomas. In addition, our patient has an extensive bony invasion of the tumor that has eroded frontal bone, orbital wall, and nasal bridge, which ultimately will need reconstruction surgery as what has been done in the same setting. Our patient has been then referred to hemato-oncologist where the patient

has been started on chemotherapy for local and systemic disease control. Agrawal *et al.* have reported a case of lymphoma involving orbit and cranial vault and has done wedge biopsy for their patient with a comment saying they could not proceed further due to the vascular tumor. In our patient, though we noted a highly vascular tumor as well, but the bleeding was under control, and thus, we managed to reach total excision.

Evaluation of orbital lymphoma includes systemic evaluation to look for other sites of lymphoma. In our patients, these evaluations were negative. Ann Arbor staging is widely used in orbital lymphoma for guiding treatment. In Stage I and Stage II, radiotherapy is the recommended treatment while chemotherapy is reserved for high-grade lesions or low-grade lesions with systemic involvement.

Conclusion

Primary orbital lymphoma can grow rapidly and aggressively, particularly those of DLBCL. They can even mimic aggressive cancerous tumors which can even be inconclusive in the frozen section. The important aspect of orbital lymphoma treatment remains radiotherapy or chemotherapy despite total excision achieved.

Financial support and sponsorship

Nil.

Conflicts of interest

There are no conflicts of interest.

References

1. Gerbino G, Boffano P, Benech R, Baietto F, Gallesio C, Arcuri F, *et al.* Orbital lymphomas: Clinical and radiological features. *J Craniomaxillofac Surg* 2014;42:508-12.
2. Madge SN, McCormick A, Patel I, Hatf E, Menon V, Prabhakaran VC, *et al.* Ocular adnexal diffuse large B-cell lymphoma: Local disease correlates with better outcomes. *Eye (Lond)* 2010;24:954-61.
3. Pelloski CE, Wilder RB, Ha CS, Hess MA, Cabanillas FF, Cox JD. Clinical stage IEA-IIEA orbital lymphomas: Outcomes in the era of modern staging and treatment. *Radiother Oncol* 2001;59:145-51.
4. Martelli M, Ferreri AJ, Agostinelli C, Di Rocco A, Pfreundschuh M, Pileri SA. Diffuse large B-cell lymphoma. *Crit Rev Oncol Hematol* 2013;87:146-71.
5. Tsen CL, Lin MC, Bee YS, Chen JL, Kuo NW, Sheu SJ. Ocular adnexal lymphoma: Five case reports and a literature review. *Taiwan Journal of Ophthalmology* 2015;5(2):99-102.
6. Yadav BS, Sharma SC. Orbital lymphoma: Role of radiation. *Indian J Ophthalmol* 2009;57:91-7.
7. Agrawal A, Sinha A. Lymphoma of frontotemporal region with massive bone destruction and intracranial and intraorbital extension. *J Cancer Res Ther* 2008;4:203-5.
8. Eckardt AM, Lemound J, Rana M, Gellrich NC. Orbital lymphoma: Diagnostic approach and treatment outcome. *World J Surg Oncol* 2013;11:73.