

Surgical treatment of large and giant cavernous carotid aneurysms

Kitiporn Sriamornrattanakul, Ittichai Sakarunchai¹, Kei Yamashiro², Yasuhiro Yamada², Daisuke Suyama², Tsukasa Kawase², Yoko Kato²

Department of Surgery, Division of Neurosurgery, Faculty of Medicine, Vajira Hospital, Navamindradhiraj University, Bangkok,

¹Department of Surgery, Division of Neurosurgery, Prince of Songkla University, Songkhla, Thailand,

²Department of Neurosurgery, Banbuntane Hotokukai Hospital, Fujita Health University, Nagoya, Japan

ABSTRACT

Cavernous carotid aneurysms (CCAs) are uncommon pathologic entities. Extradural place and the skull base location make this type of an aneurysm different in clinical features and treatment techniques. Direct aneurysm clipping is technically difficult and results in a significant postoperative neurological deficit. Therefore, several techniques of indirect surgical treatment were developed with different surgical outcomes, such as proximal occlusion of internal carotid artery (ICA) or trapping with or without bypass (superficial temporal artery-middle cerebral artery bypass or high-flow bypass). High-flow bypass with proximal ICA occlusion seems to be the most appropriate surgical treatment for CCA because of the high rate of symptom improvement, aneurysm thrombosis, and minimal postoperative complications. However, in cases of CCA presented with direct carotid-cavernous fistula, the appropriate surgical treatment is high-flow bypass with aneurysm trapping, which the fistula can be obliterated immediately after surgery.

Key words: Cavernous carotid aneurysm, giant aneurysm, high-flow bypass, intracavernous carotid aneurysm, large aneurysm, proximal occlusion, surgical treatment, trapping

Introduction

Cavernous carotid aneurysms (CCAs) are uncommon pathologic entities. Because they are located in extradural space, the clinical manifestation is different from other intradural aneurysms. Natural history usually benign if CCAs are small because of low risk of subarachnoid hemorrhage. Symptomatic and giant aneurysm usually manifest the symptoms and signs of mass effect to surrounding structures.^[1,2]

Furthermore, the appropriate treatment also differs from other types of aneurysms. Direct surgical obliteration with preservation of the parent artery is the ideal method for treatment, but may associate with significant neurological

morbidity. Therefore, several techniques of indirect surgical treatment have been developed with time to reduce neurological morbidity. The most appropriate treatment of an aneurysm is still controversial. This article mostly aims to review the surgical treatments and their outcomes.^[2]

Epidemiology

CCA account for between 3% and 5% of all intracranial (IC) aneurysms and 14% of all internal carotid artery (ICA) aneurysms. CCAs may be classified into three subdivisions by the size of aneurysm dome as small (<10 mm), large (10–25 mm), and giant (>25 mm).^[1,2]

The etiology of CCA may be infectious, traumatic, or idiopathic. The most common etiology for CCA is idiopathic. The rate of rupture of such aneurysms may correlate with their size.^[2]

This is an open access article distributed under the terms of the Creative Commons Attribution-NonCommercial-ShareAlike 3.0 License, which allows others to remix, tweak, and build upon the work non-commercially, as long as the author is credited and the new creations are licensed under the identical terms.

For reprints contact: reprints@medknow.com

Access this article online	
Quick Response Code:	Website: www.asianjns.org
	DOI: 10.4103/1793-5482.180930

Address for correspondence:

Dr. Kitiporn Sriamornrattanakul, Department of Surgery, Division of Neurosurgery, Faculty of Medicine, Vajira Hospital, Navamindradhiraj University, Bangkok, Thailand.
E-mail: kengkitiporn@yahoo.com

How to cite this article: Sriamornrattanakul K, Sakarunchai I, Yamashiro K, Yamada Y, Suyama D, Kawase T, *et al.* Surgical treatment of large and giant cavernous carotid aneurysms. *Asian J Neurosurg* 2017;12:382-8.

Clinical Presentation

Because CCAs are located in extradural space and hard surrounding structures of the cavernous sinus dura, they have a very small risk of subarachnoid hemorrhage. However, they can grow larger in size, and can present with symptoms of mass effect on cranial nerves, such as ophthalmoplegia and facial pain or numbness.^[3] Rarely, they may also compress the optic nerve leading to subsequent loss of vision.^[4]

Spontaneous intramural thrombosis of giant IC aneurysms occurs in 13–20% of cases.^[5] Furthermore, there are reports of 17 cases associated with simultaneous thrombosis of giant CCA with ipsilateral ICA occlusion.^[6]

Difference in the direction of aneurysm extension can cause different clinical manifestations. More anterior extension through the superior orbital fissure leads to proptosis and optic nerve compression with the resultant monocular visual loss. More lateral extension causes compression of the left perisylvian cortex leading to dysarthria. Medial extension results in compression of the optic nerve leading to visual impairment.^[6]

In five reported patients with a CCA causing acute subdural hemorrhage, the size of the aneurysm was giant and cranial nerve signs preceded the rupture. A possible mechanism was a cavernous aneurysm breaks the weak part of cavernous sinus dura, which is associated with the cranial nerve passages.^[7-11]

Rupture of CCA may result in direct carotid-cavernous fistula (CCF) causing severe neuro-ophthalmological symptoms. The acutely worsening neuro-ophthalmologic symptoms are caused by the direct CCF with the resultant engorged left superior orbital fissure. Furthermore, a CCA rupture can cause intracerebral hemorrhage due to cortical venous drainage or subarachnoid hemorrhage if the aneurysm ruptures into the subarachnoid space, thereby disrupting the normal confines of the cavernous sinus dura.^[12]

A subarachnoid hemorrhage may occur in 0–16% of CCAs.^[13,14] The possible causes of subarachnoid hemorrhage from CCA include growing of the CCA into subarachnoid space, direct erosion of cavernous sinus wall, and erosion into sellar turcica causing communication between cavernous sinus and subarachnoid space through diaphragm sellae. Also, Linskey *et al.* report that aneurysms arising from anterior genu of ICA may have a higher risk for subarachnoid hemorrhages.^[13]

Epistaxis may be caused by direct rupture of a CCA into the sphenoid sinus. The majority of CCAs have a thin shell of bone separating them from the sphenoid sinus, and in 4% of the specimens, no bone separation is present.^[15]

Clinical presentations of CCA have been summarized in Table 1.^[3-7,12-15]

Indications for Treatment

The risks and benefits of treatment of CCA should be carefully considered because CCAs are not a common pathology, and there are no definite guidelines for treatment currently. Furthermore, data about the natural history and pathogenesis of CCA is limited. Indications for treatment of CCA are summarized in Table 2.^[2,13]

Surgical Treatment and Outcome

In general treatment for aneurysm, direct occlusion of the aneurysm with parent artery preservation is the best method.

As for the open surgical approaches, direct clipping of CCAs^[16,17] is extremely challenging and difficult, given the complex surrounding venous structures and cranial nerves. For example, it is nearly impossible to avoid manipulating/injuring the cranial nerves when creating a direct surgical corridor for aneurysm clipping. This results in a significant postoperative neurological deficit. In addition, lengthy temporal occlusion and multiple complex clipping are necessary for direct clipping of such aneurysms, leading to a risk of devastating distal ischemia.

Table 1: Clinical presentations of cavernous carotid aneurysms

Clinical presentations of cavernous carotid aneurysm

Mass effect on cranial nerves
Ptosis
Ophthalmoparesis
Facial pain or numbness
Visual disturbance
Dysarthria
Acute subdural hematoma
Subarachnoid hemorrhage
Intracerebral hemorrhage
Direct carotid-cavernous fistula causing acute loss of vision
Epistaxis

Table 2: Indications for treatment of cavernous carotid aneurysms

Indications for treatment of cavernous carotid aneurysms

Asymptomatic aneurysms
Extension of aneurysm into subarachnoid space
Extension of aneurysm into sphenoid sinus
Origin from anterior genu of cavernous carotid
Radiographic enlargement of aneurysm
Symptomatic aneurysms
Subarachnoid hemorrhage
Epistaxis
Unbearable ipsilateral face or retro-orbital pain
Progressive ophthalmoplegia
Progressive visual loss
Sudden, severe ophthalmoplegia

In contrast, distal bypass with parent vessel occlusion can completely exclude the aneurysms from the circulation, promptly inducing thrombosis inside aneurysms, and can be performed with predictable ischemic time and a relatively low complication rate, obviating the dangers associated with direct complex aneurysm manipulation.^[12,18]

Currently, several techniques for indirect treatment of giant CCA have been reported. Such techniques include ICA occlusion (direct ligation or gradual occlusion using Selverstone clamp), superficial temporal artery-middle cerebral artery (STA-MCA) bypass with ICA occlusion, trapping, and high-flow bypass with ICA occlusion or trapping.

Little *et al.*^[19] reported 15 cases of symptomatic CCA were treated with different methods of ICA occlusion without high-flow bypass. Good results were achieved in most cases, but delayed ipsilateral cerebral ischemia was found in two cases (13%), and partial retrograde filling of the aneurysm was demonstrated in three cases.

Niuro *et al.*^[20] reported 11 cases of large or giant CCA treated by gradual occlusion of ICA or common carotid artery by Selverstone clamping without extracranial-IC bypass. Early and delayed ischemic events in the ipsilateral side of carotid occlusion occurred in three cases (27.3%), with 9.1% permanent morbidity and 36.4% temporary morbidity. Two cases (18%) developed new formations of an aneurysm at other sites (*de novo* aneurysm) in the long-term due to chronic hemodynamic stress, which are located at the contralateral cavernous carotid artery and anterior communicating artery.

Ishikawa *et al.*^[21] reported one case of giant CCA treated by high-flow bypass with trapping. Preoperative balloon Matas test was not performed. The insufficient blood flow from STA-MCA double bypass was detected by somatosensory evoked potential (disappearance of N20 100 min after ICA occlusion).

In 2007, Murai *et al.*^[22] reported 17 patients with giant or large complex ICA aneurysm (4 cases located in paraclinoid region, 13 cases in the cavernous segment) between September 1997 and October 2005. Radial artery grafting (RAG) followed immediately by parent artery occlusion was performed in all cases of CCA (only proximal ligation in nine cases, trapping in four cases). Postoperative angiography was performed. All 17 aneurysms were excluded from the cerebral circulation, with all RAGs patent. Cranial nerve dysfunction (III and VI) caused by altered blood flow from the ICA after occlusion was the most common complication (three cases in CCA) and typically was temporary.

Houkin *et al.*^[23] reported 36 patients with giant or large aneurysms located at the cavernous portion of the ICA with ocular nerve signs, which were treated by ligation and reconstruction of the ICA with an RAG bypass between

1989 and 1998. Postoperative angiography showed patency of bypass graft in 97% (35 cases). One patient with bypass graft occlusion who presented with cerebral infarction recovered within 1 month. No ischemic symptoms or cerebral hyperperfusion syndrome showed in patients with good patency of bypass graft. The ocular symptom improved in all patients. Aneurysms disappeared and thrombosed on postoperative angiography and magnetic resonance imaging, respectively.

The cervical ICA was ligated (proximal ligation of parent artery) immediately after the opening of the RAG. In the early cases in this series, the IC ICA was ligated proximally to the origin of the ophthalmic artery (distal outflow occlusion for trapping the aneurysm). To occlude such IC ICA with clip, anterior clinoidectomy is often performed for ophthalmic artery origin identification.^[23]

However, the authors found that most of the aneurysms would spontaneously thrombose after proximal ligation without the distal outflow occlusion, even after just the RAG. Therefore, in most cases in this series, the IC portion of the ICA was not occluded (only proximal ligation of cervical ICA was performed). The anterior clinoidectomy was not necessary [Figure 1].^[23,24]

In 2011, Murai *et al.*^[25] reported eight elderly patients with large or giant symptomatic CCA (all patients age over 70 years). High-flow bypass (using RAG) surgery was performed in all the patients for the surgical ligation of the ICA. After the operation, aneurysms completely thrombosed in all cases, and the improvement of presenting symptoms was achieved in 87.5%. One patient had a postoperative small area of cerebral infarction at the ipsilateral frontal lobe, which resulted in transient dysarthria and gait disturbance, and another patient developed convulsive seizures, which had been attributed to the postoperative hyperperfusion syndrome.

Shimizu *et al.*^[26] reported large or giant CCA treated with cervical ICA occlusion (ligation or coil embolization) with or without bypass (STA-MCA or high-flow bypass) depending on balloon test occlusion (BTO) and single photon emission computed tomography. Postoperative ischemia occurred in 16.7%, all were embolic in origin. Complete aneurysm occlusion was demonstrated in all cases.

The amount of patients, treatment techniques, outcomes, and postoperative complications of six case series are summarized in Table 3.^[19,20,22,23,25,26]

The mechanism of CCA thrombosis after proximal occlusion of ICA is still unknown. Some authors report many cases of aneurysm treatment with parent artery occlusion using “blind-alley formation” strategy (making the aneurysm lumen “a blind-alley” by obliteration of all but one artery around the aneurysm).^[27-29] Takahashi *et al.*^[27] reported using “blind-alley”

formation technique to treat giant partially thrombosed basilar tip aneurysm that failed to completely thrombose with proximal parent artery occlusion. Unsuccessful treatment of a partially thrombosed giant basilar tip aneurysm with proximal occlusion is caused by blood flow from bilateral posterior communicating artery in first operation [Figure 2a]. The aneurysm become “blind-alley formation” by additional clipping (purple) and bypass [Figure 2b]. Postoperative imaging showed complete aneurysm obliteration [Figure 2]. Miyamoto *et al.*^[28] reported “maximal flow reduction strategy,” in which the configuration of the aneurysm was transformed into a “blind-alley” formation, to treat giant partially thrombosed basilar tip aneurysm in two patients. Complete aneurysm thrombosis was demonstrated after operation in both cases [Figure 3]. Shimizu *et al.*^[29] reported the successful “blind-alley” formation technique to treat three patients with unclippable ophthalmic segments and supraclinoid segments of ICA aneurysms [Figure 4].^[29]

According to the anatomical relationship of CCA, ophthalmic artery, and ICA, the aneurysm thrombosis after

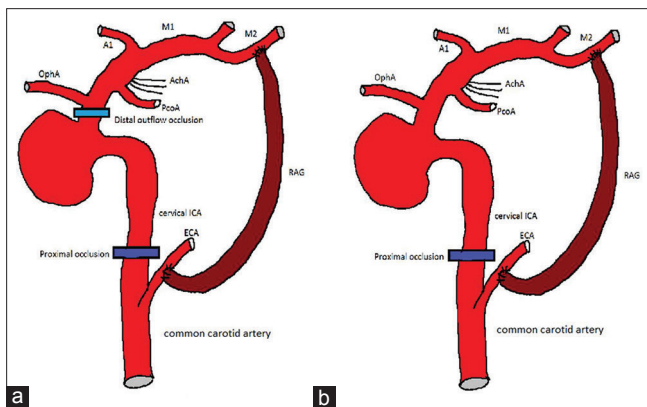


Figure 1: (a) Trapping (cervical internal carotid artery ligation with clipping of C3 segment of internal carotid artery, just proximal to ophthalmic artery origin) of cavernous carotid aneurysm with high-flow bypass. (b) Cervical internal carotid artery ligation with high-flow bypass. Both techniques result in the complete aneurysm thrombosis. First segment of anterior cerebral artery (A1), anterior choroidal artery, first segment of middle cerebral artery (M1), second segment of middle cerebral artery (M2), ophthalmic artery (OphA), posterior communicating artery (PcoA), and radial artery graft (RAG)

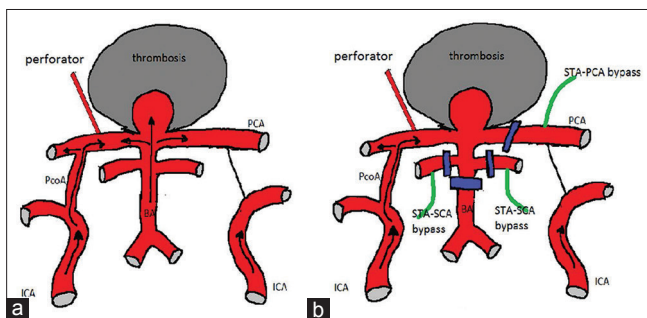


Figure 3: (a) A partially thrombosed giant basilar tip aneurysm. (b) The maximal flow reduction strategy (“blind-alley formation”) (modified from Miyamoto *et al.*)

proximal occlusion of ICA may be explained by the same mechanism (“blind-alley” formation) as the aforementioned three case report [Figure 5].

In reports of three patients with ruptured CCA causing acute subdural hemorrhage undergoing surgery, ICA occlusion was selected to treat the aneurysms.^[7,8,11] In one case with high-flow bypass and ICA ligation, the right abducens nerve palsy improved, although the oculomotor nerve palsy remained postoperatively. This patient was discharged 4 weeks after admission and returned to her previous life.^[7] Two patients had ICA occlusion performed without bypass surgery. Cerebral infarction occurred causing transient hemiparesis.^[8,11]

In an aspect of the indication for revascularization when ICA is sacrificed, many authors take the position of “selective revascularization” that is, the occlusion of the ICA, with or without bypass, depending on the cross-flow, as well as results of BTO.^[26,30]

Some authors think that the cumulative risks of not performing revascularization in patients who tolerate ICA balloon occlusion (risk of BTO itself 3.7–7%,^[31,32] false negative rate of BTO 7–22%) exceed the surgical risk of revascularization (3–7%). Furthermore, the delayed risk of arterial occlusion without revascularization is *de novo* formation (new aneurysm formation) of aneurysms (0–10%) due to hemodynamic stress. They, therefore, favor revascularization in all patients who

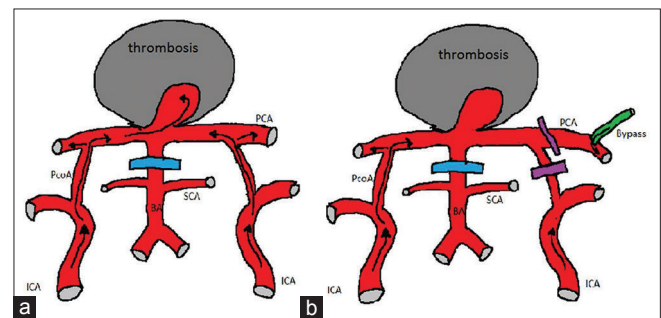


Figure 2: Modified from Takahashi *et al.* (a) first operation. (b) second operation for “blind-alley formation”. Basilar artery (BA), superior cerebellar artery (SCA)

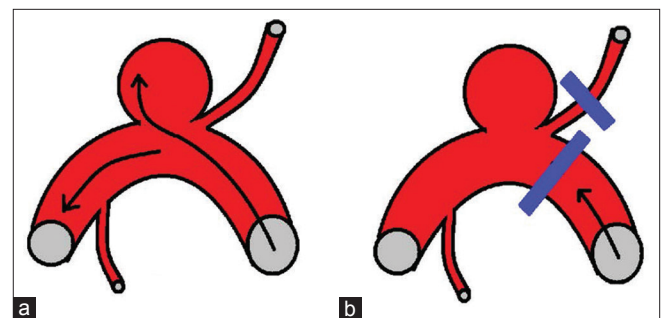


Figure 4: Scheme demonstrates (a) aneurysm and (b) treatment using “blind-alley formation” strategy (modified from Shimizu *et al.*)

Table 3: Summary of indirect surgical treatment and outcome of large or giant cavernous carotid aneurysms

Author	No. of cases	Surgical technique	Symptom improve	% of complete aneurysm thrombosis	% of postoperative ipsilateral ischemic stroke	Other complication
Little <i>et al.</i> 1989	15	Selverstone clamp occlusion of ICA over 24 hr. (8 cases) ICA ligation (1 case) Aneurysm trapping (4 cases) STA-MCA bypass with Selverstone clamp occlusion of ICA over 24 hr. (2 cases)	33% (60% not change) *30 days after surgery	78.6%	2/15 cases (13%) One case for STA-MCA bypass with Selverstone clamp occlusion One for ICA ligation) *Mean follow-up period 5.6 years	CN3, CN5 palsy 2/15 cases
Houkin <i>et al.</i> 1999	36	ECA-RA-MCA bypass with cervical ICA ligation → most cases ECA-RA-MCA bypass with trapping (cervical ICA ligation and ICA clipping just proximal to OphA origin) → few cases	100%	100%	1/36 cases (2.8%) RA graft occlusion *Mean follow-up period 7.2 years	No
Niiri <i>et al.</i> 2000	11	Selverstone clamp occlusion of Common carotid artery with ECA ligation (8 cases) ICA (3 cases)	72.7%	100%	3/11 cases (27.3%) Early 1 case Delayed 2 cases *Mean follow-up period 13.9 years	De novo aneurysm formation (2 cases, contralateral CCA and Acom) Ruptured Acom aneurysm (1 case) Delayed re-enlargement of CCA (2 cases)
Murai <i>et al.</i> 2007	13	ECA-RA-MCA bypass with Cervical ICA occlusion (9 cases) Trapping (4 cases)	61.5%	100%	0% *Mean follow up period 5.2 years	CN3,6 palsy (3/13 cases)
Shimizu <i>et al.</i> 2010	12	Cervical ICA occlusion (ligation or coil embolization) with High flow bypass (6 cases) STA-MCA bypass (4 cases) No bypass (2 cases) Depend on BTO and SPECT	66.7%	100%	2/12 cases (16.7%) Both are embolic stroke One case is asymptomatic	CN2 (1 case) CN3,4 (2 cases) CN3,4,6 (1 case) CN6 (1 case)
Murai <i>et al.</i> 2011	8 (all cases >70 year)	ECA-RA-MCA bypass with cervical ICA occlusion	87.5%	100%	1/8 cases (12.5%) A small ipsilateral frontal ischemia (transient dysarthria and gait disturbance) *Mean follow-up period 3.15 years	CN4 (1 case) Epilepsy due to hyperperfusion syndrome (1 case)

Acom – Anterior communicating artery; BTO – Balloon test occlusion; CN – Cranial nerve; ECA – External carotid artery; ICA – Internal carotid artery; MCA – Middle cerebral artery; RA – Radial artery; STA – Superficial temporal artery; VA – Vertebral artery

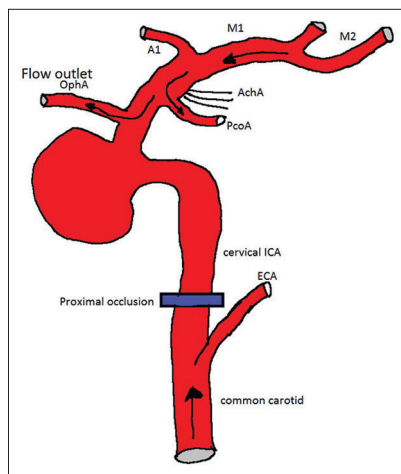


Figure 5: Scheme demonstrates the thrombosis of cavernous carotid aneurysm by proximal internal carotid artery occlusion as “blind-alley formation” strategy

have undergone occlusion of a parent vessel for treatment of complex aneurysms (“universal revascularization”).^[33-35]

In the case of ruptured CCA causing direct CCF, Hasegawa *et al.*^[12] reported urgent treatment with high-flow bypass followed by trapping the aneurysm (cervical ICA ligation and distal outflow clipping at C3 segment of ICA, proximal to origin of ophthalmic artery) to completely control bleeding from aneurysm to cavernous sinus. The progressive visual decline, papilledema, and refractory elevation of the intraocular pressure are all indications for emergent intervention [Figure 6].^[36] The great benefit of direct surgical repair is that trapping of the aneurysm can successfully occlude the aneurysm and fistula without causing any mass effect, leading to an immediate decrease of intracavernous sinus pressure, which results in rapid and complete resolution of neuro-ophthalmic symptoms.^[12]

Endovascular Treatment

Recently, endovascular techniques have been developed to treat CCA, which included intra-aneurysmal coil embolization with or without stent or balloon-assist, and flow-diverting stent.

Morita *et al.*^[37] performed intra-aneurysmal coil embolization in seven patients with large or giant symptomatic CCA. After the operation, one patient improved the symptoms of aneurysmal mass effect, two patients unchanged and four patients deteriorated. They concluded that intra-aneurysmal coil embolization is not an effective treatment option for large or giant CCA.

According to a recent report, a flow diverting stent has been developed for the effective treatment of an unruptured giant symptomatic CCA;^[38] however, early,^[39] and delayed^[40,41] rupture of the aneurysm after treatment has been described. The incidence delayed ruptured of an aneurysm after the stent is 0.6–1%, but was not reported for early rupture. The risk factor is aneurysm size 10 mm or larger.^[40]

Stent- or balloon-assisted endovascular treatment of saccular aneurysm resulted in acceptable short-term occlusion, but the recanalization rate remained as high as 20% for small and up to 46% for large aneurysms requiring a high number of retreatment.^[39]

In cases of a ruptured aneurysm with flow diverting stent treatment, the blood flow entered the aneurysm sac continuously without intra-aneurysmal pressure reduction immediately after device deployment. Furthermore, it was necessary to use the antiplatelet agent during the perioperative period after stenting. Therefore, prompt prevention of the aneurysmal re-rupture could not be obtained.^[42]

In cases with direct CCF, the fistula occlusion via an endovascular approach was the treatment of choice. In general, direct CCF due to ruptured CCAs progressed rapidly and required urgent treatment. The progressive visual decline, papilledema, and refractory elevation of the intraocular pressure were all indications for emergent intervention. However, endovascular management was not always available on an urgent basis in some institutes and was not always successful, in which case direct

surgical trapping of the lesion and distal bypass might be indicated.^[12]

Conservative Treatment

Spontaneous intramural thrombosis of giant IC aneurysms occurs in between 13% and 20% of cases.^[5]

Few cases of spontaneous ICA occlusion with giant CCA thrombosis was reported in 17 cases from 10 different centers. Many hypotheses have been proposed by authors to explain the simultaneous occurrence of ICA occlusion and cavernous aneurysm. Three of such theories include direct stretch and compression of the parent artery by the giant aneurysm, proximal propagation of an intramural thrombus, or compression of the ICA against the anterior clinoid process.^[6]

Many reports suggest that there is definitely a subset of these patients with giant cavernous ICA aneurysms who undergo spontaneous occlusion of the feeding vessel. Therefore, Sastri *et al.* believe there is a role for conservative management in patients who are not acutely and severely symptomatic and fail BTO.^[6]

Conclusion

Several surgical techniques for treatment of large or giant CCA with results were reviewed in this article.

For CCA with mass effect, high-flow bypass with proximal occlusion of ICA (without trapping) seems to be the first choice treatment for large and giant CCA because of the high rate of aneurysm thrombosis and significant improvement of symptoms.

However, in cases of direct CCF caused by ruptured CCA, high-flow bypass with aneurysm trapping seems to be the most effective option for patients with rapid progressive visual loss.

Financial support and sponsorship

Nil.

Conflicts of interest

There are no conflicts of interest.

References

1. Mikabe T, Ogihara R, Tomita S, Kin H, Karasawa H, Watanabe S, *et al.* Giant intracranial aneurysm visualized by prolonged injection angiography – Case report (author's transl). *No Shinkei Geka* 1980;8:749-53.
2. Russell SM, Jafar JJ. Microsurgical treatment of intracavernous carotid artery aneurysms. In: Le Roux PD, Winn RH, Newell DW, editors. *Management of Cerebral Aneurysms*. Philadelphia: Saunders; 2004. p. 711-29.
3. Hahn CD, Nicolle DA, Lownie SP, Drake CG. Giant cavernous carotid aneurysms: Clinical presentation in fifty-seven cases. *J Neuroophthalmol* 2000;20:253-8.
4. Silva MN, Saeki N, Hirai S, Yamaura A. Unusual cranial nerve palsy caused by cavernous sinus aneurysms. *Clinical and anatomical considerations reviewed*. *Surg Neurol* 1999;52:143-8.
5. Whittle IR, Williams DB, Halmagyi GM, Besser M. Spontaneous

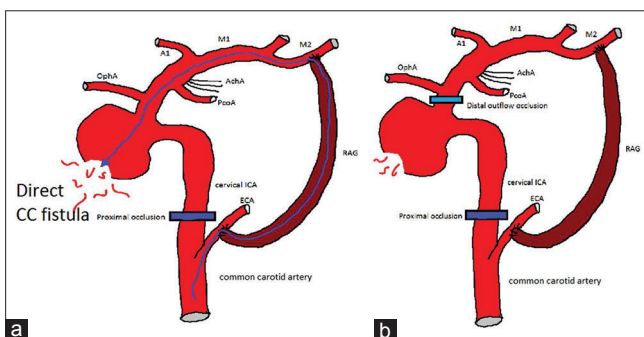


Figure 6: Surgical treatment of cavernous carotid aneurysm presented with direct carotid-cavernous fistula. (a) By only proximal internal carotid artery occlusion, the fistula was not obliterated completely. (b) Complete obliteration of carotid-cavernous fistula accomplished by trapping of the aneurysm was able to immediately decrease blood flow to the fistula

- thrombosis of a giant intracranial aneurysm and ipsilateral internal carotid artery. Case report. *J Neurosurg* 1982;56:287-9.
6. Sastri SB, Sadasiva N, Pandey P. Giant cavernous carotid aneurysm with spontaneous ipsilateral ICA occlusion: Report of 2 cases and review of literature. *J Neurosci Rural Pract* 2013;4 Suppl 1:S113-6.
 7. Shigematsu H, Sorimachi T, Aoki R, Osada T, Srivatanakul K, Matsumae M. Acute subdural hematoma caused by a ruptured cavernous internal carotid artery giant aneurysm following abducens nerve palsy: Case report and review of the literature. *Acta Neurochir (Wien)* 2015;157:1113-6.
 8. Andaluz N, Tomsick TA, Keller JT, Zuccarello M. Subdural hemorrhage in the posterior fossa caused by a ruptured cavernous carotid artery aneurysm after a balloon occlusion test. Case report. *J Neurosurg* 2006;105:315-9.
 9. Barr HW, Blackwood W, Meadows SP. Intracavernous carotid aneurysms. A clinical-pathological report. *Brain* 1971;94:607-22.
 10. Hodes JE, Fletcher WA, Goodman DF, Hoyt WF. Rupture of cavernous carotid artery aneurysm causing subdural hematoma and death. Case report. *J Neurosurg* 1988;69:617-9.
 11. McLaughlin MR, Jho HD, Kwon Y. Acute subdural hematoma caused by a ruptured giant intracavernous aneurysm: Case report. *Neurosurgery* 1996;38:388-92.
 12. Hasegawa H, Inoue T, Tamura A, Saito I. Urgent treatment of severe symptomatic direct carotid cavernous fistula caused by ruptured cavernous internal carotid artery aneurysm using high-flow bypass, proximal ligation, and direct distal clipping: Technical case report. *Surg Neurol Int* 2014;5:49.
 13. Linskey ME, Sekhar LN, Hirsch WL Jr., Yonas H, Horton JA. Aneurysms of the intracavernous carotid artery: Natural history and indications for treatment. *Neurosurgery* 1990;26:933-7.
 14. Diaz FG, Ohaegbulam S, Dujovny M, Ausman JJ. Surgical alternatives in the treatment of cavernous sinus aneurysms. *J Neurosurg* 1989;71:846-53.
 15. Inoue T, Rhoton AL Jr., Theele D, Barry ME. Surgical approaches to the cavernous sinus: A microsurgical study. *Neurosurgery* 1990;26:903-32.
 16. Dolenc VV. A combined epi- and subdural direct approach to carotid-ophthalmic artery aneurysms. *J Neurosurg* 1985;62:667-72.
 17. Sekhar LN, Burgess J, Akin O. Anatomical study of the cavernous sinus emphasizing operative approaches and related vascular and neural reconstruction. *Neurosurgery* 1987;21:806-16.
 18. Sughrue ME, Saloner D, Rayz VL, Lawton MT. Giant intracranial aneurysms: Evolution of management in a contemporary surgical series. *Neurosurgery* 2011;69:1261-70.
 19. Little JR, Rosenfeld JV, Awad IA. Internal carotid artery occlusion for cavernous segment aneurysm. *Neurosurgery* 1989;25:398-404.
 20. Niiro M, Shimozuru T, Nakamura K, Kadota K, Kuratsu J. Long-term follow-up study of patients with cavernous sinus aneurysm treated by proximal occlusion. *Neurol Med Chir (Tokyo)* 2000;40:88-96.
 21. Ishikawa T, Kamiyama H, Tada M, Ihara T, Abe H. Giant internal carotid aneurysm at the cavernous portion with abrupt disappearance of N20 100 minutes after carotid occlusion – case report. *Neurol Med Chir (Tokyo)* 1990;30:417-21.
 22. Murai Y, Teramoto A, Mizunari T, Kobayashi S, Kamiyama H. Treatment of complex internal carotid artery aneurysm using radial artery grafts. *Surg Cereb Stroke* 2007;35:387-93.
 23. Houkin K, Kamiyama H, Kuroda S, Ishikawa T, Takahashi A, Abe H. Long-term patency of radial artery graft bypass for reconstruction of the internal carotid artery. Technical note. *J Neurosurg* 1999;90:786-90.
 24. Kamiyama H. Bypass with radial artery graft. *No Shinkei Geka* 1994;22:911-24.
 25. Murai Y, Mizunari T, Umeoka K, Tateyama K, Kobayashi S, Teramoto A. Radial artery grafts for symptomatic cavernous carotid aneurysms in elderly patients. *Neurol India* 2011;59:537-41.
 26. Shimizu H, Matsumoto Y, Tominaga T. Parent artery occlusion with bypass surgery for the treatment of internal carotid artery aneurysms: Clinical and hemodynamic results. *Clin Neurol Neurosurg* 2010;112:32-9.
 27. Takahashi JC, Murao K, Iihara K, Nonaka Y, Taki J, Nagata I, *et al.* Successful “blind-alley” formation with bypass surgery for a partially thrombosed giant basilar artery tip aneurysm refractory to upper basilar artery obliteration. Case report. *J Neurosurg* 2007;106:484-7.
 28. Miyamoto S, Funaki T, Iihara K, Takahashi JC. Successful obliteration and shrinkage of giant partially thrombosed basilar artery aneurysms through a tailored flow reduction strategy with bypass surgery. *J Neurosurg* 2011;114:1028-36.
 29. Shimizu H, Endo H, Inoue T, Fijimura M, Matsumoto Y, Tominaga T. Surgical treatment of internal carotid artery aneurysms requiring strategic selective clipping or parent artery occlusion/flow alteration. *Jpn J Neurosurg* 2014;23:721-8.
 30. Kupersmith MJ, Hurst R, Berenstein A, Choi IS, Jafar J, Ransohoff J. The benign course of cavernous carotid artery aneurysms. *J Neurosurg* 1992;77:690-3.
 31. Tarr RW, Jungreis CA, Horton JA, Pentheny S, Sekhar LN, Sen C, *et al.* Complications of preoperative balloon test occlusion of the internal carotid arteries: Experience in 300 cases. *Skull Base Surg* 1991;1:240-4.
 32. Origitano TC, al-Mefty O, Leonetti JP, DeMonte F, Reichman OH. Vascular considerations and complications in cranial base surgery. *Neurosurgery* 1994;35:351-62.
 33. Lawton MT, Hamilton MG, Morcos JJ, Spetzler RF. Revascularization and aneurysm surgery: Current techniques, indications, and outcome. *Neurosurgery* 1996;38:83-92.
 34. Ishishita Y, Tanikawa R, Noda K, Kubota H, Izumi N, Katsuno M, *et al.* Universal extracranial-intracranial graft bypass for large or giant internal carotid aneurysms: Techniques and results in 38 consecutive patients. *World Neurosurg* 2014;82:130-9.
 35. Javedan SP, Deshmukh VR, Spetzler RF, Zabramski JM. The role of cerebral revascularization in patients with intracranial aneurysms. *Neurosurg Clin N Am* 2001;12:541-55, viii.
 36. Ellis JA, Goldstein H, Connolly ES Jr., Meyers PM. Carotid-cavernous fistulas. *Neurosurg Focus* 2012;32:E9.
 37. Morita K, Sorimachi T, Ito Y, Nishino K, Jimbo Y, Kumagai T, *et al.* Intra-aneurysmal coil embolization for large or giant carotid artery aneurysms in the cavernous sinus. *Neurol Med Chir (Tokyo)* 2011;51:762-6.
 38. Szikora I, Berentei Z, Kulcsar Z, Marosfoi M, Vajda ZS, Lee W, *et al.* Treatment of intracranial aneurysms by functional reconstruction of the parent artery: The Budapest experience with the pipeline embolization device. *AJNR Am J Neuroradiol* 2010;31:1139-47.
 39. Turowski B, Macht S, Kulcsár Z, Hänggi D, Stummer W. Early fatal hemorrhage after endovascular cerebral aneurysm treatment with a flow diverter (SILK-Stent): Do we need to rethink our concepts? *Neuroradiology* 2011;53:37-41.
 40. Lin LM, Colby GP, Jiang B, Pero G, Boccardi E, Coon AL. Transvenous approach for the treatment of direct carotid cavernous fistula following pipeline embolization of cavernous carotid aneurysm: A report of two cases and review of the literature. *BMJ Case Rep* 2014;2014. pii: Bcr2014011235.
 41. Kallmes D, Boccardi E, Bonafe A, Cekirge S, Fiorella D, Hanel R, *et al.* O-009 Safety of flow diversion: Results from a multicentre registry. *J Neurointerv Surg* 2013;5 Suppl 2:A6. [Abstr].
 42. Schneiders JJ, VanBavel E, Majoie CB, Ferns SP, van den Berg R. A flow-diverting stent is not a pressure-diverting stent. *AJNR Am J Neuroradiol* 2013;34:E1-4.