

Computed tomographic study of posterior cranial fossa, foramen magnum, and its surgical implications in Chiari malformations

Showkathali Iqbal, Ambooken P. Robert¹, Dominic Mathew¹

Departments of Anatomy and ¹Radiodiagnosis, Amala Institute of Medical Sciences, Thrissur, Kerala, India

ABSTRACT

Objective: The aim of this study is to measure the height and volume of the bony part of the posterior cranial fossa (PCF) and the surface area of the foramen magnum (FM) using computed tomography (CT) scans and to correlate our clinical findings with the available current literature.

Materials and Methods: This cross-sectional study was conducted in a tertiary care referral hospital in the Southern part of India during the period from January 2015 to August 2015. A total of 100 CT scans of the suspected head injury patients were collected retrospectively form the basis for this study. The height, volume of PCF and the anteroposterior (AP), transverse diameter, and surface area of the FM were measured. The values of all parameters were subjected to statistical analysis using SPSS version 16.

Results: The age of the patients were ranged between 18 and 70 years with the mean age of 41.22 ± 13.93 years. The dimensions of the posterior fossa and FM were larger in males compared to females. The mean height of the posterior fossa was $38.08 (\pm 4.718)$ mm ($P = 0.0001$), and the mean volume of the posterior fossa was $157.23 (\pm 6.700)$ mm³ ($P = 0.0001$). The mean AP, transverse diameter, and the surface area of the FM were $33.13 (\pm 3.286)$ mm, $29.01 (\pm 3.081)$ mm, and $763.803 (\pm 138.276)$ mm², respectively.

Conclusion: The normal dimensions of the posterior fossa and FM were less in females than males and were useful to radiologists and neurosurgeons to better their diagnostic inferences, as well as to determine the proper treatment options in Chiari malformation type I (CMI) and other posterior fossa anomalies. The posterior fossa tissue volume can be reliably measured in patients with CMI using our method. More studies were required because there were variations in dimensions among individuals of different races in different regions of the world.

Key words: Chiari malformation type I, computed tomography scans, foramen magnum, posterior cranial fossa

Introduction

The posterior cranial fossa (PCF) is a compact and rigid space with poor compliance. Even a small increase in the volumes within PCF, either in the form of tumor or hematoma can result in a significant increase in the intracompartmental pressure,

leading to a life-threatening brain stem compression. The PCF is the deepest cranial fossa and is bounded by dorsum sellae and basilar part of occipital bone anteriorly, petromastoid parts of temporal bone laterally, tentorium cerebelli, superiorly, and the occipital bone posteroinferiorly. The foramen magnum (FM) in the occipital bone is the largest opening in the posterior fossa and transmits important neurovascular structures. The brain stem, cerebellum, and the lower six cranial nerves are the important neural structures present in the posterior fossa.

Access this article online	
Quick Response Code:	Website: www.asianjns.org
	DOI: 10.4103/1793-5482.175627

This is an open access article distributed under the terms of the Creative Commons Attribution-NonCommercial-ShareAlike 3.0 License, which allows others to remix, tweak, and build upon the work non-commercially, as long as the author is credited and the new creations are licensed under the identical terms.

For reprints contact: reprints@medknow.com

Address for correspondence:

Dr. Showkathali Iqbal, Amala Institute of Medical Sciences, Amala Nagar, Thrissur - 680 555, Kerala, India.
E-mail: dr.iqbal.s@gmail.com

How to cite this article: Iqbal S, Robert AP, Mathew D. Computed tomographic study of posterior cranial fossa, foramen magnum, and its surgical implications in Chiari malformations. Asian J Neurosurg 2017;12:428-35.

Three dural venous sinuses viz., transverse, sigmoid, and occipital sinuses traverse the fossa. The cerebral aqueduct is a narrow passage for the drainage of cerebrospinal fluid (CSF), and any obstruction to it can lead to hydrocephalus with a significant increase in intracranial pressure.^[1]

The posterior fossa pathologies like intracranial tumors, aneurysms, arachnoid/epidermoid cysts, hemifacial spasm, and craniocervical abnormalities such as Arnold-Chiari malformations may cause compression of the brain stem and may warrant surgical decompression.^[2] Arnold-Chiari malformations are a group of congenital disorders causing a downward displacement of the contents of the PCF into the cervical spinal canal. It has been classified into two types: Chiari malformation type I (CMI) is the herniation of cerebellar tonsil, 5 mm or more into the cervical canal and type II includes the herniation of the fourth ventricle and medulla and cerebellar tonsil. Type I is common in adults and usually occur during the second or third decade of life. Type II is more common in the pediatric population and is often associated with spinal dysraphism.^[3-5] It may occur either congenital due to embryological defects in the paraxial mesoderm or acquired due to intracranial hypo/hypertension viz., CSF leak, external lumbar drainage, chronic ventriculoperitoneal shunt, edema, and space occupying lesion or, osseous anomalies of the PCF, and craniovertebral junction in the form of Paget's disease, craniostylosis, and basilar invagination. The clinical features of CMI include the symptoms of cerebellar, brain stem, and spinal cord compression due to overcrowding of PCF, and it is often associated with syringomyelia. The prevalence of CMI is estimated to be in the range of 1:1000–1:5000. Even though most cases occur sporadically, a familial transmission can also be reported either by autosomal dominant or recessive inheritance.^[6,7]

The posterior fossa volume (PFV) and the size of the FM play a significant role in determining the pathophysiology of craniovertebral junction disorders like CMI and other PCF disorders and its surgical approaches. Recent evidences attributed by computed tomography (CT) and magnetic resonance imaging (MRI) scans have suggested that the overcrowding of hindbrain due to underdevelopment of the posterior fossa is the main cause for the development of CMI. Many morphometrical studies focusing on the bony part of the PCF have supported the above hypothesis. Studies also have revealed that females are affected more than males, and this has been attributed to large PCF and hindbrain volume in males, whereas women demonstrated a higher degree of crowdedness due to smaller PCF. Posterior fossa decompression involving posterior craniectomy, laminectomy, and duroplasty have remained to be the definitive treatment of CMI.^[8,9]

Any abnormal increase in the PFV or stenosis of FM causes brain stem, cerebellum, and cranial nerve compressions,

which are manifested by cardiac, respiratory complications, lower cranial nerve dysfunctions, upper and lower extremity paresis, hyper/hypotonia, hyperreflexia, or clonus.^[10] Thus, we need a detailed anatomy of posterior fossa and FM for a proper diagnosis of PCF abnormalities, as well as in determining the proper surgical approach. So the aim of the present investigation was to evaluate the PCF volume and the surface area of FM in the adult South Indian population, in the CT scan films of patients suspected of head injury and to correlate our findings with the current literature. It can also help in a great way to sonologists and neurosurgeons for better diagnostic procedures, as well as proper planning of the treatment modalities of the posterior fossa.

Materials and Methods

This cross-sectional study was carried out in a tertiary care referral hospital in South India from January to August 2015. One hundred adult CT scans without any bony or soft tissue abnormalities from the suspected cases of head injury patients with age ranging from 18 to 70 years from Radiodiagnosis department were included in this study. The patient's consent was obtained, and the study procedure was approved by the Institutional Research Committee. The height of the PCF was measured as the perpendicular distance between the Twining's line and McRae's line [Figure 1a and b]. The anteroposterior (AP) diameter is the maximum distance from the dorsum sellae to internal occipital crest while the transverse diameter is the maximum distance between the points just below the base of petrous temporal bone in the groove for sigmoid sinus [Figure 1c and d]. The PFV was calculated by using a formula $abc/2$, where "a" is the height of the posterior fossa, "b" is the greatest AP diameter, and "c" is the greatest transverse diameter.^[11] The AP diameter of FM was measured from basion to opisthion, and the transverse diameter was measured by connecting the most distally placed lateral points perpendicular to the AP diameter [Figure 1e and f]. The surface area of FM was calculated using the formula πr^2 , where r is the average radius calculated from both AP and transverse diameters.^[12] All the above parameters were measured by two independent observers to eliminate inter/intraobserver errors. The CT scans were performed using an Optima volume CT 660 machine; brain images were obtained with thickness/space 5/5 mm (4 images/rotation); reconstruction were done with a thickness of 0.625 mm with a total of 256 images, and the measurements were taken from reconstructive images. The data obtained from the CT scans of PCF and FM were subjected to statistical analysis by using SPSS software version 16 (SPSS Inc., Chicago, IL, USA). Independent sample *t*-test and analysis of variance test were used. $P < 0.05$ was considered significant.

Appendix

The derivation of the $abc/2$ formula is as follows: The volume of an ellipsoid is $4/3\pi(a/2)(b/2)(c/2)$, where a, b, and c are the three diameters. If π is estimated to be 3, then the volume of an ellipsoid becomes $abc/2$.^[11]

Results

The height and volume of the PCF and the various dimensions of the FM were recorded in 100 CT scans of suspected head injury patients. The age of the patients were ranged from 18

to 70 years with a mean of 41.22 ± 13.937 years [Table 1]. There were 53 males and 47 females. Patients with fracture of base of the skull and with soft tissue injuries including brain parenchyma were excluded from this study. The dimensions such as height, AP, and transverse diameters and PFV were measured in the CT scans and were depicted in Table 2. The AP, transverse diameters, and the surface area of FM in the CT scans were enumerated in Table 3. There was no significant difference in the dimensions of posterior fossa and FM among the various age groups. Almost all the dimensions of PCF and FM were larger in males compared to females. These differences were statistically significant in all except AP diameter of FM [Table 4]. The mean height of PCF was $38.08 (\pm 4.718)$ mm (range 37.16–38.96 mm), and the mean PFV was $157.23 (\pm 6.700)$ mm³, (range 155.89–158.59 mm³) in the CT scans of head injury patients. The mean AP, transverse diameters, and mean surface area of FM were $33.13 (\pm 3.286)$ mm, $29.01 (\pm 3.081)$ mm, and $763.803 (\pm 138.276)$ mm², respectively. A Whisker-Boxplot

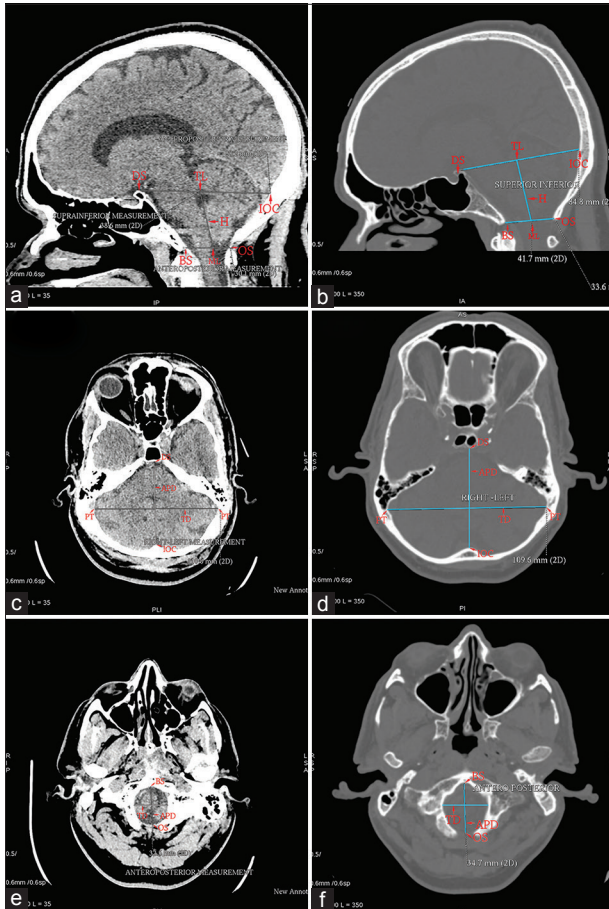

Figure 1: (a) Brain computed tomography midsagittal film demonstrating the boundaries of posterior fossa. (b) Brain computed tomography midsagittal film (bone window) demonstrating the measurement of height of the posterior fossa. DS – Dorsum sellae; IOC – Internal occipital crest; TL – Twining’s line; BS – Basion; OS – Opisthion; ML – McRae’s line; H – Height of posterior fossa. (c) Brain computed tomography axial film demonstrating anteroposterior and transverse diameters of posterior cranial fossa. DS – Dorsum sellae; IOC – Internal occipital crest; PT – Base of Petrous temporal; APD – Anteroposterior diameter; TD – Transverse diameter. (d) Brain computed tomography axial film (bone window) demonstrating the measurement of anteroposterior and transverse diameters of posterior cranial fossa. (e) Brain computed tomography axial film demonstrating anteroposterior and transverse diameters of foramen magnum. (f) Brain computed tomography axial film (bone window) demonstrating the measurement of anteroposterior and transverse diameters of foramen magnum. BS – Basion; OS – Opisthion; APD – Anteroposterior diameter; TD – Transverse diameter

Table 1: Age distribution of suspected head injury patients enrolled in this study

Age (years)	Frequency	Percentage	Mean age
18-24	13	13.0	41.22±13.937
25-34	22	22.0	
35-44	21	21.0	
45-54	24	24.0	
55-64	13	13.0	
65-70	7	7.0	
Total	100	100.0	

Table 2: Dimensions of the PCF according to various age groups in suspected head injury patients

Age group (years)	Posterior fossa height (mm)	P	PFV (mm ³)	P
18-24 (n=13)	37.20±5.822	0.808	156.83±6.900	0.816
25-34 (n=22)	38.72±4.651		158.43±7.638	
35-44 (n=21)	38.42±3.937		156.95±6.744	
45-54 (n=24)	37.16±4.724		155.89±5.547	
55-64 (n=13)	38.96±3.498		158.59±6.544	
65-70 (n=7)	38.21±7.249		157.14±8.295	

PCF – Posterior cranial fossa; PFV – Posterior fossa volume

Table 3: Dimensions of the FM according to various age groups in suspected head injury patients

Age group (years)	APD (mm)	P	Transverse diameter (mm)	P	Surface area (mm ²)	P
18-24 (n=13)	33.12±2.56	0.810	28.11±2.58	0.254	739.64±105.72	0.422
25-34 (n=22)	33.06±2.74		28.93±2.60		758.87±119.41	
35-44 (n=21)	33.03±3.80		29.42±3.54		780.27±167.33	
45-54 (n=24)	32.94±3.26		28.73±3.14		758.02±132.71	
55-64 (n=13)	34.02±3.00		30.60±3.46		825.80±145.52	
65-70 (n=7)	31.75±5.21		27.52±2.28		700.00±155.17	

FM – Foramen magnum; APD – Anteroposterior diameter

for various dimensions of PCF and FM by gender were also done [Figure 2].

Discussion

The various pathological conditions of the PCF viz., axial tumors like medulloblastoma, cerebellopontine angle tumors, aneurysms of vessels of the posterior fossa, arterio-venous malformations, cranial nerve lesions, and the craniovertebral junction abnormalities like Arnold-Chiari malformations are quite common. A fundamental knowledge of PCF and FM including its normal dimensions and extent is essential clinically for accurate radiological diagnosis and in the proper planning of various surgical interventions. Normal variations in the PCF and FM were seen in various races, religions, body habitus, gender, geographical, and genetic factors. Several studies were conducted on the normal dimensions of both PCF and FM in the various parts

of the world, but information available among South Indian population was very limited. Our study adds up to the above deficit and has a superior advantage over other studies as we have measured the dimensions of both posterior fossa and FM from the CT scans of suspected head injury patients to evolve a rational data that will have an immense help to clinicians as a whole.

Kanodia *et al.* reported that the mean posterior fossa height was 3.01 cm in the dry skull and 3.52 cm in CT scans.^[10] Shrestha *et al.* in their study using sagittal MRI films measured the height from basion to the peak of tentorium cerebelli and reported as 47.28 ± 7.0 mm in CMI patients and 54.11 ± 5.45 mm in the control groups.^[13] Aydin *et al.*^[8] in their study using MRI scans, measured the height of posterior fossa from splenium of the corpus callosum to McRae's line and this value was slightly higher than our values. The mean height of posterior fossa in the CT scans of the suspected head

Table 4: Mean dimensions of the PCF and FM in suspected head injury patients in relation to gender

Dimensions	Total (mean)	Sex (mean±SD)		P
		Male (n=53)	Female (n=47)	
Posterior fossa height (mm)	38.08±4.718	39.63±4.791	36.34±3.995	0.0001
PFV (mm ³)	157.23±6.700	159.66±6.324	154.50±6.083	0.0001
FM APD (mm)	33.13±3.286	33.67±2.96	32.52±3.54	0.081
FM transverse diameter (mm)	29.01±3.081	29.65±3.15	28.30±2.86	0.028
FM surface area (mm ²)	763.803±138.276	800.11±143.789	722.859±120.607	0.005

SD – Standard deviation; APD – Anteroposterior diameter; PCF – Posterior cranial fossa; FM – Foramen magnum; PFV – Posterior fossa volume

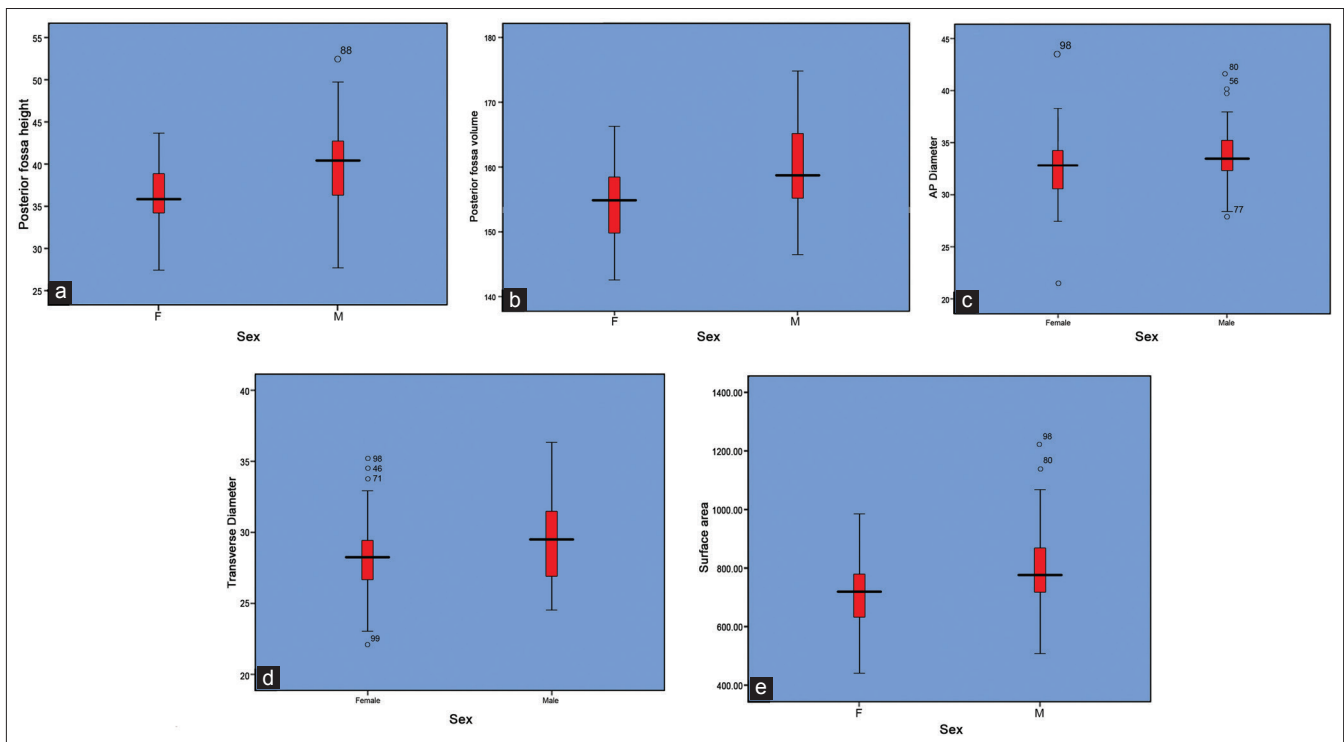


Figure 2: (a) Posterior fossa height (mm) in relation to genders. (b) Posterior fossa volume (mm³) in relation to genders. (c) Anteroposterior diameter (mm) of foramen magnum in relation to genders. (d) Transverse diameter (mm) of foramen magnum in relation to genders. (e) Surface area (mm²) of foramen magnum in relation to genders

injury patients in our present study was 38.08 (± 4.718) mm, and our measurement was more or less similar to that of Kanodia *et al.*^[10] The wide variations in the values of the posterior fossa of the other workers may be explained due to the different methodology employed by different authors.

The mean PFV was calculated by using a simple formula $abc/2$, and this formula was used to calculate the volume of intracranial hematoma and abscess.^[11] Kanodia *et al.*^[10] used both the formula $abc/2$ and a built-in-software to calculate PFV. They have reported that the PFV was 122.49 cm³ in the dry skull and 157.88 cm³ in CT scans. Bagci *et al.*^[14] using MRI scans in adult cohort CMI patients, calculated the mean PCF volume as 196 ± 8.7 mL while Nishikawa *et al.*,^[3] Noudel *et al.*,^[15] and Milhorat *et al.*^[16] recorded as 186 mL, 174 ± 25 mL, and 166 ± 8 mL respectively, using both CT and MRI-based studies. The mean PFV using CT scans in the suspected head injury group in our study was 157.23 (± 6.700) mm³ and our measurement was more or less similar to that of Kanodia *et al.*,^[10] but it was slightly lesser than the volume calculated using MRI scans.^[8,13]

The normal volume of the PCF and its height are the prime factors to determine the overcrowding of the PCF. Some patients with bony hypoplasia become symptomatic at an early age. The severity of presentations could be more with more overcrowding as in congenital anomalies like CMI. Underdeveloped PCF associated with short height could lead to downward herniation of the contents in adult and pediatric patients leading to syringomyelia and cause obstruction of the normal CSF circulation.^[3,17] Most of the previous studies suggest that the overcrowding in the posterior fossa is produced by the underdevelopment of the occipital endochondrium, possibly due to the underdevelopment of occipital somites originating from paraxial mesoderm in the intrauterine life, resulting in posterior fossa hypoplasia with CSF flow abnormalities manifested in the adult with varying degrees of tonsillar herniation.^[3,4,18] The basioccipital shortness was a cardinal feature of the shallow PCF. This may be due to a congenital disorder of the cephalic mesoderm of the parachordal plate or occur in the later infancy because of premature fusion of the spheno-occipital synchondrosis.^[19]

The hypoplasia of PCF results in herniation of normal sized hindbrain and leading to the development of CMI. Other factors contribute to the development of CMI are the shorter lengths of clivus and supraocciput and height of posterior fossa.^[3,8,13] The reduction in the angle between the tentorium and twining's line leads to a steeper tentorium, due to the upward shift of contents of the posterior fossa, causes overcrowding of PCF and finally leads to a downward shift of hindbrain, causes cerebellar tonsil herniation. The herniation of the cerebellar tonsils through FM into cervical canal also leads to the obstruction of the anatomical pathway of the CSF circulation and leads to the development of hydrocephalus.^[3]

The basilar invagination is the other important factor for the development of syringomyelia because it also causes the reduction in the PFV. It can be confirmed by radiological identification of the odontoid protrusion above McRae's line. It is the causative factor for 25–50% of CMI in adults. The surgical intervention was different in these patients with CMI with syringomyelia as it requires anterior decompression.^[20] Goel *et al.* reported that small PFV were associated with Chiari malformation in a basilar invasion while patients with only basilar invasion without Chiari malformation had a normal PFV. They recommended decompression of the FM in small PFV group patients.^[21] Nishikawa *et al.* estimated the PCF overcrowding by calculating a "volume ratio," between the volume of the PCF brain to volume of PCF cranium and suggested that in adult-type Chiari malformation an underdeveloped occipital bone possibly due to underdevelopment of occipital bone originating from the paraxial mesoderm induces overcrowding in the posterior fossa, which contains the normally developed hindbrain. Basilar invagination is associated with a more severe downward herniation of the hindbrain due to the more severely underdeveloped occipital endochondrium, which further exacerbates overcrowding of posterior fossa.^[3]

Grant *et al.* reported that the meningocele was found to associate with tonsillar herniation and a smaller posterior fossa. The antenatal surgical repair was conducted to correct both abnormalities in this case.^[22] Badie *et al.* concluded that that the ratio of PFV to supratentorial volume, i.e. posterior fossa ratio (PFR) was smaller in most patients with CMI. The smaller PCF may be the primary cause of tonsillar herniation. Patients with CMI who have smaller PFRs tend to develop symptoms earlier than those with normal values. They also observed that patients with smaller PFRs tend to respond better to suboccipital decompression.^[20] Sgouros *et al.* suggested that children with both CMI and syringomyelia had a significantly smaller PFV than children with isolated CMI alone and that they concluded that the two subgroups may represent different phenotypic expression or even a different pathogenesis.^[23] Trigylidas *et al.* observed that the mean PFV/intracranial volume ratio for all CMI patients was statistically smaller than that of the control patients.^[24] But Tubbs *et al.*^[25] who analyzed volumetric analysis in a family of CMI documented in four generations concluded that it is not necessary that patients with a CMI will have a smaller PCF. Sekula Jr *et al.*^[18] analyzed 22 patients prospectively and suggested that tonsillar descent $<3-5$ mm below the FM with congenitally hypoplastic posterior fossa, results CSF flow abnormalities, causing symptomatology consistent with CMI.

It is an accepted fact that CMI is due to the result of a paraxial mesodermal defect of the parachordal plate or premature stenosis of the spheno-occipital synchondrosis.^[19,24] Hwang *et al.* also agreed with the above theory and further proposed that premature stenosis of the spheno-occipital synchondrosis

causes premature closure of the spheno-occipital synchondrosis similar to craniosynostosis of the calvaria. The shape of the posterior fossa eventually changes into a narrow funnel shape, reflecting the slab-sided and narrow posterior fossa, such as inverted oxycephaly of coronal suture craniosynostosis.^[26]

Various surgical modalities have been employed to manage CMI decompression over the last 100 years. Some experts suggested performing only a simple suboccipital craniectomy with C1 or C1, C2 laminectomy.^[27] Others recommended an enlargement of the dura of the posterior fossa in addition to the craniectomy. The most effective treatment of CMI is to enlarge the FM and expand the dura by surgical approaches, such as suboccipital craniectomy, craniectomy with C1, C2 laminectomy, and duroplasty. Sindou *et al.* performed FM decompression with extreme lateral rim resection, followed by dural enlargement was considered to be the most effective treatment for CMI whether associated with syringomyelia or not. Bilateral resection of the tonsil has been advocated by some surgeons in order to achieve an optimal decompression of the cervico-occipital junction.^[28,29] In the cases of either occipital hypoplasia or early synostosis of spheno-occipital synchondrosis, the posterior fossa assumes the shape of a funnel, and since the sigmoid sinus forms the bilateral limitation, there seems a less change in the bilateral diameter of the posterior fossa in CMI group. But there seems to be a slight change in anteroposterior diameter of the FM in CMI group than normal patients. For the effective PCF decompression, sufficient cephalocaudal extension of the craniotomy of the PCF in patients with symptomatic CMI is important.^[29] Thus, the morphometrical assessments of both, the posterior fossa and FM, in the control group and symptomatic CMI patients will, however, aid in the selection of most effective, ideal surgical techniques most suited to CMI patients based on morphological changes in PF.

The FM and the occipital bone develops from cells of two different origins. The first one is the chondrocranium that constitutes the bones at the cranial base and is formed by endochondral ossification. The second one constitutes the parachordal cartilage around the cranial end of the notochord. Both of them fuse into a cartilaginous mass and is derived from the sclerotomal regions of the occipital somites. These cartilaginous mass grow extensively around the cranial end of the spinal cord and contribute to the base of the occipital bone and the boundaries of the FM. After birth, the growth of the cranial base continues at the spheno-occipital synchondrosis until adolescence.^[27]

The FM is the prime component in the complex network of bony, ligamentous, and muscular structures that comprise the craniovertebral junction. The size and shape of the FM are the critical parameters for the manifestation of clinical signs and symptoms in craniocervical pathology. Lang *et al.* classified

five different groups of FM based on the different shapes: (a) Two semicircles, (b) an elongated circle, (c) egg-shaped, (d) rhomboidal, and (e) rounded.^[30] On the other hand Kumar *et al.* described the shape of FM into another five types namely, oval, rounded, tetragonal, hexagonal, and irregular shapes.^[31] Tubbs *et al.* described three types of FM based on the surface area. Type I foramina seen in 20.8% of skulls with surface area <500 mm². Type II foramina (66.6%) with intermediate size with a surface area between 500 and 600 mm². Type III with large skulls with a surface area more than 600 mm² (12.5%).^[12]

The AP and transverse diameters of the FM are to be independent risk factors in patients with craniocervical anomalies.^[32] Kanodia *et al.* in their prospective study of 100 CT scans, reported that mean AP, transverse diameter, and surface area of FM were 3.31 cm, 2.76 cm, and 729.15 mm², respectively, in CT scan group.^[10] Kosif *et al.* studied the FM using midsagittal MRI images and measured the diameter of FM as 38.19 ± 3.85 mm in males and 36.09 ± 2.79 mm in females.^[33] Murshed studied the morphometry of FM in CT scans of 110 normal subjects and recorded the sagittal (AP) diameter as 37.3 ± 3.43 mm and transverse diameter 31.6 ± 2.99 mm in males and 34.6 ± 3.16 mm and 29.3 ± 2.19 mm in females, respectively.^[34] Gopalrao *et al.* in 2013 studied the FM in 100 CT scans of all age groups and recorded the AP and transverse diameters were 33.90 ± 2.61 mm and 28.05 ± 2.22 mm in males and 32.35 ± 3.16 mm and 26.88 ± 2.96 mm in females, respectively.^[35] In this study, the AP, transverse diameters, and the surface area of the FM were 33.67 (±2.96) mm, 29.65 (±3.15) mm, and 800.11 (±143.789) mm² in males and 32.52 (±3.54) mm, 28.30 (±2.86) mm, and 722.859 (±120.607) mm² in females, respectively. Our measurements were more or less coincides with that of other CT scan study groups. The majority of the authors confirmed that both AP, transverse diameters, and surface area of FM were greater in males compared to females, indicating sexual dimorphism, and it also helps to determine the sex in certain medico-legal conditions, such as in aircraft accidents, bomb explosions, and post-war sequel.^[36] The results of our study also confirm the above gender dominance. Slight variations in our results could be explained due to the difference in races, habitus, and geographical and genetic factors.

The FM transmits numerous neurovascular structures, which may suffer compressions in certain pathological conditions, such as FM achondroplasia and FM brain herniation. These patients need a carefully planned surgical intervention for decompression. A detailed knowledge of the dimensions of the FM is useful to determine the congenital malformations such as Arnold-Chiari malformations, which usually shows an increase in transverse diameter. In patients with achondroplasia, the size of FM was small with exaggerated neurological problems. The configuration of the FM has been found to be larger in Chiari malformations types I and II than with control

subjects.^[37] Furtado *et al.* found that there was no statistical difference in the area and linear dimensions of the FM in children with CMI and control groups.^[38] The symptoms of CMI develop very early in patients who have a short AP diameters of FM than others.^[39] Aydin *et al.* in their study, noted that all measurements except AP diameter of FM were reduced in patients with CMI than compared to control. Most of them have tonsillar herniation 5 mm below FM and were associated with syringomyelia.^[8] Patients with stenosis of FM, such as craniometaphyseal dysplasia, Jeune's asphyxiating thoracic dystrophy, spherophakia-brachymorphism (Marchesani's syndrome), and Beare-stevenson syndrome could develop early and severe symptoms.^[10] The anatomy of the craniocervical region may be different in CMI patients with syringomyelia who develop syringobulbia than to with other patients of CMI with or without syringomyelia.^[40] An increased frequency of cerebellar tonsillar herniation was associated with patients with an increased AP diameter of FM.^[41]

For transcondylar approach for decompression, to understand the bony anatomy of FM is of utmost importance. Muthukumar *et al.* have suggested that the occipital condyle can be safely drilled for a distance of 12 mm from the posterior margin before encountering hypoglossal canal. In over 20% of the skulls, the occipital condyle protrudes significantly into the FM. Wide and sagittally inclined occipital condyles, medially protuberant occipital condyles along with an FM index of more than 1.2 will require much more extensive bony resection than other patients.^[42] Transcondylar approach is also the commonly employed procedure to access the lesions which are ventral to the brain stem and cervicomedullary junction. The longer AP diameter of the FM permits greater contralateral surgical exposure for condylar resection.^[43]

Strengths and limitations

Large sample size is the strength of our study. Morphometrical analysis in CT scans of suspected head injury patients without bony injury were used in this study. Moreover, only a few publications listing the CT measurements of posterior fossa and FM were available in the current medical literature. This was a cross-sectional study in which all age groups ranging from 18 to 70 years were included. Notable limitations include that of the duration of the study and the pediatric age group, which is the predominant age group for anomalies of this region, has not included in this study, as it was difficult to get sufficient specimens.

Conclusion

Normal ranges of various dimensions of PCF and FM of adult South Indian population were determined using CT scans, which could serve as future reference. The various dimensions of PCF and FM were less in females compared to males and was also useful to determine various congenital malformations like Arnold-Chiari syndrome and in surgical procedures of FM

and PCF decompression. Dry skull measurements could not be relied upon because it may mislead surgeons due to shrinkage and demineralization.

Acknowledgments

Authors sincerely acknowledge the services rendered by Dr. Balakrishnan V, Professor and HOD of Radiodiagnosis, Mr. Vidhu M Joshy, Biostatistician, Dr. Ajith TA, Dr. Sugathan KR, and all the supporting staff of Amala Institute of Medical Sciences, Thrissur, Kerala, India for their immense help to make this project a reality.

Financial support and sponsorship

Nil.

Conflicts of interest

There are no conflicts of interest.

References

1. Standring S, editor. Gray's Anatomy: The Anatomical Basis of Clinical Practice. 40th ed. Philadelphia: Elsevier Churchill Livingstone; 2008. p. 424.
2. Duffy C. Anaesthesia for posterior fossa surgery. In: Matta BF, Menon DK, Turner JM, editors. Textbook of Neuroanaesthesia and Critical Care. London: Greenwich Medical Media Ltd.; 2000. p. 269-80.
3. Nishikawa M, Sakamoto H, Hakuba A, Nakanishi N, Inoue Y. Pathogenesis of Chiari malformation: A morphometric study of the posterior cranial fossa. *J Neurosurg* 1997;86:40-7.
4. Milhorat TH, Chou MW, Trinidad EM, Kula RW, Mandell M, Wolpert C, *et al.* Chiari I malformation redefined: Clinical and radiographic findings for 364 symptomatic patients. *Neurosurgery* 1999;44:1005-17.
5. McGirt MJ, Atiba A, Attenello FJ, Wasserman BA, Datto G, Gathinji M, *et al.* Correlation of hindbrain CSF flow and outcome after surgical decompression for Chiari I malformation. *Childs Nerv Syst* 2008;24:833-40.
6. Milhorat TH, Bolognese PA, Nishikawa M, Francomano CA, McDonnell NB, Roonprapunt C, *et al.* Association of Chiari malformation type I and tethered cord syndrome: Preliminary results of sectioning filum terminale. *Surg Neurol* 2009;72:20-35.
7. D'Apolito G, Calandrelli R, Gaudino S, Tumino M, Pedone L, Colosimo C. Posterior Fossa Morphometry and Volumetric Analysis in Three Different Groups of Pediatric Patients: Congenital Chiari Type I Malformation, Posterior Craniosynostosis and Costello Syndrome. *European Society of Radiology, Poster No: C-0685, ECR; 2014.* p. 1-19. Available from: <http://www.myesr.org>. [Last accessed on 2015 Aug 30].
8. Aydin S, Hanimoglu H, Tanriverdi T, Yentur E, Kaynar MY. Chiari type I malformations in adults: A morphometric analysis of the posterior cranial fossa. *Surg Neurol* 2005;64:237-41.
9. Furtado SV, Reddy K, Hegde AS. Posterior fossa morphometry in symptomatic pediatric and adult Chiari I malformation. *J Clin Neurosci* 2009;16:1449-54.
10. Kanodia G, Parihar V, Yadav YR, Bhatlele PR, Sharma D. Morphometric analysis of posterior fossa and foramen magnum. *J Neurosci Rural Pract* 2012;3:261-6.
11. Kothari RU, Brott T, Broderick JP, Barsan WG, Sauerbeck LR, Zuccarello M, *et al.* The ABCs of measuring intracerebral hemorrhage volumes. *Stroke* 1996;27:1304-5.
12. Tubbs RS, Griessenauer CJ, Loukas M, Shoja MM, Cohen-Gadol AA. Morphometric analysis of the foramen magnum: An anatomic study. *Neurosurgery* 2010;66:385-8.
13. Shrestha R, Wang M, Xiao Y, Qi L, Pant B. Morphometric analysis of the posterior cranial fossa in Chiari type I malformation in adults. *Int J*

- Health Sci Res 2015;5:32-8.
14. Bagci AM, Lee SH, Nagornaya N, Green BA, Alperin N. Automated posterior cranial fossa volumetry by MRI: Applications to Chiari malformation type I. *AJNR Am J Neuroradiol* 2013;34:1758-63.
 15. Noudel R, Gomis P, Sotoares G, Bazin A, Pierot L, Pruvo JP, *et al.* Posterior fossa volume increase after surgery for Chiari malformation Type I: A quantitative assessment using magnetic resonance imaging and correlations with the treatment response. *J Neurosurg* 2011;115:647-58.
 16. Milhorat TH, Nishikawa M, Kula RW, Dlugacz YD. Mechanisms of cerebellar tonsil herniation in patients with Chiari malformations as guide to clinical management. *Acta Neurochir (Wien)* 2010;152:1117-27.
 17. Tubbs RS, Elton S, Grabb P, Dockery SE, Bartolucci AA, Oakes WJ. Analysis of the posterior fossa in children with the Chiari 0 malformation. *Neurosurgery* 2001;48:1050-4.
 18. Sekula RF Jr, Jannetta PJ, Casey KF, Marchan EM, Sekula LK, McCrady CS. Dimensions of the posterior fossa in patients symptomatic for Chiari I malformation but without cerebellar tonsillar descent. *Cerebrospinal Fluid Res* 2005;2:11.
 19. Noudel R, Jovenin N, Eap C, Scherpereel B, Pierot L, Rousseaux P. Incidence of basioccipital hypoplasia in Chiari malformation type I: Comparative morphometric study of the posterior cranial fossa. *Clinical article. J Neurosurg* 2009;111:1046-52.
 20. Badie B, Mendoza D, Batzdorf U. Posterior fossa volume and response to suboccipital decompression in patients with Chiari I malformation. *Neurosurgery* 1995;37:214-8.
 21. Goel A, Bhatjiwale M, Desai K. Basilar invagination: A study based on 190 surgically treated patients. *J Neurosurg* 1998;88:962-8.
 22. Grant RA, Heuer GG, Carrión GM, Adzick NS, Schwartz ES, Stein SC, *et al.* Morphometric analysis of posterior fossa after in utero myelomeningocele repair. *J Neurosurg Pediatr* 2011;7:362-8.
 23. Sgouros S, Kountouri M, Natarajan K. Posterior fossa volume in children with Chiari malformation Type I. *J Neurosurg* 2006;105 2 Suppl: 101-6.
 24. Trigylidas T, Baronia B, Vassilyadi M, Ventureyra EC. Posterior fossa dimension and volume estimates in pediatric patients with Chiari I malformations. *Childs Nerv Syst* 2008;24:329-36.
 25. Tubbs RS, Hill M, Loukas M, Shoja MM, Oakes WJ. Volumetric analysis of the posterior cranial fossa in a family with four generations of the Chiari malformation Type I. *J Neurosurg Pediatr* 2008;1:21-4.
 26. Hwang HS, Moon JG, Kim CH, Oh SM, Song JH, Jeong JH. The comparative morphometric study of the posterior cranial fossa: What is effective approaches to the treatment of Chiari malformation type 1? *J Korean Neurosurg Soc* 2013;54:405-10.
 27. Dagtekin A, Avci E, Kara E, Uzmanse D, Dagtekin O, Koseoglu A, *et al.* Posterior cranial fossa morphometry in symptomatic adult Chiari I malformation patients: Comparative clinical and anatomical study. *Clin Neurol Neurosurg* 2011;113:399-403.
 28. Sindou M, Chávez-Machuca J, Hashish H. Craniocervical decompression for Chiari type I-malformation, adding extreme lateral foramen magnum opening and expansile duroplasty with arachnoid preservation. Technique and long-term functional results in 44 consecutive adult cases-comparison with literature data. *Acta Neurochir (Wien)* 2002;144:1005-19.
 29. Fischer EG. Posterior fossa decompression for Chiari I deformity, including resection of the cerebellar tonsils. *Childs Nerv Syst* 1995;11:625-9.
 30. Lang J. *Clinical Anatomy of the Posterior Cranial Fossa and its Foramina.* Stuttgart, Germany: Thieme; 1991.
 31. Kumar A, Dave M, Anwar S. Morphometric evaluation of foramen magnum in dry human skulls. *Int J Anat Res* 2015;3:1015-23.
 32. Bagley CA, Pindrik JA, Bookland MJ, Camara-Quintana JQ, Carson BS. Cervicomedullary decompression for foramen magnum stenosis in achondroplasia. *J Neurosurg* 2006;104 3 Suppl: 166-72.
 33. Kosif R, Huvaj S, Abanonu HE. Morphometric analysis of occipitocervical region and cervical height in female and male. *Gulhane Med J* 2007;49:173-7.
 34. Murshed KA, Clecclbasi AE, Tuncer I. Morphometric evaluation of the foramen magnum and variations in its shape: A study on computed tomographic images of normal adults. *Turk J Med Sci* 2003;33:301-6.
 35. Gopalrao SR, Solanke P, Ugale M, Balsurkar S. Computed tomographic scan study of morphometry of foramen magnum. *Int J Curr Res Rev* 2013;5:41-8.
 36. Günay Y, Altinkök M. The value of the size of foramen magnum in sex determination. *J Clin Forensic Med* 2000;7:147-9.
 37. Gardner WJ, Goodall RJ. The surgical treatment of Arnold-Chiari malformation in adults; an explanation of its mechanism and importance of encephalography in diagnosis. *J Neurosurg* 1950;7:199-206.
 38. Furtado SV, Thakre DJ, Venkatesh PK, Reddy K, Hegde AS. Morphometric analysis of foramen magnum dimensions and intracranial volume in pediatric Chiari I malformation. *Acta Neurochir (Wien)* 2010;152:221-7.
 39. Menezes AH. Primary craniovertebral anomalies and the hindbrain herniation syndrome (Chiari I): Data base analysis. *Pediatr Neurosurg* 1995;23:260-9.
 40. Tubbs RS, Bailey M, Barrow WC, Loukas M, Shoja MM, Oakes WJ. Morphometric analysis of the craniocervical juncture in children with Chiari I malformation and concomitant syringobulbia. *Childs Nerv Syst* 2009;25:689-92.
 41. Dufton JA, Habeeb SY, Heran MK, Mikulis DJ, Islam O. Posterior fossa measurements in patients with and without Chiari I malformation. *Can J Neurol Sci* 2011;38:452-5.
 42. Muthukumar N, Swaminathan R, Venkatesh G, Bhanumathy SP. A morphometric analysis of the foramen magnum region as it relates to the transcondylar approach. *Acta Neurochir (Wien)* 2005;147:889-95.
 43. Wanebo JE, Chicoine MR. Quantitative analysis of the transcondylar approach to the foramen magnum. *Neurosurgery* 2001;49:934-41.