

LETTER TO EDITOR

Rhabdoid meningioma in the petroclival region: An atypical meningioma in an atypical site

Dear Editor,

Rhabdoid meningioma is an uncommon variant of meningioma and was classified separately for the first time in the 2000 World Health Organization's classification of tumors of the nervous system. Because it often shows malignant histological features and follows an aggressive clinical course, it has been classified as a grade III neoplasm.^[1] On histological examination, the majority of the tumor mass was composed of necrotic tissue with focal clusters of neoplastic cells, often localized around blood vessels. Most tumor cells exhibited typical rhabdoid morphology with large, vesicular, often eccentrically located nuclei with distinct nucleoli and abundant cytoplasm containing eosinophilic hyaline inclusions.^[2] Here, we report a case, who presented with multiple lower cranial nerves palsy and quadriplegia. Magnetic resonance imaging (MRI) of the brain revealed large right-sided petroclival meningioma, which turned out to be rhabdoid meningioma on histopathology. To our knowledge, this is the first reported case of rhabdoid meningioma in the petroclival region. As atypical meningioma poses problem during operation, preoperative diagnosis and planning of surgery will help better management.

A 60-year-old man presented with headache, difficulty in walking, right-sided hearing loss and difficulty in swallowing for 2 months. He started to fall on the right side. He had bilateral long tracts signs, right-sided hearing loss, right-sided cerebellar signs. His uvula was deviated toward left. He was quadriplegic with Medical Research Council grade 4⁺/5 muscle power in both upper and lower limbs. Contrast MRI of the brain showed right-sided huge petroclival region [Figure 1] tumor extending up to C1 level [Figure 2]. The tumor shows inhomogeneous contrast-enhancement. There was also a big extension of tumor compressing the fourth ventricle. Through retrosigmoid suboccipital craniotomy with exposure of foramen magnum and removal of right half of posterior arch of atlas tumor was removed near totally. Consistency of the tumor was firm. Histopathology reported it as rhabdoid meningioma [Figure 3]. Per operatively, there was encasement of lower cranial nerves with the tumor and nerves were carefully freed from the tumor. Some part of the tumor was extended in the jugular foramen and attached to the jugular foramen nerves. Postoperative computed tomography scan [Figure 4]

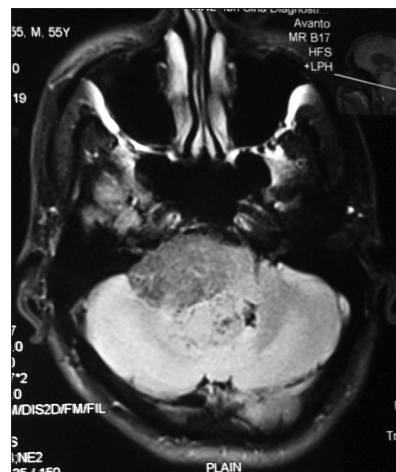

Figure 1: Plain magnetic resonance imaging axial section shows isodense space-occupying lesion at right petroclival region with compression of the 4th ventricle

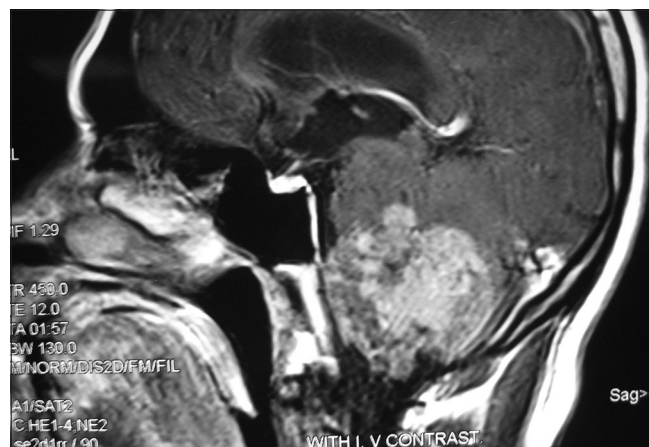


Figure 2: Contrast-enhanced sagittal magnetic resonance imaging shows inhomogeneously enhanced petroclival region space-occupying lesion extending up to the level of C1 vertebra

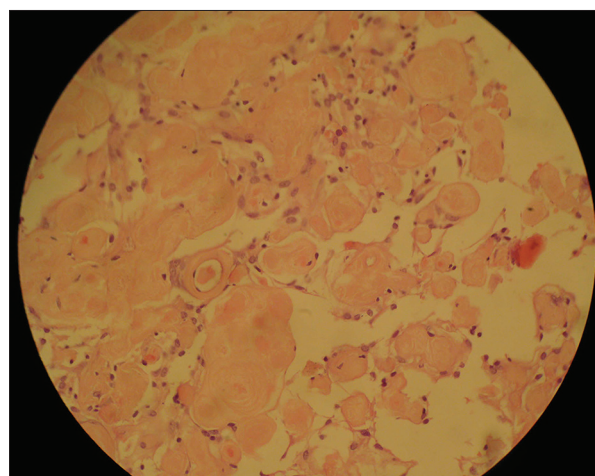


Figure 3: Histopathological picture of the tumor showing rhabdoid morphology

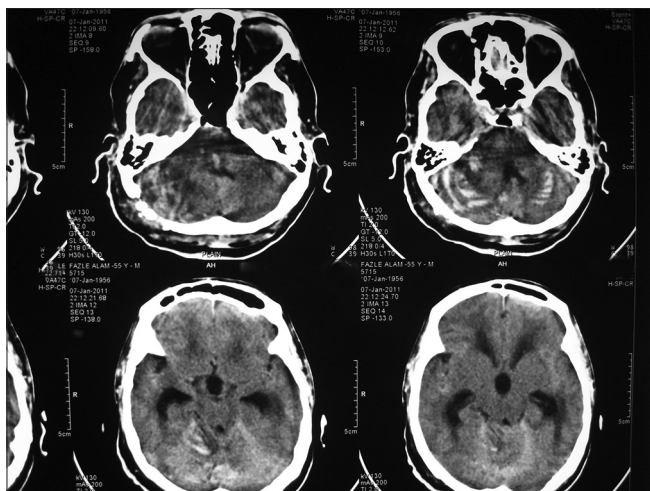


Figure 4: Postoperative computed tomography scan showing near total removal of tumor with little amount of hemorrhage

done on 2nd postoperative day revealed near-total removal of the tumor with little amount of hematoma.

It is a pathologic diagnosis with the presence of loosely cohesive cells with eccentric nuclei and hyaline, paranuclear inclusions being characteristic. Electron microscopy revealed that characteristic interdigitating cellular processes and intercellular junctions are poorly developed or absent.^[3]

Rhabdoid meningioma usually occurs in adult but can occur in children. It usually recurs shortly even after radical surgery in an aggressive manner as the rhabdoid phenotype represents a marker of malignant transformation in meningiomas. The mean age of patients was 50.4 years at their first operation. The mean time to first recurrence was 36.1 months. The recurrence-free survival rates at 1 and 5 years were 62% and 23%, respectively.^[1] The cerebral convexities (56%) and

the parasagittal region (25%) were common sites in one study, where none occurred in the posterior fossa.^[4] Though there are few reported cases of rhabdoid meningioma in the posterior fossa,^[5] no case is reported in the petroclival region till now.

K. A. Kawsar, M. R. Haque, F. H. Chowdhury

Department of Neurosurgery, Dhaka Medical College Hospital, Dhaka, Bangladesh

Address for correspondence:

Dr. Khandkar Ali Kawsar,
57, Waldrons Moor, Kings Heath, Birmingham, B14 6RT,
United Kingdom.
E-mail: drkawsar@yahoo.com

References

1. Wu YT, Lin JW, Wang HC, Lee TC, Ho JT, Lin YJ. Clinicopathologic analysis of rhabdoid meningioma. *J Clin Neurosci* 2010;17:1271-5.
2. Matyja E, Grajkowska W, Nauman P, Bonicki W, Bojarski P, Marchel A. Necrotic rhabdoid meningiomas with aggressive clinical behavior. *Clin Neuropathol* 2010;29:307-16.
3. Al-Habib A, Lach B, Khani AI. Intracerebral rhabdoid and papillary meningioma with leptomeningeal spread and rapid clinical progression. *Clin Neuropathol* 2005;24:1-7.
4. Kim EY, Weon YC, Kim ST, Kim HJ, Byun HS, Lee JI, *et al*. Rhabdoid meningioma: Clinical features and MR imaging findings in 15 patients. *AJNR Am J Neuroradiol* 2007;28:1462-5.
5. Jansen JC, Turner J, Sheehy J, Fagan PA. Recurrent rhabdoid meningioma: Case report. *Skull Base* 2003;13:51-54.

Access this article online	
Quick Response Code:	Website: www.asianjns.org
	DOI: 10.4103/1793-5482.162720