

Outcome following surgical resection of craniopharyngiomas: A case series

K. C. Bidur, Devkota Upendra Prasad

Department of Neurosurgery, National Institute of Neurological and Allied sciences, Bansbari, Kathmandu, Nepal

ABSTRACT

Introduction: Debate continues as to the optimum treatment for craniopharyngioma; radical surgical resection or partial resection followed by radiotherapy. Radical surgical resection may be complicated by intraoperative injury to surrounding structures and stormy postoperative hormonal problem. This study aims to examine the result of safe maximal surgical resection.

Materials and Methods: Retrospective study of all histopathologically proven craniopharyngiomas who had undergone surgical resection over an almost 8 year period was included. Data were collected reviewing demography, clinical presentation, hormonal dysfunction, extent of resection and visual deterioration. Outcome was measured in terms of Glasgow outcome scale and recurrence.

Results: Of 25 patients, 68% were male, and 32% were female. Age of patients ranged from 7 to 58 years with a mean of 30.12 ± 16.42 years. Patients presented with visual deterioration were 76% and with a headache were 68%. Mean duration of symptoms was 10.64 ± 14.28 months. Gross total resection was done in 21 (84%), while subtotal resection in 4 (16%) who also received subsequent adjuvant radiotherapy. During the postoperative period, diabetes insipidus developed in 84% patients, but none had it permanently. Favorable outcome was found in 88% patients. However, there were 4% operative mortality with overall mortality of 8% and tumor recurrence in 8% patients.

Conclusion: Gross total excision if judiciously decided intraoperatively has a favorable outcome with acceptable morbidity.

Key words: Craniopharyngioma, extent of resection, outcome

Introduction

Craniopharyngioma is a histologically benign tumor arising in the sellar and suprasellar region along the path of the craniopharyngeal duct. It accounts for 2-5% of all primary intracranial neoplasms^[1] and 5.6-13% of intracranial tumors in children.^[2] Despite its benign appearance, it can be associated with an unfavorable prognosis, due to the proximity to and relationships with vital structures.

Craniopharyngioma still represent a task in management. Controversy exists concerning the treatment of choice for these

tumors. Radical surgery, subtotal resection combined with radiotherapy, or primary irradiation are the frequent treatment modalities. Although an increasing numbers of reports have appeared stressing the role of primary radiation for these tumors, since it is a benign tumor, its total surgical removal is the treatment of choice to achieve cure and prevent recurrence. Postoperative complications are sometimes higher, however, when a complete tumor resection is attempted. In recent years, many improvements in the treatment of these lesions have been made which had tremendously improved the operative result and postoperative outcome. These improvements include hormone replacement therapy, the surgeon's ability to choose ideal surgical approaches on the basis of magnetic resonance imaging (MRI) studies, and microsurgical mastery of the anatomy. In the past decade, the newly defined goal of total tumor excision has been accomplished.^[3-5]

Radical resection is usually considered the therapy of choice at any age for primary treatment of craniopharyngioma. This treatment is associated with the best outcome in terms of survival and recurrence-free survival.^[6] Nevertheless, the location and the frequent involvement of critical neurovascular structures, tumor size, calcifications, and the patient age at presentation may limit the extent of resection.^[7,8]

Access this article online	
Quick Response Code:	Website: www.asianjns.org
	DOI: 10.4103/1793-5482.150228

Address for correspondence:

Dr. K. C. Bidur, Department of Neurosurgery, National Institute of Neurological and Allied Sciences, Bansbari, P. O. Box. No. 3711, Kathmandu, Nepal.
E-mail: kcbidur@gmail.com

Because the majority of all craniopharyngiomas involve the hypothalamus, which is one of the most important structures in the brain, higher mortality and morbidity rates have been reported following the attempt of radical surgery.^[9,5] Several authors have reported a high recurrence rate despite apparently complete tumor removal. These observations provided a strong argument for the therapeutic concept of limited surgery plus radiotherapy.^[9,10]

To further elucidate the role of safe maximal surgical resection, this study aims to study the immediate postoperative morbidity and their management and to assess the postoperative outcome.

Materials and Methods

All patients who underwent surgical excision of craniopharyngioma which were proven histopathologically from August 2006 to February 2014 were included in the study. All the operations were performed by the senior author (U.P.D.) via transcranial pterional route. Patients with sellar and suprasellar cyst though neuroradiologically suspicious of craniopharyngioma who has undergone reservoir placement only were excluded from the study. Total of 25 patients were included in this study.

Data were collected reviewing the patient's demography, clinical presentation, hormonal profile, extent of resection and postoperative complications by retrieving the files from medical record section. Outcome was measured in terms of Glasgow outcome score (GOS), visual disturbances, hormonal imbalances as well as recurrence. GOS was considered favorable when the score was 4, 5 and considered unfavorable when score was 1-3.

Patients were followed regularly after discharge in an outpatient department as well as via telephone whenever required. All the data were entered into the predesigned proforma. Data were checked for completion and analysis of data done using IBM SPSS Statistics for Windows, Version 20.0. Armonk, NY: IBM Corporation. Categorical data were expressed as proportions, and continuous variables were expressed as means \pm standard deviation.

Results

Total of 25 patients were enrolled into the study over seven and half years duration with the following results as shown in Table 1. Among them, 17 patients (68%) were male, and 8 patients (32%) were female. Age of patients ranged from 7 to 58 years, with a mean of 30.12 ± 16.42 years. All patients presented with either visual problem or with a headache, or both. 19 Patients (76%) presented with visual problems, 17 (68%) with headache and 11 (44%) with both symptoms. Duration of symptoms ranged from 1-month to 60 months, with a mean of 10.64 ± 14.28 months. Preoperative hormonal imbalance was found in 10 patients (40%).

Table 1: Result for different variables

Variables	Total (n=25) (%)
Age in years	
<18	6 (24)
>18	19 (76)
Sex distribution	
Males	17 (68)
Female	8 (32)
Presenting symptoms	
Visual problem	19 (76)
Headache	17 (68)
Hormonal dysfunction	10 (40)
Extent of resection	
Grosstotal	21 (84)
Subtotal	4 (16)
Postoperative radiotherapy	
Grosstotal	0 (0)
Subtotal	4 (16)
Postoperative DI	
Temporary	21 (84)
Permanent	0 (0)
Histopathology	
Adamantinomatous	23 (92)
Papillary	1 (4)
Hybrid	1 (4)

DI – Diabetes insipidus

Gross total resection (GTR) was achieved in 21 patients (84%) while the remaining 4 patients (16%) had subtotal resection. Extent of resection is based on both, surgeon's intraoperative impression and postoperative contrast enhanced MRI scan as shown in Figures 1 and 2. The patients who were resorted to subtotal resection also received postoperative radiotherapy. Reason for subtotal resection was tumor adherent to neurovascular structure and hard, calcified tumor. Duration of hospital stay lasting from a minimum of 8 days to a maximum of 52 days with a mean of 18.40 ± 8.12 days.

During the postoperative period, diabetes insipidus (DI) developed in 21 patients (84%). DI usually manifested during first 12 hours after surgery and improved over the weeks, with none of the patients becoming dependent on vasopressin for a long time. No patients had worsening of visual symptoms postoperatively.

Histopathology reports revealed adamantinomatous variety in 22 patients (88%), papillary variety in 2 patients (8%) and hybrid variety containing both adamantinomatous as well as papillary variety in 1 patient (4%).

Follow-up period was the maximum of almost 8 years and minimum of 1-month duration with a median period of 3.6 years. Outcome of all patients evaluated with GOS on the follow-up, favorable outcome was found in 22 patients (88%) as opposed to unfavorable in 3 patients (12%). There were 2 mortality (8%) in our series, one died due to pontine

myelinolysis resulting from severe hyponatremia in the postoperative period and another one died at home 3 month postsurgery of uncertain cause. So far 2 patients (8%) had recurrence of the tumor, one with subtotal resection and another with recurrent tumor who was operated outside previously had undergone GTR at our center as shown in Table 2.

Discussion

Craniopharyngioma is a histologically benign tumor. Nevertheless, its infiltrative behavior affecting the pituitary axis, the visual pathways, and other relevant vascular and nervous structures may hamper its definitive treatment and often implies unfavorable and long-term sequelae after surgical removal. Thus, optimal therapeutic management of craniopharyngioma continues to be debated; radical surgical resection or partial resection followed by radiotherapy. Radical surgical resection may be complicated by intraoperative injury to surrounding structures and stormy postoperative hormonal problem.

This study included 25 patients of histopathologically proven craniopharyngioma over an almost 8 years duration. We had

observed wide range of ages from 7 to 58 years, with a mean of 30.12 ± 16.42 years. The mean age of the patients included in a study by Mortini *et al.*^[11] was 33.3 ± 1.8 years ranged from 6 to 78 years. Baskin and Wilson^[12] showed mean age of 27 years ranged from 3 to 65 years. There were 68% male and 32% female in our study. Study by Yasargil *et al.*^[5] found 53.5% male and 46.5% female. Gardner *et al.*^[13] reported 62.5% male and 37.5% female. Slight male preponderance in our series could be because of illiteracy, poverty and male dominant society.

The most common presenting symptoms were visual problem followed by headache, or both found in 76%, 68% and 44% respectively in this study. Study done by Baskin and Wilson^[12] showed most common presenting symptoms were visual dysfunction and headache found in 71% and 50% cases respectively. Hoffman *et al.*^[14] revealed most common presenting symptoms were headache (68%) and visual dysfunction (58%). Visual problem were more common in our study could be because our hospital is a referral center and as our country is an underdeveloped patients usually present late. In this study duration of symptoms ranged from 1-month to 60 months, with a mean of 10.64 ± 14.28 months. Hoffman *et al.*^[14] reported symptoms duration ranged from 2 weeks to 4 years with a mean of 37.8 weeks. Preoperative hormonal imbalance was found in 10 patients (40%) in our study. Gardner *et al.*^[13] observed preoperative hormonal dysfunction in 5 patients (31.25%).

In this study, GTR was achieved in 21 patients (84%) while the remaining 4 patients (16%) had subtotal resection. The patients who were resorted to subtotal resection also received postoperative subsequent adjuvant radiotherapy. Reason for subtotal resection was tumor adherent to neurovascular structure and hard, calcified tumor. Comparable study was done by Yasargil *et al.*^[5] achieved 90% of the tumor removed completely. Hoffman *et al.*^[14] reported 45 patients (90%)

Table 2: Outcome following surgical resection

Variables	Total (n=25) (%)
Glasgow outcome scale	
Favorable	22 (88)
Unfavorable	3 (12)
Mortality	
Operative	1 (4)
Overall	2 (8)
Recurrence	
Gross total	1 (4)
Subtotal	1 (4)
Overall	2 (8)

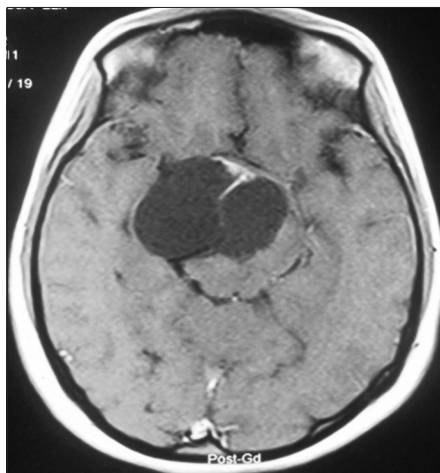


Figure 1: Preoperative contrast magnetic resonance imaging scan showing craniopharyngioma

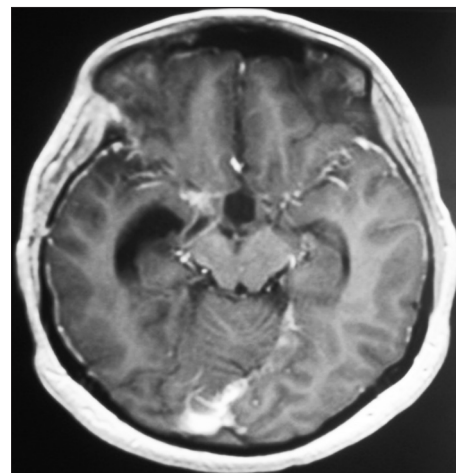


Figure 2: Postoperative contrast magnetic resonance imaging scan of the same patient showing complete removal

who underwent what was considered by the surgeon to be total excision of their tumor and 5 (10%) had subtotal excision. Mortini *et al.*^[11] used postoperative MRI to show radical resection of the tumor in 78 (71.6%) of the remaining 109 patients.

During the postoperative period, DI developed in 21 patients (84%) in this study. DI usually manifested during first 12 hours after surgery and improved over the weeks, with none of the patients becoming dependent on vasopressin for a long time. In this study, we had observed that the patient not only limited to have DI, but their symptoms may fluctuate between DI, cerebral salt wasting or hyponatremia. Hoffman *et al.*^[14] described endocrine status for 46 children of whom 43 (93.5%) were receiving DDAVP (1-Deamino-8-D-Arginine Vasopressin). Mortini *et al.*^[11] in his study of 69 patients who had normal urinary concentrating capacity before surgery of whom 21 (30.4%) retained a normal function, whereas the remaining 48 (69.6%) experienced postoperative onset of diabetes insipidus. Of the 40 patients with preoperative diabetes insipidus, 3 (7.5%) regained a normal urinary of concentrating capacity. Overall 85 (78%) of 109 patients had DI after surgery. Yasargil *et al.*^[5] reported postoperative DI in 58.2% with permanent DI in 78.7% patients. In this study, no patients had worsening of visual symptoms postoperatively. Gardner *et al.*^[13] also mentioned no patient experienced visual worsening postoperatively.

Histopathology reports revealed adamantinomatous variety in 22 patients (88%), papillary variety in two patients (8%) and hybrid variety containing both adamantinomatous as well as papillary variety in one patient (4%) in this study. Study done by Mortini *et al.*^[11] revealed, based on the morphological appearance, 104 tumors (92.9%) were classified as the adamantinomatous subtype and 8 tumors (7.1%) as the papillary subtype.

In this study, a favorable outcome was found in 22 patients (88%) as opposed to unfavorable in 3 patients (12%). There were 2 mortality (8%) in our series, one died due to pontine myelinolysis resulting from severe hyponatremia in the postoperative period and another patient died at home 3 month postsurgery. Yasargil *et al.*^[5] published in his work that the tumor was totally removed in all 112 patients with primary operation with 76.8% good results, 13.4% morbidity and 9.8% overall mortality, but if both primary and secondary operation was considered then it was possible to achieve an apparently complete removal of the tumor in 90% of cases with 67.4% good results, 16% morbidity and 16.7% overall mortality. Fahlbusch *et al.*^[8] reported till last follow-up, 117 (79%) of 148 patients who underwent primary surgery were independent and without impairment. The operative mortality rate in transcranial surgery was 1.1% with delayed mortality of 8.5% till last follow-up in primary cases and 10.5% in cases of tumor recurrence.

So far 2 patient (8%) had recurrence of the tumor in this series. Baskin and Wilson^[12] found 7 recurrences (9.4%) out of 74 cases. Yasargil *et al.*^[5] in his series of 144 patients who underwent microsurgical resection of craniopharyngioma reported recurrence rate of 7%.

Controversy exists concerning the treatment; GTR or subtotal resection combined with radiotherapy. Although an increasing numbers of reports have appeared stressing the role of primary radiation for these tumors, since it is a benign tumor, its total surgical removal is the treatment of choice to achieve cure and prevent recurrence. Postoperative complications are sometimes higher, however, when a complete tumor resection is attempted. This treatment is associated with the best outcome in terms of survival and recurrence-free survival. GTR also carries significant morbidity in terms of visual, hypothalamic, and endocrinological disturbances, thus potentially deteriorating the quality of life of patients. Because the majority of all craniopharyngiomas involve the hypothalamus, higher mortality and morbidity rates have been reported following the attempt of radical surgery.^[9,5] Several authors have reported a high recurrence rate despite apparently complete tumor removal. These observations provided a strong argument for the therapeutic concept of limited surgery plus radiotherapy.^[9,10] However, the results derived from earlier surgical series are of limited use in developing guidelines for current management of craniopharyngiomas. Series that include patients treated in the macrosurgical era are not comparable to the standard of today. Investigators in some of the more recent surgical series have reported low morbidity and mortality rates when performing transcranial microsurgical removal of craniopharyngiomas^[3,4] even when an attempt is made to remove the tumors totally. Previously, the claim of total removal was based on the surgeon's intraoperative impression, which alone is no longer sufficient.^[4,15,16,17] Today, postoperative imaging is required to define complete removal. The advent of postoperative imaging might explain why the recurrence rates in more recent surgical series appear more favorable than previously reported.^[16,3,4,5] Hoffman *et al.*^[14] reported 90% GTR with 45 patients who underwent what was considered to be total excision, there have been 13 recurrences, serious morbidity occurred in three patients who suffered injury to their internal carotid artery. Hemorrhage occurred in two patients, leading to a hemiparesis in one and a hemiparesis and dysphasia in the other. Spasm occurred in one patient, causing a hemiparesis. Endocrine deficiency was present in all patients after surgery. Vision was normal in 20 of 46 children. The other 26 had some degree of impairment. In some, the deficits were severe, but none was blind. Regarding the quality of life, 28 patients belonged to the normal or nearly normal group, 12 were mildly handicapped, and four were severely handicapped.^[14] In this study, 21 patients had GTR, and 4 had subtotal resection. Overall 21 patients developed DI of which 2 were from subtotal resection group. Out of 2 recurrences,

one was from gross total and other from subtotal resection. Regarding the quality of life, two patients were dead and one patient was dependent, all were from GTR group, rest of the 22 patients was independent.

Conclusion

of 25 patients, who had undergone surgical resection of craniopharyngioma, we have found favorable outcome in 88% patients with 4% operative mortality, no patient with permanent DI and tumor recurrence of 8% in our center. Hence, we may conclude that GTR if judiciously decided intraoperatively gives favorable outcome with acceptable morbidity.

References

1. Samii M, Tatagiba M. Craniopharyngioma. In: Kaye AH, Laws ER Jr, editors. *Brain Tumors: An Encyclopedic Approach*. New York: Churchill Livingstone; 1995. p. 873-94.
2. Rickert CH, Paulus W. Epidemiology of central nervous system tumors in childhood and adolescence based on the new WHO classification. *Childs Nerv Syst* 2001;17:503-11.
3. Samii M, Bini W. Surgical treatment of craniopharyngiomas. *Zentralbl Neurochir* 1991;52:17-23.
4. Symon L, Pell MF, Habib AH. Radical excision of craniopharyngioma by the temporal route: A review of 50 patients. *Br J Neurosurg* 1991;5:539-49.
5. Yasargil MG, Curcic M, Kis M, Siegenthaler G, Teddy PJ, Roth P. Total removal of craniopharyngiomas. Approaches and long-term results in 144 patients. *J Neurosurg* 1990;73:3-11.
6. Karavitaki N, Cudlip S, Adams CB, Wass JA. Craniopharyngiomas. *Endocr Rev* 2006;27:371-97.
7. Duff J, Meyer FB, Ilstrup DM, Laws ER Jr, Schleck CD, Scheithauer BW. Long-term outcomes for surgically resected craniopharyngiomas. *Neurosurgery* 2000;46:291-302.
8. Fahlbusch R, Honegger J, Paulus W, Huk W, Buchfelder M. Surgical treatment of craniopharyngiomas: Experience with 168 patients. *J Neurosurg* 1999;90:237-50.
9. Fischer EG, Welch K, Shillito J Jr, Winston KR, Tarbell NJ. Craniopharyngiomas in children. Long-term effects of conservative surgical procedures combined with radiation therapy. *J Neurosurg* 1990;73:534-40.
10. Raimondi AJ. Craniopharyngioma: Complications and treatment failures weaken case for aggressive surgery. *Crit Rev Neurosurg* 1993;3:7-24.
11. Mortini P, Losa M, Pozzobon G, Barzaghi R, Riva M, Acerno S, *et al*. Neurosurgical treatment of craniopharyngioma in adults and children: Early and long-term results in a large case series. *J Neurosurg* 2011;114:1350-9.
12. Baskin DS, Wilson CB. Surgical management of craniopharyngiomas. A review of 74 cases. *J Neurosurg* 1986;65:22-7.
13. Gardner PA, Kassam AB, Snyderman CH, Carrau RL, Mintz AH, Grahovac S, *et al*. Outcomes following endoscopic, expanded endonasal resection of suprasellar craniopharyngiomas: A case series. *J Neurosurg* 2008;109:6-16.
14. Hoffman HJ, De Silva M, Humphreys RP, Drake JM, Smith ML, Blaser SI. Aggressive surgical management of craniopharyngiomas in children. *J Neurosurg* 1992;76:47-52.
15. De Vile CJ, Grant DB, Kendall BE, Neville BG, Stanhope R, Watkins KE, *et al*. Management of childhood craniopharyngioma: Can the morbidity of radical surgery be predicted? *J Neurosurg* 1996;85:73-81.
16. Fahlbusch R, Honegger J, Buchfelder M. Clinical features and management of craniopharyngiomas in adults. In: Tindall GT, Cooper PR, Barrow DL, editors. *The Practice of Neurosurgery*. Baltimore: Williams and Wilkins; 1996. p. 1159-73.
17. Weiss M, Sutton L, Marcial V, Fowble B, Packer R, Zimmerman R, *et al*. The role of radiation therapy in the management of childhood craniopharyngioma. *Int J Radiat Oncol Biol Phys* 1989;17:1313-21.

How to cite this article: Bidur KC, Prasad DU. Outcome following surgical resection of craniopharyngiomas: A case series. *Asian J Neurosurg* 2017;12:514-8.

Source of Support: Nil, **Conflict of Interest:** None declared.