

## CASE REPORT

# Sino-nasal T-cell lymphoma invading the brain: A case study

Srikanth Reddy, Ashish Kumar, Rajesh Allugolu, Megha Uppin<sup>1</sup>, Keshav Ramgopal<sup>2</sup>

Departments of Neurosurgery, <sup>1</sup>Pathology and <sup>2</sup>Radiation Oncology, Nizam's Institute of Medical Sciences, Punjagutta, Hyderabad, Andhra Pradesh, India

## ABSTRACT

Lesions occupying the anterior cranial fossa may arise *de novo* or are extensions from the sino-nasal areas with a handful of differentials in either group. The imaging findings, though to a large extent standardized are not full proof. Primary central nervous system lymphoma and sino-nasal lymphoma are uncommon variants of extranodal non-Hodgkin's lymphoma (NHL). We encountered a 35-year-old lady presenting with headache and seizures with a mass lesion involving the ethmoids with invasion into the anterior cranial fossa diagnosed as T-cell extranodal NHL. Gross total resection and reconstruction of the skull base were done. She was treated with chemotherapy and radiotherapy and is doing well at 6 months follow-up. This is the first report of a sino-nasal T-cell lymphoma invading the brain-parenchyma in an immuno-competent person. Sino-nasal primary T-cell lymphoma presenting as skull base pathology should form an essential differential diagnosis along with other routine lesions of anterior cranial fossa. Since these lesions have a good response to chemo and radiotherapy, a trans-nasal biopsy may obviate the need of a craniotomy if neurosurgeons are aware of this rare entity.

**Key words:** Immunohistochemistry, lymphoma, sino-nasal, T-cell

## Introduction

Primary T-cell central nervous system (CNS) lymphoma is a rare form of extranodal non-Hodgkin's lymphoma (NHL) constituting <5% of all and affecting any part of the neuraxis including the eyes, brain, leptomeninges, and spinal cord. Majority of these are high-grade B-cell type despite the fact that B-cells are absent from normal brain.<sup>[1,2]</sup> The incidence of the T-cell phenotype is only 1-4% in these cases, usually presenting with leptomeningeal spread and neurolymphomatosis.<sup>[3]</sup> Primary NHL affecting the nasal cavities and paranasal sinuses account for <3% of all malignant extranodal lymphomas.<sup>[4]</sup> To the best of our knowledge, there are only three cases of ethmoidal B-cell lymphomas reported in the literature.<sup>[5]</sup> There is no

published report of an ethmoidal T-cell lymphoma invading the brain-parenchyma, and we report the first of its kind and review the existing literature till date.

## Case Report

A 35-year-old lady presented to us with a history of dull aching intermittent headache involving the frontal and retro bulbar region for past 14 months and two episodes of generalized tonic and clonic seizures in last 10 days. Frontal lobe dysfunctions in the form of subtle behavioral abnormalities were present. Magnetic resonance imaging detected an irregular lesion, of size 43 mm × 39 mm × 27 mm, isointense on T1-weighted and T2-weighted sequences arising from bilateral ethmoids, and upper nasal cavity involving the nasal septum extending through the cribriform plate to invade the basi-frontal region bilaterally (left > right). The lesion was well-enhancing on contrast imaging [Figure 1]. The differentials thought were (a) esthesioneuroblastoma, (b) fungal granuloma, and (c) sino-nasal malignancy. The patient underwent left frontal craniotomy, and a moderately vascular, soft tumor was seen in the basi-frontal region with invasion and extension across the dura and the cribriform plate into the ethmoidal sinus and the nasal cavity. The tumor was well-separated from the brain with an intervening pial surface on the right side, whereas the brain-parenchyma was infiltrated on the left side. The ethmoidal and nasal portions of the lesion were excised from the cranial end only. Gross total excision

### Access this article online

#### Quick Response Code:



#### Website:

www.asianjns.org

#### DOI:

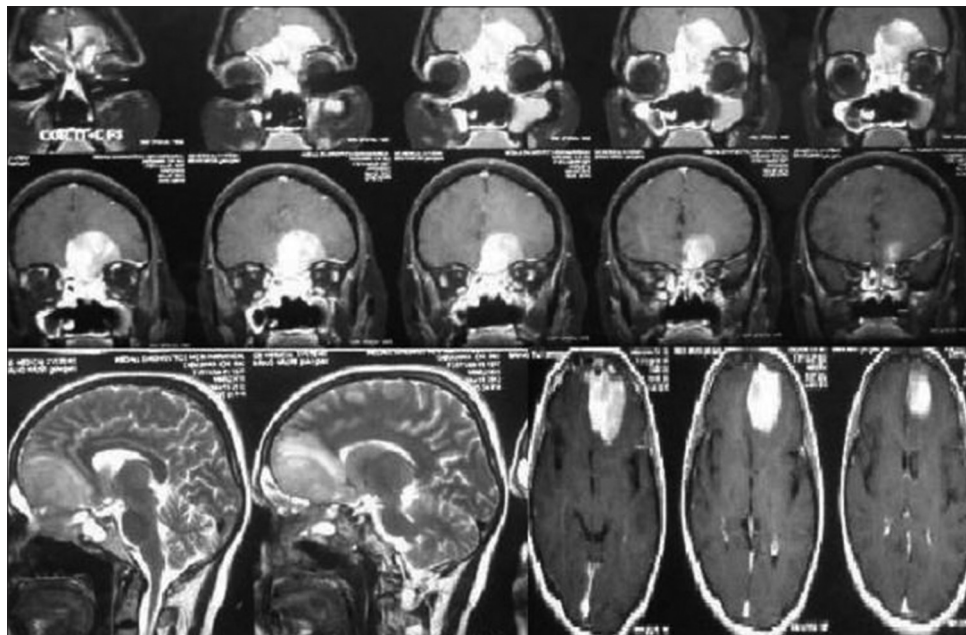
10.4103/1793-5482.146626

### Address for correspondence:

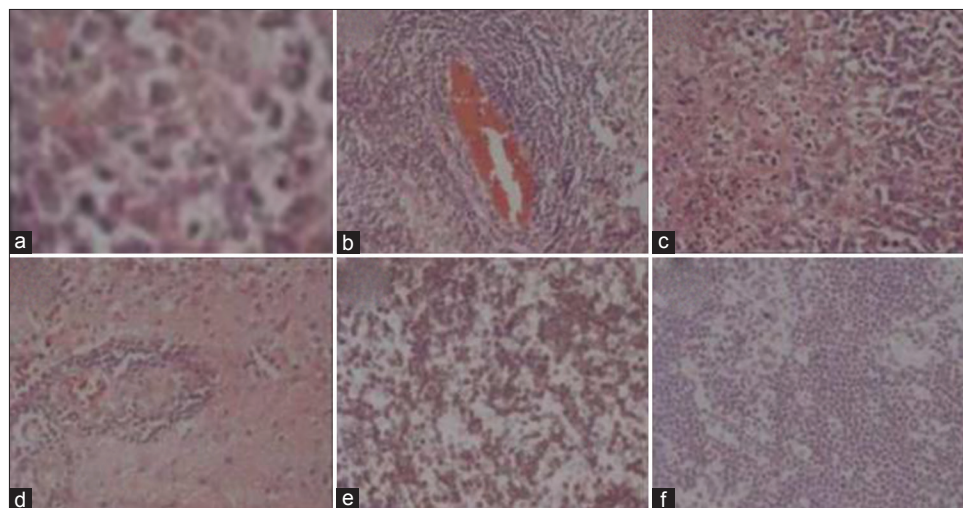
Dr. Ashish Kumar, Department of Neurosurgery, Nizam's Institute of Medical Sciences, Punjagutta, Hyderabad - 500 082, Andhra Pradesh, India. E-mail: drashishmch@hotmail.com

of the lesion was done. The frontal sinus was packed with fat graft and exteriorized using pericrania. The anterior skull base defect was reconstructed by placement of split calvarial bone graft with fascia lata and fibrin glue. Microscopic examination showed lesion compromising of cells arranged in sheets. Cells were discrete with vesicular nuclei and scanty cytoplasm and inconspicuous nucleoli. There were multiple areas of necrosis and cells were infiltrating brain tissue. Immunocytochemistry demonstrated positivity for leucocyte common antigen, neuron-specific enolase, CD3, and negative for synaptophysin, CD20, Tdt. Ki index was 76%. This confirmed the histopathological diagnosis of extra nodal NHL (T-cell type) Ann Arbor stage I-E [Figure 2]. Postoperative computed tomography (CT) scan showed

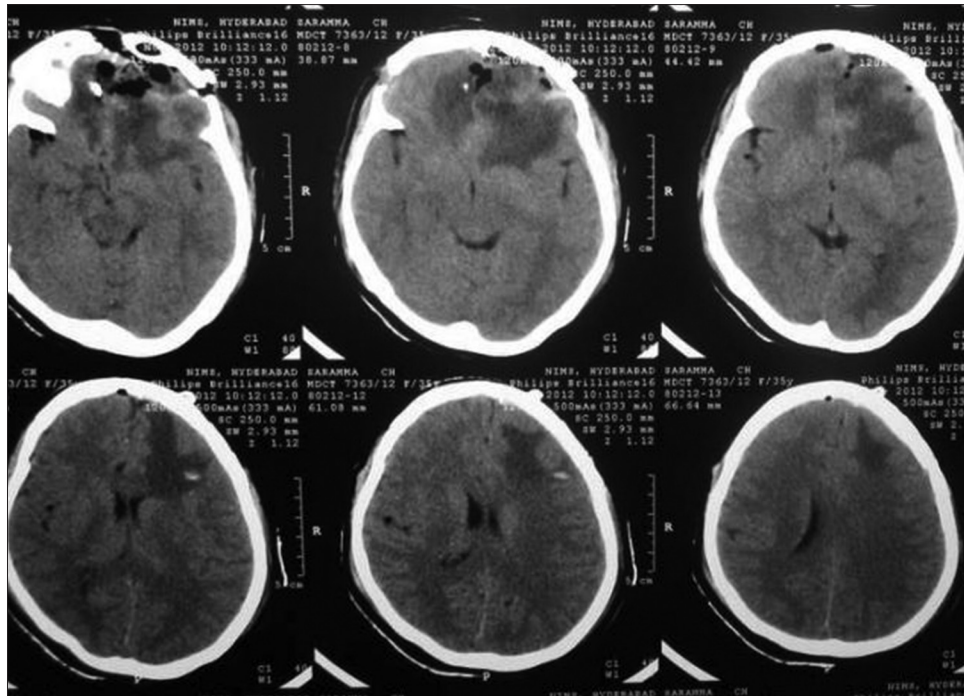
gross total excision of the lesion [Figure 3]. The patient recovered well only to develop delayed cerebrospinal fluid (CSF) rhinorrhea on 8<sup>th</sup> postoperative day, which was managed with lumbar CSF drainage. Patient was discharged after 14 days. Subsequently, the patient was screened and investigated for any systemic evidence of any other primary source of malignancy by CT chest and abdomen; all being negative. This led to the diagnosis of primary T-cell lymphoma of the ethmoid sinus invading the brain. She was subjected to 54 Gy radiotherapy (1.8 Gy/fraction 30 fractions) with 2-3 cm margin over primary tumor; paranasal sinuses being also included. This was later on followed by chemotherapy. She is doing well at 6 months follow-up.



**Figure 1:** Magnetic resonance imaging brain showing intensely enhancing lesion of the ethmoids invading brain via the cribriform plates



**Figure 2:** (a) The photomicrograph small round cells arranged discretely. The cells are larger than small lymphocytes and show nuclear folding. (b) Angiocentric distribution of cells. (c) Many areas of coagulative necrosis with apoptotic bodies. (d) The cells infiltrating brain parenchyma. (e) Intense CD3 positivity in the cytoplasm of round cells. (f) The cells are negative for CD20



**Figure 3:** Postoperative scan showing complete excision of the lesion

## Discussion

Primary T-cell CNS lymphoma (5%) may present with leptomeningeal involvement as the sole manifestation (neuronal lymphomatosis) or presenting symptoms may also include signs of elevated intracranial pressure and neuropathies. On the other hand, more than 60% of NHLs of the head and neck occur in the extra nodal sites, such as the paranasal sinuses, nasal cavity, oral cavity, salivary glands, and laryngopharynx.<sup>[3,4]</sup> NHLs of the sino-nasal tract are uncommon malignancies representing 3-5% of all. The most common histological type is angiocentric lymphoma (35.9%), followed by B-cell lymphoma (22.6%), peripheral T-cell lymphoma (15.1%), and other lymphomas of nonspecific types.<sup>[6]</sup> In Western population, lymphomas of the maxillary sinus are more common than in the nasal cavity while the latter is predominantly involved in Asian populations.<sup>[7]</sup> The most common presenting feature is a mass or swelling (59%), with minimal symptoms: Pain (21%), dysphasia (7.9%), weight loss (1.1%), night sweats (0.5%), and nasal obstruction (7.9%).<sup>[8]</sup> Immuno-deficiency and infectious agents such as Epstein-Barr virus and human T-lymphotropic virus-1 have been suggested as the possible aetiologies.<sup>[9,10]</sup> They have varied histological features and clinical behaviors. The major determinants of the clinical course and prognosis are the type of cell origin (T- or B-cell) and pattern of growth within the lymph nodes.<sup>[10]</sup> T-cell lymphomas are virtually nonexistent in the brain and as stated above they are commonly seen in the paranasal sinuses. However, no previous case of sino-nasal T-cell lymphoma invading the brain-parenchyma has been reported so far.<sup>[11]</sup>

Sino-nasal lymphomas can usually be tackled via endoscopic-endonasal route. However, those that invade through the cribriform plate into the brain resulting in mass effect may require trans-cranial approach as well. Biopsy usually suffices, and the rest of the treatment is taken care of by chemo-radiotherapy<sup>[12]</sup> Hart *et al.*, in his review of 580 patients with lymphoma, noted that relatively high (over one-third) proportion of patients had excisional surgery, suggesting the importance of diagnostic biopsy before proceeding to definitive surgery.<sup>[6]</sup> In retrospect, a nasal biopsy would have sufficed in our patient too, if the diagnosis was speculated before surgery. The most common chemotherapeutic regimen is the cyclophosphamide, doxorubicin, vincristine, prednisone (CHOP) regimen or CHOP-like regimens. The number of chemotherapy cycles range from one to nine (median, four cycles).<sup>[13]</sup> The addition of rituximab to CHOP chemotherapy, given for eight cycles to elderly patients with newly diagnosed diffuse large-B-cell lymphoma, significantly increases the rate of complete response.<sup>[14-16]</sup>

## Conclusion

Primary T-cell NHL arising from the ethmoid sinus eroding through the cribriform plate and progressing further to involve the leptomeninges and brain-parenchyma in the basi-frontal region should be kept as one of the differentials for aberrant crypt foci lesions involving sinuses apart from infections. Henceforth, biopsy followed by adjuvant chemo and radiotherapy should be the preferable mode of management. Surgery must be best kept as a salvage procedure in these patients.

## References

- Gijtenbeek JM, Rosenblum MK, DeAngelis LM. Primary central nervous system T-cell lymphoma. *Neurology* 2001;57:716-8.
- Miller DC, Hochberg FH, Harris NL, Gruber ML, Louis DN, Cohen H. Pathology with clinical correlations of primary central nervous system non-Hodgkin's lymphoma. The Massachusetts General Hospital experience 1958-1989. *Cancer* 1994;74:1383-97.
- Hayabuchi N, Shibamoto Y, Onizuka Y. Primary central nervous system lymphoma in Japan: A nationwide survey. *Int J Radiat Oncol Biol Phys* 1999;44:265-72.
- Frierson HF Jr, Mills SE, Innes DJ Jr. Non-Hodgkin's lymphomas of the sinonasal region: Histologic subtypes and their clinicopathologic features. *Am J Clin Pathol* 1984;81:721-7.
- Wang J, Sun NC, Weinstein SM, Canalis R. Primary T-cell-rich B-cell lymphoma of the ethmoid sinus. A case report with 5 years of follow-up. *Arch Pathol Lab Med* 2000;124:1213-6.
- Hart S, Horsman JM, Radstone CR, Hancock H, Goepel JR, Hancock BW. Localised extranodal lymphoma of the head and neck: The Sheffield Lymphoma Group experience (1971-2000). *Clin Oncol (R Coll Radiol)* 2004;16:186-92.
- Yamanaka N, Harabuchi Y, Sambe S, Shido F, Matsuda F, Kataura A, *et al.* Non-Hodgkin's lymphoma of Waldeyer's ring and nasal cavity. Clinical and immunologic aspects. *Cancer* 1985;56:768-76.
- Ng CS, Chan JK, Lo ST, Poon YF. Immunophenotypic analysis of non-Hodgkin's lymphomas in Chinese. A study of 75 cases in Hong Kong. *Pathology* 1986;18:419-25.
- Quraishi MS, Bessell EM, Clark D, Jones NS, Bradley PJ. Non-Hodgkin's lymphoma of the sinonasal tract. *Laryngoscope* 2000;110:1489-92.
- Hennessy BT, Hanrahan EO, Daly PA. Non-Hodgkin lymphoma: An update. *Lancet Oncol* 2004;5:341-53.
- Flowers CR, Sinha R, Vose JM. Improving outcomes for patients with diffuse large B-cell lymphoma. *CA Cancer J Clin* 2010;60:393-408.
- Juweid M, DeNardo GL, Graham M, Vose J. Radioimmunotherapy: A novel treatment modality for B-cell non-Hodgkin's lymphoma. *Cancer Biother Radiopharm* 2003;18:673-4.
- Armitage JO. How I treat patients with diffuse large B-cell lymphoma. *Blood* 2007;110:29-36.
- A clinical evaluation of the International Lymphoma Study Group classification of non-Hodgkin's lymphoma. The Non-Hodgkin's Lymphoma Classification Project. *Blood* 1997;89:3909-18.
- Fisher RI, Gaynor ER, Dahlborg S, Oken MM, Grogan TM, Mize EM, *et al.* Comparison of a standard regimen (CHOP) with three intensive chemotherapy regimens for advanced non-Hodgkin's lymphoma. *N Engl J Med* 1993;328:1002-6.
- Coiffier B, Lepage E, Briere J, Herbrecht R, Tilly H, Bouabdallah R, *et al.* CHOP chemotherapy plus rituximab compared with CHOP alone in elderly patients with diffuse large-B-cell lymphoma. *N Engl J Med* 2002;346:235-42.

**How to cite this article:** Reddy S, Kumar A, Allugolu R, Uppin M, Ramgopal K. Sino-nasal T-cell lymphoma invading the brain: A case study. *Asian J Neurosurg* 2014;9:235.

**Source of Support:** Nil, **Conflict of Interest:** None declared.