

Morphometric analysis of posterior fossa in Indian CP angle acoustic schwannoma patients

Mohana Rao Patibandla, Manas K. Panigrahi¹, Paniraj L. Gurrani¹, Amit Kumar Thotakura², Dilip Kulkarni³

Departments of Neurosurgery, Nizam's Institute of Medical Sciences, Hyderabad, ¹Krishna Institute of Medical Sciences, Hyderabad, Telangana, ²NRI Academy of Sciences, Mangalagiri, Andhra Pradesh, ³Department of Anesthesiology, Nizam's Institute of Medical Sciences, Hyderabad, Telangana, India

ABSTRACT

Aim: To study the morphometry of posterior fossa in Indian CP angle schwannoma patients in order to know its influence on the extent of excision of the CP angle acoustic schwannomas.

Materials and Methods: One hundred cases of cerebellopontine angle schwannomas treated surgically by the senior author and 20 controls between January 2006 and June 2011 were consecutively investigated with computed tomography (CT) using the high-resolution CT bone windows before surgery. Evaluation of anatomic parameters of the petrous bone and posterior fossa cavity were done in all patients and controls. Data were entered in Excel software and were analyzed using NCSS software. All possible regression analysis was done to select the important variables to be included in the model to predict the excision of tumor with these variables. A prediction model was developed defining the binary outcome as total excision or subtotal excision as dependent variable and the morphometric data and grading of tumor as independent variables.

Results: Interpetrous distance (IP) is the distance between the two petrous apices. Sigmoid distance (IS) distance is the distance between the two sigmoid points. Sigmoid point is the point at which the scalloped impression of the sigmoid sinus straightens to join the occipital bone posteriorly. SAG is the distance between the mid IP point and the mid-point on the inner wall of the occipital bone. The PM angle was 47.8 ± 4.14 degrees (38-58), the PA angle was 42.68 ± 4.47 degrees (34-53), the IP distance was 2.07 ± 0.13 cm (1.5-2.8), the sagittal diameter of posterior fossa was 6.22 ± 0.73 cm (5.1-9.8) and the intersigmoid distance was 9.45 ± 0.73 cm (7.4-11). There was no significant gender difference in the posterior fossa morphometry between patients and controls. Inter-sigmoid distance and the petrous-apex angle were more in the Indians when compared to the European population mentioned in the Mathies and Samii study.

Conclusions: The posterior fossa morphological parameters of the Indian and European population differ significantly. Inter-sigmoid distance and the petrous-apex angle were more in the Indians when compared to the Europeans. There is no significant gender difference in the morphometry of the Indians. There is no significant difference between the patients and the control groups. In our study the adhesions with surrounding structures along with the posterior fossa morphometry significantly affect the extent of excision.

Key words: Angles, cerebellopontine angle angle tumors, morphometry, posterior fossa, schwannoma

Access this article online

Quick Response Code:



Website:

www.asianjns.org

DOI:

10.4103/1793-5482.145308

Introduction

Many authors have also proposed various classification systems and surgical approaches to excise CP angle tumors. Most of these classifications are based on the size (largest diameter) of the tumor.^[1] Apart from the size of the tumor, many parameters affect the excision of the tumor. In the present literature, there are a very few studies which analyzed the morphology of the posterior fossa and its effect on the excision.^[2] In this study, we tried to analyze and compare the posterior fossa morphology between Indian patients and control population and European population and also tried to

Address for correspondence:

Dr. Manas K. Panigrahi, Department of Neurosurgery, Krishna Institute of Medical Sciences, Hyderabad - 500 003, Andhra Pradesh, India. E-mail: manaspanigrahi@live.com

stratify the effect of the posterior fossa morphology on the extent of excision.

Materials and Methods

The study design is a prospective study done between January 2006 and June 2011. All primary CP angle schwannomas that were operated during the study period and had a minimum of 6 months follow up were included. Recurrent or residual tumors were excluded. Fifty-four (54%) patients were female and forty-six (46%) were male. There were four patients in 0-20 years age range group, 56 in 21-40 age range, 30 in 41-60 age range and 10 in the age range >60 years. The mean age was 42.61 ± 13.26 years (range of 11-77 years). Ten (50%) controls were female and ten (50%) were male. There were 14 in 21-40 age range, 6 in 41-60 age range. The mean age was 36.4 ± 8.22 years (range of 21-55 years). European population posterior fossa craniometry was taken from article published by Mathies and Samii.^[1]

The anatomic parameters of the petrous bone and posterior fossa cavity were evaluated in all the patients and controls. With the help of CT scan, thin inner ear 1 mm bone sections were taken preoperatively and morphology of the posterior fossa was analyzed. Parameters like interpetrous distance (IP), sagittal diameter (SAG), inter sigmoid distance (IS), petrous midst angle (PM), and petrous apex angle (PA) were analyzed in each patient and control group [Figure 1].

IP is the distance between the two petrous apices. IS distance is the distance between the two sigmoid points. Sigmoid point is the point at which the scalloped impression of the sigmoid sinus straightens to join the occipital bone posteriorly. SAG is the distance between the mid IP point and the mid-point on the inner wall of the occipital bone. If this point happened to be on the apex of a bony spicule, then the SAG distance was

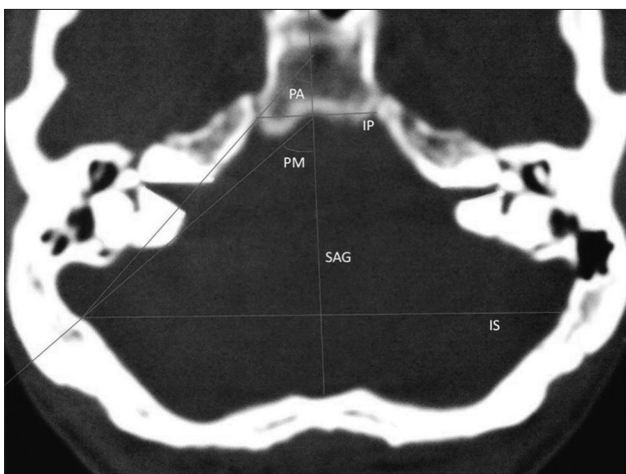


Figure 1: Morphometric analysis of the posterior fossa with different parameters. IP: Interpetrous distance, IS: Intersigmoid distance, PA: Petrous apex angle, PM: Petrous-midst angle, SAG: Sagittal diameter of posterior fossa

measured from mid IP point to a point on the base of this spicule, as the spicule will not greatly alter the volume of the posterior fossa. PM is the angle between the SAG line and the line connecting the sigmoid and mid IP points. PA is the angle between the SAG line and a line connecting the sigmoid point and petrous apex.

Grade-1 tumors were those which were seen extending around the ipsilateral internal auditory meatus (IAC). Grade-2 tumors were those which extended from ipsilateral IAC to the ipsilateral petrous apex. Grade-3 tumors extended from ipsilateral IAC to contralateral petrous apex. Grade-4 tumors extended from ipsilateral IAC to contralateral IAC. Grade-5 tumors were those grade-3 or grade-4 tumors that had an additional extension up to the jugular tubercle [Figure 2]. Grade-1 and 2 tumors were resected by retrosigmoid approach. Grade-3 tumor was resected by presigmoid approach, grade-4 tumor by a combination of presigmoid and retrosigmoid approach and grade-5 tumor by either the trans-sigmoid approach or combination of presigmoid and retrosigmoid approach [Table 1].

Results

When all the patients were considered, the PM angle was 47.8 ± 4.14 degrees (38-58), the PA angle was 42.68 ± 4.47 degrees (34-53), the IP distance was 2.07 ± 0.13 cm (1.5-2.8), the sagittal diameter of posterior fossa was 6.22 ± 0.73 cm (5.1-9.8), and the intersigmoid distance was 9.45 ± 0.73 cm (7.4-11) [Table 2].

In men, the PM angle was 47.8 ± 4.1 degrees, the PA angle was 42.6 ± 4.2 degrees, the IP distance was 2.02 ± 0.3 cm, the sagittal diameter of posterior fossa was 6.2 ± 0.7 cm, and the intersigmoid distance was 9.5 ± 0.8 cm. In female patients, the PM angle was 47.9 ± 5.1 degrees, the PA angle was 42.7 ± 4.5 degrees, the IP distance was 2.1 ± 0.3 cm (1.5-2.8), the sagittal diameter of posterior fossa was 6.2 ± 0.8 cm, and the intersigmoid distance was 9.23 ± 0.1 cm [Table 2].

Table 1: Grade of the tumor and approach used

Grade	Extent of tumor	Approach
I	Ipsilateral IAC	Retrosigmoid
II	Ipsilateral IAC Ipsilateral petrous apex	Retrosigmoid
III	Ipsilateral IAC Ipsilateral petrous apex Contralateral petrous apex	Presigmoid
IV	Ipsilateral IAC Ipsilateral petrous apex Contralateral petrous apex, Contralateral IAC	Presigmoid+Retrosigmoid
V	Grade III or IV with extension up to Jugular tubercle	Presigmoid+Retrosigmoid OR Trans-sigmoid

IAC – Internal auditory canal . Manas, Mohan and Paniraj grading. There were 39 grade 1, 53 grade 2, 5 grade 3, 2 grade 4, and 1 grade 5 tumors

In controls, the PM angle was 49.82 ± 3.9 degrees, the PA angle was 44.2 ± 4.3 degrees, the IP distance was 2.14 ± 0.3 cm, the sagittal diameter of posterior fossa was 6.31 ± 0.6 cm, and the intersigmoid distance was 9.475 ± 0.8 cm [Table 2].

There were 39 Grade 1, 53 grade 2, 5 grade 3, 2 grade 1, and 1 grade 5 tumors. The representative pictures were shown in Figure 2. Complete excision was achieved in 82 cases (82%) and subtotal excision in 18 cases (18%). The total excision was achieved in 36 cases of grade 1, 43 in grade 2, 2 in grade 3, and 1 in grade 4 tumors. Sub-total excision was done in 3 of grade 1, 10 of grade 2, 3 of grade 3, and one each of grade 4 and 5 tumors [Table 3].

Post-operative complications were noted in 18 cases (18%). Seven cases had wound site CSF leak and out of which two cases developed meningitis and one case had cranial nerve palsy. Three cases had developed hemiparesis and out of which one case had developed operative site hematoma. Four cases had additional cerebellar signs out of which two cases had additional cranial nerve palsy. Four cases had only cranial nerve palsies.

Prediction model for outcome of surgery was done by using NCSS software. A total of 11 variables initially selected to analyze their effect on extent on tumor resection and they were the proposed Grade of the tumor, sagittal length of posterior fossa (SAG), axial extension of the tumor, pathology of the tumor, petrous midst angle (PM), coronal extension of

the tumor, petrous apex angle (PA), age of the patient, sagittal extension of the tumor, inter sigmoid distance (IS), and width of petrous apex (IP) [Table 4].

The proposed grade of the tumor was the only variable that had a significant P value [Table 5].

All possible regression analysis was done to select the important variables to be included in the model to predict the outcome and only four variables, namely grade of tumor, sagittal diameter of posterior fossa, PM, sagittal extension of the tumor, were found to be useful in the model [Table 6].

A regression model was developed by multinomial logistic regression analysis with these four parameters and the regression equation is as follows:

$$(XB) = -0.22 - (1.61 \times \text{Grade of tumor}) + (0.121 \times \text{PM}) - (0.53 \times \text{SAG}) + (0.563 \times \text{Sagittal})$$

Table 3: Grade vs Excision (n=100)

Grade	Total	Subtotal
1	36	3
2	43	10
3	2	3
4	1	1
5	0	1

Table 2: Morphometry of posterior fossa Caucasians vs Indians

	Male		Female		All patients		Controls Indians
	Caucasians	Indians	Caucasians	Indians	Caucasians	Indians	
IP	2.8±0.4 cm	2.02±0.3 cm	2.6±0.4 cm	2.1±0.3 cm	2.72±0.6 cm	2.07±0.13 cm	2.14±0.3 cm
SAG	6.8±0.46 cm	6.2±0.7 cm	6.2±0.6 cm	6.2±0.8 cm	6.49±0.4 cm	6.22±0.73 cm	6.31±0.6 cm
IS	9.4±1.15 cm	9.5±0.8 cm	9.0±1.1 cm	9.4±0.75 cm	9.23±1.1 cm	9.45±0.73 cm	9.47±0.8 cm
PM	63.5±12 degrees	47.8±4.1 degrees	65.0±9.4 degrees	47.9±5.1 degrees	64.4±7.9 degrees	47.8±4.14 degrees	49.82±3.9 degrees
PA	33.8±8.7 degrees	42.6±4.2 degrees	31.0±7.5 degrees	42.7±4.5 degrees	32.4±8.7 degrees	42.6±4.47 degrees	44.2±4.3 degrees

IP – Interpetrous distance; IS – Intersigmoid distance; PA – Petrous apex angle; PM – Petrous-midst; SAG – Sagittal diameter of posterior fossa

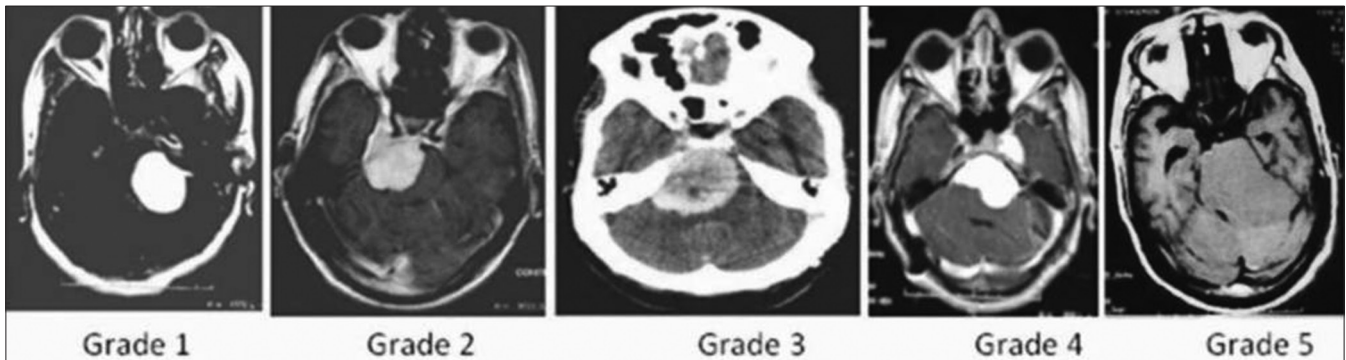


Figure 2: Proposed grading system for the CP angle schwannomas: Grade-1: Extending around the ipsilateral IAC. Grade-2: Extended from ipsilateral IAC to the ipsilateral PA. Grade-3: Extended from Ipsilateral IAC to contralateral PA. Grade-4: Extended from ipsilateral IAC to contralateral IAC. Grade-5: Grade-3 or grade-4 tumors that had an additional extension up to the jugular tubercle

Probability of excision is then given by the formula $1/(1 + \text{Exp}(-XB))$.

Overall accuracy of the model in predicting the outcome of excision was 85%. Sensitivity and specificity were 87.5 and 62.5%. Area under the ROC curve was 0.78 for total and 0.79 for sub-total excision, indicating that the regression equation model used to predict the outcome of surgical excision was a fair one [Figure 3].^[3]

Discussion

Cerebellopontine angles (CPA) tumors are the most common neoplasms in the posterior fossa, accounting for 5-10% of intracranial tumors. Most CPA tumors are benign, with vestibular schwannomas accounting for approximately 80% of tumors. The most frequent non-acoustic CPA tumors are meningiomas (3-13%), epidermoids (2-6%), and facial or lower cranial nerve schwannomas (1-2%).^[1,4-8] In CP angle, schwannoma surgery size of the tumors influences the outcome.^[1] Most of our cases had large and giant tumors (large 2.5-4 cm, giant >4 cm), as reported in other Indian studies and in contrast to the various western series which had small tumors (<2.5 cm).^[1,4,6-9] This is mainly due to delayed diagnosis and management due to socioeconomic constraints prevailing here. Out of 100 vestibular schwannomas, 80 (80%) were giant tumors.

In literature, most authors have evaluated vestibular schwannomas and other CP angle tumors separately. This is because of the high incidence of vestibular schwannomas in this region and also its pathophysiology varies from other tumors.^[4-7,9-12] In our series, we had achieved 82% (82/100) total removal of vestibular schwannomas by the retrosigmoid approach, which is comparable to other Indian and western studies. Samii. *et al.* in their series of surgical outcome for 1000 cases of vestibular schwannomas by Retrosigmoid approach reported that, 979 cases had complete tumor

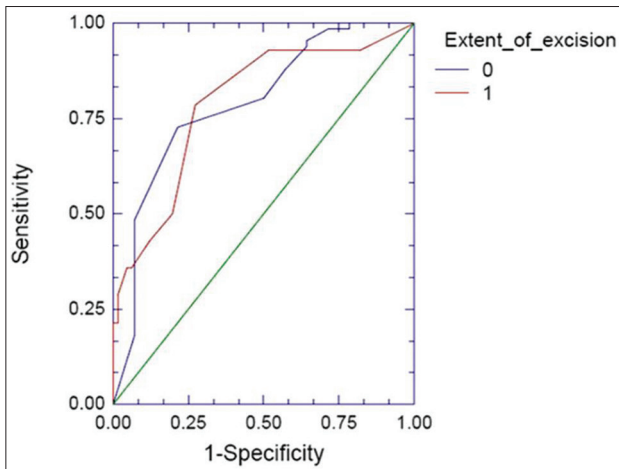


Figure 3: ROC curve of extent of excision with sensitivity and specificity

Table 4: Independent variables measured

Variable	Range	Mean±SD
Age	11-77	39.61±13.54 years
Grade	1-5	1.75
Coronal (tumor)	0.2-8.8	3.57±1.11
Sagittal (tumor)	1.8-6.5	4.36±0.99
Axial	1-8	3.17±1.02
PM	38-58	47.81±/-4.14
PA	34-53	42.68±/-4.47
IP	1.5-2.8	2.07±0.13
SAG	5.1-9.8	6.22±0.73
IS	7.4-11	9.45±0.73

IP – Interpetrous distance; IS – Intersigmoid distance; PA – Petrous Apex angle; PM – Petrous-Midst; SAG – Sagittal diameter of Posterior fossa

Table 5: Effect of all independent variables analyzed

Variable	Chi² Wald	P value
Age	0.164	0.6855
Pathology	0.884	0.3472
Grade of the tumour	9.444	0.0021
Sagittal	3.054	0.0805
Coronal	0.119	0.7306
Axial	2.167	0.141
PM	-0.308	1
PA	-0.297	1
PM-PA	-0.304	1
IP	0.747	0.3875
SAG	0.699	0.4032
IS	0.114	0.7362

IP – Interpetrous distance; IS – Intersigmoid distance; PA – Petrous apex angle; PM – Petrous-midst; PM-PA – Petrous-midst angle minus petrous apex angle; SAG – Sagittal diameter of posterior fossa

Table 6: All possible regression analysis

Model size	R-squared	Variables in this best model
1	0.141422	Grade of tumor
2	0.175587	Grade of the tumor, SAG
3	0.194069	Grade of the tumor, Sagittal, SAG
4	0.212528	Grade of the tumor, Sagittal, PM, SAG
5	0.228466	Grade of the tumor, Sagittal, Axial, PM, SAG
6	0.240929	Grade of the tumor, Sagittal, Axial, PM, IP, SAG
7	0.246214	Pathology, grade of the tumor, sagittal, axial, PM, IP, SAG
8	0.251477	Pathology, grade of the tumor, sagittal, axial, PM, PA, IP, SAG
9	0.256675	Pathology, grade of the tumour, sagittal, coronal, axial, PM, PA, IP, SAG
10	0.257241	Age, pathology, grade of the tumour, sagittal, coronal, axial, PM, PA, IP, SAG
11	0.257540	Age, pathology, grade of the tumour, sagittal, coronal, axial, PM, PA, IP, SAG, IS

IP – Interpetrous distance; IS – Intersigmoid distance; PA – Petrous apex angle; PM – Petrous-midst; PM-PA – Petrous-midst angle minus petrous apex angle; SAG – Sagittal diameter of posterior fossa

resection. In 21 cases, deliberate subtotal tumor removal was performed.^[7] Jain *et al.* reported 96.5% (250/259 Vestibular schwannomas) total excision.^[9] Yamakani *et al.* reported 86% total removal of large vestibular schwannomas.^[13] Ebersold *et al.* reported 97.2% total excision.^[14] All these authors had approached the tumor by Retrosigmoid approach, irrespective of the tumor size. Roland *et al.* reported 73% total removal for large tumors by using the translabrynthine and retrosigmoid approaches.^[15] Lanman *et al.* reported 96.3% of total removal by trans-labyrinthine approach.^[16]

The reported incidence of CSF leak varies from 0 to 30% and in our series it was 7%.^[6] However, the incidence of meningitis in our series was only 2%, which is much less than that reported in the literature (3.7-9.2%).^[6] We have made use of percutaneous esophagostomy (PEG) in patients with severe lower cranial nerve palsy, both pre- and post-operatively for the purpose of feeding and to prevent aspiration.

Morphometric analysis of the posterior fossa and its influence on the surgical outcome in European population was done by Matthies and Samii *et al.*^[1] We have tried to analyze the similar morphometric data in South Indian CP angle schwannoma patients. When compared to their western counterparts, the inter-sigmoid distance and the petrous-apex angle were more in the Indians. Unlike their western counterparts, there was no significant difference in morphological parameters between Indian men and women. There is no significant statistical difference (0.19) between the patients and controls [Table 1].

In our study of surgical excision of CP angle schwannomas, we had noted that 82 out of 100 cases had complete surgical excision [Table 3]. We have done the subtotal excision in some of these cases to preserve the seventh nerve preservation. Of the various factors influencing total surgical excision, we had statistically found that PM angle and SAG distance were two predictive morphological factors. Petrous-midst angle and the sagittal extension of the tumor had a positive influence on the total excision of the tumor. When analyzed logically, larger the size of the tumor, higher is the difficulty to excise it. As the sagittal diameter of posterior fossa increases or the PM angle decreases, the shallower it becomes and more will be the difficulty to visualize the structures around the brainstem area and greater will be the probability of sub-total excision.

Eighteen out of one-hundred cases in our study could not be totally excised because the tumor was firmly adherent to the brainstem, surrounding nerves and vessels or because the posterior fossa was narrower requiring excessive cerebellar retraction to visualize all the structures. Arbitrarily, we had classified the posterior fossa into narrow or wide based on the PM angle and SAG distance (as these two parameters were significant in our prediction model). PM angle less than 45 degrees and/or SAG distance of more than 6.5 cm was

considered narrow fossa and wide fossa was considered if PM angle of 45 degrees or more and SAG distance of 6.5 cms or less.

Size of the tumor, heterogeneous nature of the tumour consistency, extension of the tumor more anterior, and caudal to IAC, pre-existing neurological deficits and cardiopulmonary compromise have negative influence on the outcome of the surgery with regard to total excision, facial nerve preservation, and auditory function.^[2] In our series in 12 out of 18 cases (66.6%) the total excision was not possible due to a narrow posterior fossa and in 3 out of the 8 cases with subtotal excision and adhesion, post-operative neurological deficits were observed. A wide posterior fossa was noted in 77 cases (77%) where total excision was performed. A total of 12 patients developed neurological deficits in narrow posterior fossa group due to total excision. So in order to attempt total excision apart from the facial nerve function, posterior fossa morphometry and adhesions are very important factors. The knowledge of the volume of the tumor and posterior fossa (which were not measured here) might have an influence on the outcome of surgery and this needs further study.

Conclusions

The posterior fossa morphological parameters of the Indian and European population differ significantly. There is no significant gender difference in the morphometry of the Indian CP angle schwannoma patients. Inter-sigmoid distance and the petrous-apex angle were more in the Indians when compared to the Europeans. As the sagittal diameter of posterior fossa increases or the PM angle decreases, the shallower it becomes and more will be the difficulty to visualize the structures around the brainstem area and greater will be the probability of sub-total excision in order to prevent complications. Finally, our study proved the adhesions with surrounding structures along with the posterior fossa morphometry that significantly affect the extent of excision.

References

1. Gormley WB, Sekhar LN, Wright DC, Kamerer D, Schessel D. Acoustic neuromas: Results of current surgical management. *Neurosurgery* 1997;41:50-60.
2. Matthies C, Samii M, Krebs S. Management of vestibular schwannomas (acoustic neuromas): Radiological features in 202 cases: Their value for diagnosis and their predictive importance. *Neurosurgery* 1997;40: 469-82
3. Swets JA. Measuring the accuracy of diagnostic systems. *Science* 1988;240:1285-93.
4. Mallucci CL, Ward V, Carney AS, O'Donoghue GM, Robertson I. Clinical features and outcomes in patients with non-acoustic cerebellopontine angle tumors. *J Neurol Neurosurg Psychiatry* 1999;66:768-71.
5. Springborg JB, Poulsen L, Thomsen J. Nonvestibular schwannoma tumors in the cerebellopontine angle: A structured approach and management guidelines. *Skull base* 2008;18:217-27.
6. Matthies C, Samii M. Management of 1000 vestibular schwannomas (acoustic neuromas): Clinical presentation. *Neurosurgery* 1997; 40:1-10.
7. Samii M, Matthies C. Management of 1000 vestibular schwannomas (acoustic neuromas): Surgical management and results with an

- emphasis on complications and how to avoid them. *Neurosurgery* 1997;40:11-23.
8. Sekhar LN, Jannetta PJ. Cerebellopontine angle meningiomas-microsurgical excision and follow-up results. *J Neurosurg* 1984;60:500-5.
 9. Jain VK, Mehrotra N, Sahu RN, Behari S, Banerji D, Chhabra DK. Surgery of vestibular schwannomas: An institutional experience, *Neurol india* 2005;53,41-5.
 10. Chen L, Chen LH, Ling F, Liu YS, Samii M, Samii A. Removal of vestibular schwannoma and facial nerve preservation using small suboccipital retrosigmoid craniotomy. *Chin Med J*, 2010;123:274-80.
 11. Darrouzet V, Martel J, Enée V, Bébéar JP, Guérin J. Vestibular schwannoma surgery outcomes: Our multidisciplinary experience in 400 cases over 17 years. *Laryngoscope* 2004;114:681-8.
 12. Jackler RK, Pitts LH, Acoustic neuromas. *Neurosurg Clin N Am* 1990;1:199-223.
 13. Yamakami I, Uchino Y, Kobayashi E, Yamaura A, Oka N. Removal of large acoustic neurinomas (vestibular schwannomas) by the retrosigmoid approach with no mortality and minimal morbidity. *J Neurol Neurosurg Psychiatry* 2004;75:453-8.
 14. Ebersold MJ, Harner SG, Beatty CW, Harper CM Jr, Quast LM. Current results of the retrosigmoid approach to acoustic neurinoma. *J Neurosurg* 1992;76:901-9.
 15. Roland JT Jr, Fishman AJ, Golfinos JG, Cohen N, Alexiades G, Jackman AH. Cranial nerve preservation in surgery for large Vestibular Schwannomas. *Skull Base* 2004;14:85-91.
 16. Lanman TH, Brackmann DE, Hitselberger WE, Subin B. Report of 190 consecutive cases of large acoustic Tumors (vestibular schwannoma) removed via the translabyrinthine approach. *J Neurosurg* 1999;90,617-23.

How to cite this article: Patibandla MR, Panigrahi MK, Gurram PL, Thotakura AK, Kulkarni D. Morphometric analysis of posterior fossa in Indian CP angle acoustic schwannoma patients. *Asian J Neurosurg* 2016;11:255-60.

Source of Support: Nil, Conflict of Interest: None declared.