

## CASE REPORT

# Spontaneous chronic subdural hematoma associated with arachnoid cyst in children and young adults

Rajendra Shrestha, Chao You

Department of Neurosurgery, West China Hospital, Sichuan University, Chengdu, PR China

## ABSTRACT

Arachnoid cysts are clear, colorless fluid-filled cysts that arise during brain and skull development from the splitting of the arachnoid membrane. Chronic subdural hematoma (CSDH) is an encapsulated collection of old blood, mostly or totally liquefied and located between the dura mater and the arachnoid mater. Trauma is an important factor in the development of CSDH. Here, we report four patients, previously asymptomatic, revealing CSDH with AC on computed tomography (CT) and magnetic resonance imaging (MRI) of the brain. All patients underwent craniotomy with evacuation of hematoma and resection of the cystic membrane that was then connected to the basal cistern under the operating microscope. Postoperatively, all patients were symptom-free. Presentation of an AC with chronic subdural hematoma in the absence of preceding head trauma is considered to be rare in children and young adults.

**Key words:** Arachnoid cyst, craniotomy, subdural hematoma

## Introduction

Arachnoid cysts (AC) are rare. They may develop anywhere in the subarachnoid space along the cerebrospinal axis. Their reported incidence accounts for only 1% of intracranial space occupying lesions. However, an apparent relative increase in frequency and a shift in age distribution towards the initial years of life have been described in recent years, reflecting the impact of the wide application of computed tomography (CT), magnetic resonance imaging (MRI). Trauma has been recognized as an important factor in the development of chronic subdural hematoma (CSDH).<sup>[1]</sup> We report four patients with SDH with AC; this is, to our knowledge, the largest series of spontaneous SDH with AC reported.

## Case Reports

### Patient 1

A 21-year-old gentleman presented with left temporal pain for 3 months. Initially his pain was stabbing in nature

associated with spasm of left cheek. It was not associated with vomiting, diplopia, visual hallucination, tinnitus and convulsions. However, it lasted only for four days and seemingly recovered after symptomatic treatment. However, the CT scan at the local hospital revealed a left temporal hyperdense lesion adjoining the left sylvian fissure - the left temporal AC. He visited our hospital for further management with complaints of recurrent headache. The neurological and physical examinations were normal. His medical and family histories were unremarkable. There was no history of trauma. The MRI demonstrated isohyperintense on T1-weighted images and hypo intense on T2-weighted images that suggested left temporoparietal subdural hematoma [Figure 1a]. A left temporal craniotomy was performed. Dura was intact with tension. When dura mater was opened, dark red blood about 20 ml was evacuated and AC was found in yellow, tough envelop. The arachnoid membrane was also excised carefully and sent for pathological examination. The postoperative course was uneventful. A postoperative CT showed obliteration of AC and subdural hematoma [Figure 1b]. The pathological examination and culture was negative for infection. The patient had a good recovery postoperatively.

### Patient 2

A 15-year-old boy presented to the hospital with a 2-month history of recurrent localized, left temporal throbbing headache requiring oral medication for amelioration and was referred to the hospital for further evaluation. There was no significant history of trauma. His vitals parameters were within normal limits with no neurological deficits. The result of the CT scan showed left frontal-temporal CSDH with AC.

### Access this article online

#### Quick Response Code:



#### Website:

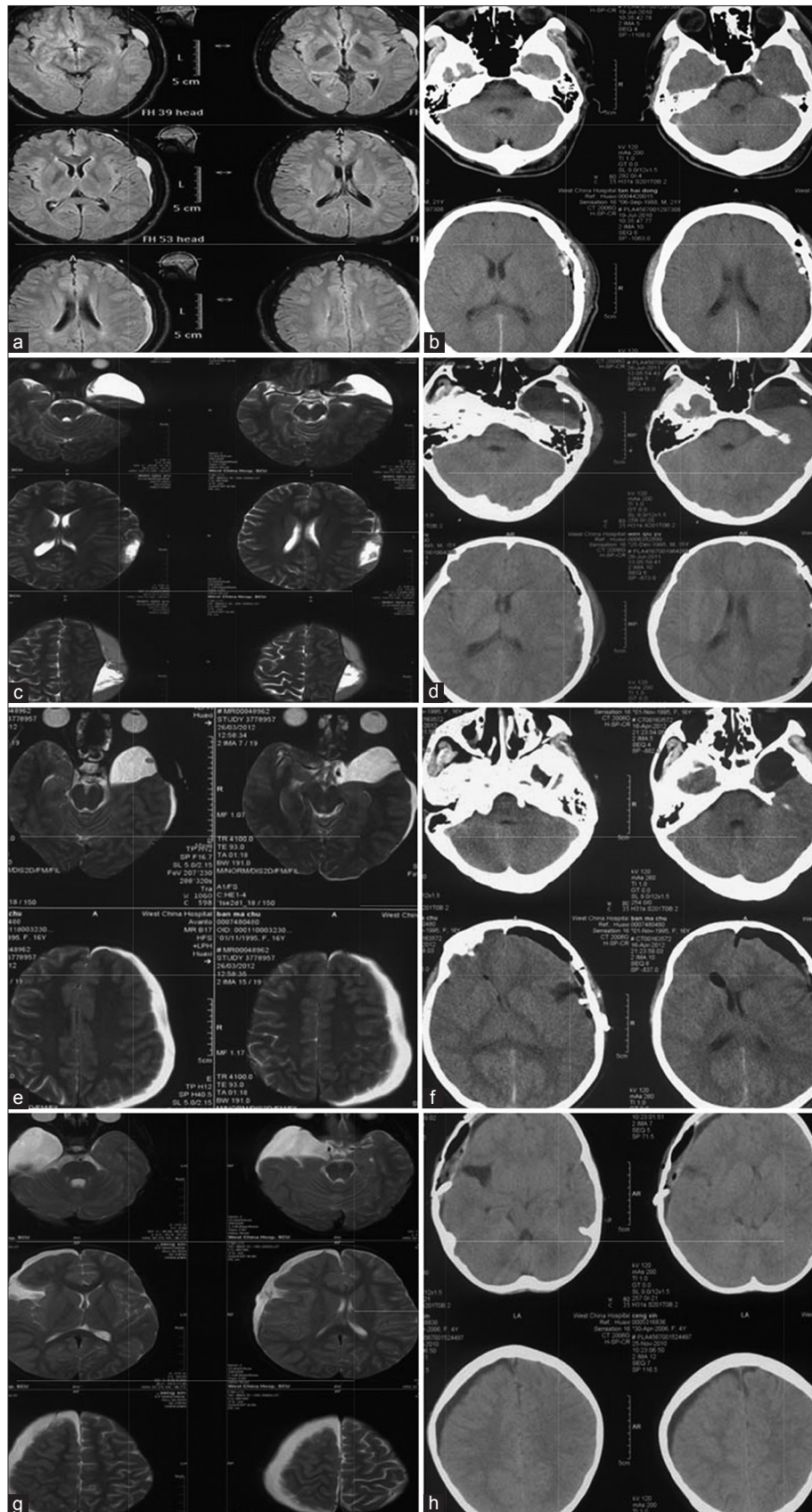
www.asianjns.org

#### DOI:

10.4103/1793-5482.142739

### Address for correspondence:

Prof. Chao You, Department of neurosurgery, West China Hospital, Sichuan University, Chengdu, 610041, PR China.  
E-mail: youchaowch@gmail.com



**Figure 1:** Magnetic resonance examination of brain (A, Patient 1; C, Patient 2; E, Patient 3 and G, Patient 4) showing chronic subdural hematoma and arachnoid cyst. And a postoperative computed tomography scan (B, Patient 1; D, Patient 2; F, Patient 3 and H, Patient 4) shows the absence of subdural hematoma and an arachnoid cyst

The MRI examination also showed low density signal in left frontal-temporal region [Figure 1c]. Workup for coagulopathy was negative. After hospitalization, SDH was evacuated and cystic membrane was resected using the operating microscope. Histopathological examination of the membrane resulted in the diagnosis of AC. Postoperative period was uneventful and the patient recovered completely [Figure 1d].

### Patient 3

A 16-year-old girl presented with headache and dizziness of 2-months duration. The headache had started insidiously, occurring four to five times a week initially. It was treated as migraine in a local hospital. During the last week, it had worsened, occurring several times a day and was associated with dizziness. It was aggravated during the change of posture. There was no history of head trauma. The neurological examination was normal. Blood profile was within normal limits. CT showed left frontotemporo CSDH with middle fossa AC. Magnetic resonance revealed hypointense in left frontotemporal region, suggestive of left middle fossa AC with fronto-temporo-parietal subdural effusion [Figure 1e]. The left temporal craniotomy was done; tense dura was opened to reveal yellowish hematoma and little clotted blood which was evacuated. There was neither any vascular malformation nor old fracture or tearing of dura. Postoperative period was uneventful [Figure 1f]. He was discharged with counseling to follow-up in the outpatient door.

### Patient 4

A 5-year-old girl was admitted with complaints of headache for 2 months. It was aggravated with vomiting for a week. Her condition had been deteriorating and so was referred to our Emergency for further management. Physical examination and neurological examination did not detect anything abnormal. MRI revealed right frontotemporo-SDH with AC [Figure 1g]. Her baseline investigations were normal. She underwent right frontotemporo craniotomy with evacuation of dark red-colored blood. Intraoperatively, there was xanthochromic fluid with normal brain surface. However, there was no evidence of any vascular malformations. AC membrane was resected and explored cistern under the operating microscope to flow CSF. The histopathology report was consistent with the AC. Postoperative CT scan was normal [Figure 1h].

## Discussion

ACs are benign; a congenital malformation characterized by clear cerebrospinal fluid (CSF) accumulation between the two layers of arachnoid membrane. ACs are nearly always sporadic and single- predominant in males with a two-third majority. The most frequent site is sylvian fissure (49%) followed by cerebellopontine angle (11%), supracollicular (10%), vermian (9%), Sellar and suprasellar (9%), interhemispheric (5%), cerebral convexity (4%) and clival (3%).<sup>[2]</sup> Galassi has classified Sylvian fissure cysts into three types according to the CT: Type I: Small, biconvex

is located in anterior temporal tip and communicates with subarachnoid space on water-soluble contrast CT cisternogram (WS-CTC) but no mass effect. Type II: Involves proximal and intermediate segments of sylvian fissure; completely open insula gives rectangular shape, partial communication on WS-CTC. Type III: Involves entire sylvian fissure, marked midline shift, bony expansion of middle fossa (elevation or lesser wing of sphenoid, outward expansion of squamous temporal bone) Minimal communication on WS-CTC.<sup>[2,3-5]</sup> Our all cases represent type I classification. CT and/or MR imaging are important tools in confirming the diagnosis.

The presentations of ACs are not very well known. Some of these cysts are quiescent throughout life, some remain dormant for many years before showing clinical manifestations, and some even disappear spontaneously.<sup>[1]</sup> Headache, epileptic seizures, psychomotor retardation, bobble-head doll syndrome, raised intracranial pressure, developmental delay, focal neurological deficit and deformity of the cranium with bulging and thinning of the adjacent bone are known symptoms of intracranial AC.<sup>[1,6-8]</sup> However, the commonest symptomatic presentation of patients with CSDH with an AC was headache (81%),<sup>[5]</sup> which was proven by our case too.

CSDH is commonly associated with cerebral atrophy. CSDH tends to occur in elderly patients with a history of mild head injury. It is a rare manifestation in children and young adults and also it is extremely rare without trauma. That made our cases quite interesting. Some authors mentioned that ACs are also recognized as cause of CSDH after head injury in young people and are considered a risk factor for chronic SDH in such population.<sup>[6]</sup> To our best knowledge, Wester *et al.*, the incidence of CSDH or intracystic hematomas were found as 4.6% of all patients with AC. Hiroyasu *et al.*, reviewed 72 patients SDH with AC reported in the literature. A trivial head injury was documented in 40 of the 72 cases but 12 cases had neither history of head injury nor recall of any traumatic event.<sup>[5]</sup> Parsch *et al.* and Page *et al.* reported 12 in 16 cases and seven cases of AC complicated with CSDH respectively.<sup>[7,9]</sup> All patients had a history of a previous head injury, whereas our cases did not. Although these AC lesions are considered congenital, the exact etiology is still not clear.<sup>[10]</sup> The theories currently accepted to explain the progressive enlargement of ACs postulate two principal mechanisms. AC may gradually increase in size, either due to CSF being driven in through a “ball-valve” like opening or by active secretion of fluid from the cyst wall.<sup>[4,11]</sup> Ultimately pressure inside the cyst will increase. An AC can even rupture spontaneously. Secondly, the cyst membrane is loosely attached to the convexity dura. The mechanical forces that are sustained during a moderate head trauma can cause the cyst membrane to be detached from the dura and thus cause a bleeding episode. Thirdly, the parietal cyst membrane also covers the area where the bridging sylvian veins, or the veins that traverse the membrane unsupported

**Table 1: Summary of SDH with arachnoids cyst in the literature**

| Cases | Authors           | Sex | Age | Symptom  | Location of AC and SDH     | Operation Outcome  | Outcome   |
|-------|-------------------|-----|-----|----------|----------------------------|--|-----------|
| 1.    | Kushida Y (1983)  | M   | 19  | Headache | Right                      | Cystectomy, Craniotomy                                     | Improved  |
| 2.    |                   | M   | 17  | Headache | Left                       | Cystectomy, Craniotomy                                     | -         |
| 3.    | Tajima K (1984)   | M   | 41  | Headache | Left                       | Cystectomy, Craniotomy                                     | -         |
| 4.    | Hara H (1984)     | M   | 13  | Headache | Right                      | Cystectomy, Craniotomy                                     | Improved  |
| 5.    | Page A (1987)     | F   | 23  | Headache | Right AC and Bilateral SDH | Cyst-Peritoneal Shunt, Burr Hole                           | Improved  |
| 6.    |                   | M   | 57  | Headache | Left AC and Bilateral SDH  | Cystectomy   | Unchanged |
| 7.    | Saito A (1987)    | M   | 42  | Headache | Left AC and Right SDH      | Cystectomy, Cyst-Peritoneal Shunt, Burr hole for right SDH | -         |
| 8.    | Endo G (1988)     | F   | 22  | Headache | Left                       | Cystectomy, Craniotomy                                     | Improved  |
| 9.    |                   | M   | 17  | Headache | Left                       | Cystectomy, Craniotomy                                     | Improved  |
| 10.   |                   | M   | 16  | Headache | Left                       | Cystectomy, Craniotomy                                     | Improved  |
| 11.   |                   | F   | 16  | Headache | Left                       | Burr Hole  | Improved  |
| 12.   |                   | F   | 7   | Headache | Left                       | Burr Hole  | Improved  |
| 13.   | Yokoyama K (1989) | M   | 17  | Headache | Right                      | Cystectomy, Craniotomy                                     | -         |
| 14.   | Sakai N (1992)    | F   | 6   | Headache | -                          | Cystectomy, Craniotomy                                     | Improved  |
| 15.   |                   | M   | 15  | Headache | -                          | None   | Improved  |
| 16.   | Maeda M (1993)    | M   | 14  | Headache | Left                       | Cystectomy, Craniotomy                                     |           |
| 17.   | Oka Y (1994)      | M   | 17  | Headache | Right                      | Burr Hole  | Improved  |
| 18.   |                   | M   | 24  | Headache | Right                      | Burr Hole  | Improved  |
| 19.   | Hiroyasu (1997)   | M   | 3   | Headache | Left                       | Cystectomy, Craniotomy                                     | Improved  |
| 20.   | Our case 1        | M   | 21  | Headache | Left                       | Cystectomy, Craniotomy                                     | Improved  |
| 21.   | Our case 2        | M   | 15  | Headache | Left                       | Cystectomy, Craniotomy                                     | Improved  |
| 22.   | Our case 3        | F   | 16  | Headache | Left                       | Cystectomy, Craniotomy                                     | Improved  |
| 23.   | Our case 4        | F   | 5   | Headache | Right                      | Cystectomy, Craniotomy                                     | Improved  |

by brain tissue, enter into the dural venous sinuses behind the sphenoid ridge. Even a moderate manipulation of the parietal membrane can disrupt these veins; leading to bleeding into subdural space.<sup>[8,10]</sup>

The most successful and universal treatment for a SDH patient is evacuation and irrigation with normal saline through burr holes. Galassi E *et al.* mentioned that membranectomy and cyst communication into the basal cisterns have good outcome in ACs of the middle cranial fossa.<sup>[2]</sup> Page *et al.* recommended craniotomy, membranectomy and hematoma drainage for middle fossa ACs complicated by CSDH.<sup>[9]</sup> Mori *et al.* performed drainage and irrigation through a burr hole on 12 CSDH with AC and reported satisfactory results. Cystoperitoneal shunting surgery after the drainage surgery can be used if the AC causes mass effect to the surrounding brain.<sup>[6]</sup> Cysto-peritoneal shunt can be recommended as the surgical treatment after evacuation of the haematoma.<sup>[12-15]</sup> Hiroyasu *et al.*, reported nineteen among 72 cases were only headache with a CSDH associated with an AC [Table 1]. Sixty-two percent of patients described in the literature had undergone craniotomy with combined evacuation of the CSDH and cystectomy of the AC.<sup>[5]</sup> Burr-hole evacuation of the CSDH alone was performed in 19% of cases. There are very few cases which reported conservative management<sup>[7]</sup> of CSDH associated with an AC in English literature. In our cases, two distinct clinical entities sporadically occurred in the same patient having significant headache. So, we performed craniotomy for evacuation of

SDH. And also cystic membrane were resected and made communication in the basal cistern to prevent recurrent in all cases. The patients in our cases were young and showed no evidence of head injury. Therefore, we conclude that SDH with AC in our patient were, indeed, spontaneous. We must follow-up to identify the cause of spontaneous SDH with angiography.

## Conclusions

CSDH is one of the complications of an AC, either spontaneous or post traumatic. Hematoma can develop on either side of AC. However, spontaneous SDH with AC presented with mass effect or severe intractable headache, craniotomy is the treatment of choice over burr-hole evacuation. Long clinical and radiological follow-up are indispensable despite satisfactory surgical resection.

## References

1. Robinson RG. Congenital cysts of the brain: Arachnoid malformations. *Progr Neurosurg* 1971; 4:133-74.
2. Greenberg MS. *Handbook of Neurosurgery*. 7<sup>th</sup> ed. 2010. p. 222.
3. Galassi E, Tognetti F, Gaist G, Fagioli L, Frank F, Frank G. CT scan and metrizamide CT cisternography in arachnoid cysts of middle cranial fossa: Classification and pathophysiological aspect. *Surg Neurol* 1982;17:363-9.
4. Go, KG. Pathogenesis of arachnoid cysts in relation to the mechanism of cerebrospinal fluid absorption. In: Raimondi AJ, Choux M, Di Rocco C, editor. *Intracranial Cyst Lesions*. New York: Springer-Verlag; 1993. p. 79-86.

5. Yamakawa H, Sakai H, Nishimura Y, Okumura A, Sawafuji M, Sakai N, *et al.* Intracranial arachnoid cyst with subdural hematoma. *J Clin Neurosci* 1997;4:493-8.
6. Mori K, Yamamoto T, Horinaka N, Maeda M. Arachnoid cyst is a risk factor for chronic subdural hematoma in juveniles: Twelve cases of chronic subdural hematoma associated with arachnoid cyst. *J Neurotrauma* 2002;19:1017-27.
7. Parsch CS, Krauss J, Hofmann E, Meixensberger J, Roosen K. Arachnoid cysts associated with subdural hematomas and hygromas: Analysis of 16 cases, longterm follow-up, and review of the literature. *Neurosurgery* 1997;40:483-90.
8. ShresthaRajendra, PradhanReeka, JianguoXu, Chao You. Arachnoid cyst complicated by spontaneous Chronic Subdural Hematoma in the infant. *Romanian Neurosurgery* 2012;XIX 1.
9. Page A, Paxton RM, Mohan D. A reappraisal of the relationship between arachnoid cyst of the middle fossa and chronic subdural hematoma. *J Neurol Neurosurg Psychiatry* 1987;50:1001-7.
10. Wester K, Helland CA. How often do chronic extra-cerebralhaematomas occur in patients with intracranial arachnoid cysts? *J Neurol Neurosurg Psychiatry* 2008;79:72-5. Epub 2007 May 8.
11. Smith RA, Smith W A. Arachnoid cysts of the middle cranial fossa. *Surg. Neurol* 1976;5:246-52.
12. Rogers MA, Klug GL, Siu KH. Middle fossa arachnoid cysts in association with subdural haematomas. A review and recommendations for management. *Br J Neurosurg* 1990;4:497-502.
13. Adhiyaman V, Asghar M, Ganeshram KN, Bhowmick BK. Chronic subdural haematoma in the elderly. *Postgrad Med J* 2002;78:71-5.
14. Galassi E, Piazza G, Gaist G, Frank F. Arachnoid cysts of the middle cranial fossa: A clinical and radiological study of 25 cases treated surgically. *SurgNeurol* 1980;14:211-9.
15. Pillai P, Menon SK, Manjooran RP, Kariyattil R, Pillai AB, Panikar D. Temporal fossa arachnoid cyst presenting with bilateral subdural hematoma following trauma: Two case reports. *J Med Case Rep* 2009;3:53.

**How to cite this article:** Shrestha R, You C. Spontaneous chronic subdural hematoma associated with arachnoid cyst in children and young adults. *Asian J Neurosurg* 2014;9:168-72.

**Source of Support:** Nil, **Conflict of Interest:** None declared.

## New features on the journal's website

### Optimized content for mobile and hand-held devices

HTML pages have been optimized of mobile and other hand-held devices (such as iPad, Kindle, iPod) for faster browsing speed.

Click on [**Mobile Full text**] from Table of Contents page.

This is simple HTML version for faster download on mobiles (if viewed on desktop, it will be automatically redirected to full HTML version)

### E-Pub for hand-held devices

EPUB is an open e-book standard recommended by The International Digital Publishing Forum which is designed for reflowable content i.e. the text display can be optimized for a particular display device.


Click on [**EPub**] from Table of Contents page.

There are various e-Pub readers such as for Windows: Digital Editions, OS X: Calibre/Bookworm, iPhone/iPod Touch/iPad: Stanza, and Linux: Calibre/Bookworm.

### E-Book for desktop

One can also see the entire issue as printed here in a 'flip book' version on desktops.

Links are available from Current Issue as well as Archives pages.

Click on  View as eBook