Article published online: 2022-09-22

ORIGINAL ARTICLE

EC-IC bypass for cavernous carotid aneurysms: An initial experience with twelve patients

G. Menon, Sudhir Jayanand, K. Krishnakumar, S. Nair
Department of Neurosurgery, Sree Chitra Tirunal Institute for Medical Sciences and Technology, Trivandrum, India

ABSTRACT

Aims: Need for performing a bypass procedure prior to parent artery occlusion in patients with good cerebral vascular reserve is controversial. We analyze our experience of 12 giant internal carotid artery aneurysms treated with extracranial-intracranial (EC-IC) bypass and proximal artery occlusion.

Materials and Methods: Retrospective analysis of the case records of all complex carotid aneurysms operated in our institute since January 2009.

Results: The study included eleven cavernous carotid aneurysms and one large fusiform cervical carotid aneurysm reaching the skull base. Preoperative assessment of cerebral vascular reserve was limited to Balloon test occlusion with hypotensive challenge. Eleven patients who successfully completed a Balloon test occlusion (BTO) underwent low flow superficial temporal artery to middle cerebral artery (STA-MCA) bypass, while one patient with a failed BTO underwent a high flow bypass using a saphenous vein graft. Parent artery ligation was performed in all patients following the bypass procedure. Check angiogram revealed thrombosis of the aneurysm in all patients with a graft patency rate of 81.8%. We had one operative mortality, probably related to a leak from the anastomotic site. The only patient who had a high flow bypass developed contralateral hemispheric infarcts and remained vegetative. All the other patients had a good recovery and with a Glasgow outcome score of 5 at last follow-up.

Conclusion: We feel that combining EC-IC bypass prior to parent vessel occlusion helps in reducing the risk of post operative ischemic complications especially in situations where a complete mandated cerebral blood flow studies are not feasible.

Key words: Aneurysms, bypass surgery, clipping, coiling, revascularization

Introduction

Management of certain complex carotid aneurysms pose considerable surgical challenge. Exclusion of aneurysm from the circulation, in such patients, quite often involves either trapping of the aneurysmal segment or parent vessel occlusion. In such situations, cerebral revascularization through extracranial to intracranial (EC-IC) bypass is required prior to parent vessel occlusion to prevent ischemic complications.[1,2] The selection of patients for EC-IC bypass is controversial. Proponents of the "universal bypass" policy advocate bypass for all patients while the others recommend bypass only for patients with poor cerebrovascular reserve. This article describes the author's and initial experience with 12 cases of EC-IC bypass procedures for large or giant intracranial internal carotid artery (ICA) aneurysms that were not amenable to either direct clipping or endovascular coiling. The overall outcome and management issues are discussed under the light of the relevant literature.

Access this article online	
Quick Response Code:	Website: www.asianjns.org
	DOI: 10.4103/1793-5482.136718

Address for correspondence:
Dr. G. Menon, Department of Neurosurgery, SCTIMST, Trivandrum - 695 011, India. E-mail: gmr@sctimst.ac.in

Materials and Methods

Since January 2009, 12 cases of revascularization were performed in our center for the treatment of complex internal carotid artery aneurysms. These aneurysms were considered unsuitable for either surgical clipping or endovascular coiling due to various reasons like wide neck, fusi-saccular configuration, giant size, intramural thrombus, cavernous sinus location, and transitional variants (cavernous with supraclinoid). [Table 1] presents the summary demographic data of these 12 patients.

Selection of patients

All patients underwent magnetic resonance imaging (MRI), computed tomographic (CT) scanning of the brain, CT

Table 1: Clinical summary of the twelve patients in the current series

Age and sex	Presenting symptom	Clinical deficits	Site and size of aneurysm	Balloon test occlusion with hypotension	Procedure	Clinical/cranial nerve outcome	Graft patency	Aneurysm status
60 F	Headache, diplopia	LR palsy	Cavernous 3.1×2.4×1.5	Passed	STMC and ICA ligation	No change	Good	Thrombosed
67 F	Ptosis, diplopia	3rd nerve palsy	Transitiional 2.7×2.5×1.5	Not passed	EC-IC high flow using SVG	Vegetative	Good	Thrombosed
24 F	Headache, diplopia, ptosis	Partial 3rd	Cavernous 1.9×1.6×1.9	Passed	STMC and ICA ligation	Partial recovery of ptosis	Poor	Thrombosed
43 F	Ptosis, diplopia, headache	Total opthalmoplegia	Cavernous 2.1×.2.1×1.9	Passed	STMC and ICA ligation	Expired		
45 F	Headache, ptosis, diplopia	Ophthalmoplegia	Transitional 2.7×3.7×2.6	Passed	STMC and AwaitingICA ligation	No change	Good	Awaiting ligation if the caroid dissection recanalises
52 M	Diplopia, headache	Partial 3rd nerve palsy	Cavernous 2.1×1.9×3.2	Passed	STMC and ICA ligation	3rd nerve paresis recoveredt	Good	Thrombosed
48 F	Diplopia	Lateral rectus palsy	Cavernous 2.1× .1.8×1.8	Passes after bypass	STMC and ICA ligation	Partial recovery	Good	Thrombosed
58 F	Periorbital pain, diplopia	Lateral rectus, partial 3rd	Cavernous 2.5×2×2.3	Passed	STMC and ICA ligation	No recovery	Poor	Thrombosed
51 F	Diplopia	3rd nerve paresis	Cavernous 3×3×2.9	Passed	STMC and ICA ligation	3rd nerve paresis improved	Good	Thrombosed
50 F	Headache, diplopia	3rd nerve paresis	Transitional 3.9×3.5×2.4	Passed	STMC and ICA ligation	3rnd nerve paresis improved	Good	Thrombosed
21 M	Swelling left side of neck and within tonsillar fossa	No deficits	Fusiform left cervical aneurysm from carotid bulb to carotid canal, 3 cm wide	Passed	STMC and ICA ligation	No deficits	Good	Thrombosed
30 M	Diplopia, facial pain	Right abducens palsy	Giant cavernous aneurysm	Passed	STMC and ICA ligation	No deficits	Good	Thrombosed

STMC – Superficial temporal middle cerebral; ICA – Internal carotid artery

angiography (CTA) followed by digital subtraction cerebral angiography (DSA) with cross compression studies. Patients having good cross circulation through anterior communicating artery or posterior communicating artery were subjected to balloon test occlusion (BTO) with hypotensive challenge. BTO was performed initially for 15 minutes at normal blood pressure and those patients who tolerated BTO were subjected to hypotensive challenge. The balloon was deflated if the patient tolerated ICA occlusion after hypotensive challenge or developed a gross neurological deficit during 20 minutes of parent vessel occlusion. Low-flow augmentative bypass (ST-MC) was used in patients with good cross circulation who tolerated balloon occlusion with hypotensive challenge. High flow bypass (using saphenous vein graft) was used in patients with poor cross circulation and for those who did not tolerate BTO. The aneurysm was thereafter excluded from circulation by parent vessel (ICA) ligation alone and none of the patients underwent trapping of the aneurismal segment.

Results

The study included 9 female and 3 male patients. Their age ranged from 21 to 67 years (mean 45.83 years). Follow-up periods ranged 3 months to 2 years (mean 15 months). The study included 11 cavernous carotid aneurysms and one large fusiform cervical carotid aneurysm reaching the skull base. [Table 1]. All the patients with cavernous aneurysms presented with features of cranial nerve paresis, 3rd nerve and 6th nerve being the most commonly affected [Table 1]. All these patients also gave history of chronic headache, facial pain or periorbital pain. Eleven patients, who tolerated the BTO well, underwent low flow bypass using an end-to-side superficial temporal artery to middle cerebral artery (STA-MCA) bypass, and one patient who failed the BTO underwent a high flow bypass using a saphenous vein graft. All patients underwent permanent ICA occlusion as a second stage procedure. We could not perform SPECT, PET or other cerebral blood flow/cereberovascular reserve studies in any of our patients and the management decision was entirely based on BTO studies.

Check angiogram revealed thrombosis of the aneurysm in all the nine cases where parent artery ligation was carried out. Graft patency was observed on check angiograms (DSA or CTA) in 9 patients [Figures 1 and 2]. Graft patency was absent in two patients, both operated in the initial part of the series. In these two patients, parent ligation was nevertheless

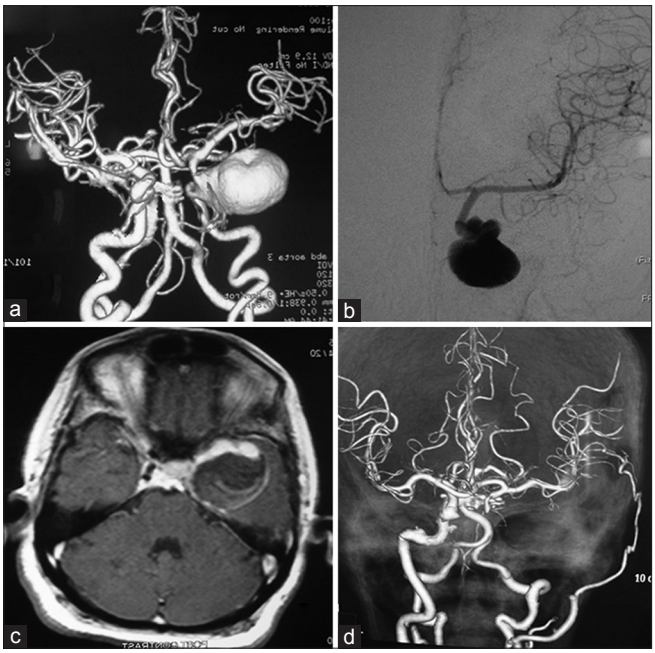

Figure 1: (a and b) CT angiogram and 4 vessel DSA showing a giant cavernous aneurysm on the left side. (c) MRI brain T1 weighted contrast sequence suggestive of intramural thrombus. (d) Post operative CT angiogram showing non filling of the aneurysm and a patent STMC anastomosis

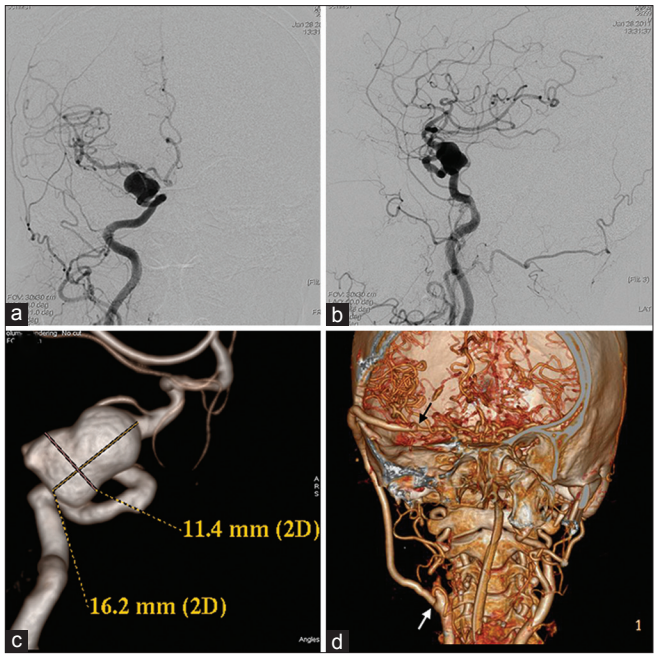

Figure 2: (a-c) DSA images of a right transitional aneurysm (cavernous and supraclinoid) of the internal carotid artery. (d) CTAngioram (post operative) showing a patent high flow saphenous vein graft from the cervical ICA to middle cerebral artery. The ICA stump and the non filling of the aneurysm are also visible

carried out inspite of an absent flow through the graft as the patients were found to have good collaterals and adequate cerebrovascular reserve on balloon occlusion studies. In two patients, imaging evidence of diffusion restriction was seen following bypass surgery, but both these patients did not develop any corresponding clinical deficits.

We had one operative mortality. This patient had undergone a STMC bypass for a giant cavernous IC aneurysm. She recovered well from surgery and the first CT scan done within 24 hours was normal. However, one day after surgery, she suddenly deteriorated in sensorium, and became unresponsive. An urgent CT scan done after intubation showed a thin subdural clot with a full brain. Inspite of all supportive measures, she rapidly deteriorated and succumbed. The cause of death was not evident as autopsy could not be performed. We presume that a leak from the anastomotic site could have resulted in the subdural hematoma and malignant cerebral edema. The only patient who underwent high flow by pass using a saphenous vein graft too had a stormy post operative course. She developed a contralateral ICA infarct with associated deficits and was discharged in a vegetative state. All the other patients had a good recovery and were in good neurological grade with a Glasgow outcome score of 5 at last follow-up.

Discussion

The credit for the first intracranial EC-IC bypass surgery goes to Donaghy and Yasargil in 1967.[1,3] EC-IC bypass technique was first used in the treatment of ischemic stroke. The initial reports of the international randomized trial on EC-IC bypass for preventing ischemic stroke were however disappointing.[4] Bypass surgery is currently gaining ground as an effective alternative in the management of complex and difficult intracranial aneurysm,[5-8] especially in situations where the parent artery sacrifice is required and recent clinical publications[9-14] have indicated a strong rationale for reexamining the bypass procedures. Recent evidence suggests a revival of EC- IC bypass surgery especially for the management of unclippable complex aneurysm and cranial base tumors involving major cranial arteries.[5-7,15-21]

Natural history of giant cavernous segment aneurysms and the rationale for intervention

Carotid cavernous aneurysms (CCA) represent approximately 3 to 5% of all intracranial aneurysms and 15% of those arising in the internal carotid artery (ICA).[20-22] Cavernous aneurysms can arise from any segment of cavernous carotid but most commonly originate in the horizontal segment. Pure cavernous segment aneurysms, being extradural seldom present with subarachnoid hemorrhage and they commonly present with symptoms related to their large size, intramural thrombus and subsequent neurovascular compression. Thus, diplopia and ophthalmoparesis are the most common presenting features coupled with retroorbital pain, headache, or facial pain. The transitional forms of cavernous aneurysms have an intradural component and carry a risk of subarachnoid hemorrhage. The natural history of these aneurysms is not well known.[23-25] Although a few cases of spontaneous thrombosis have been

reported, they are best treated for they definitely carry a risk of life threatening hemorrhage, thromboembolism and cranial nerve palsies.[21,25] Surgical treatment of giant unruptured cavernous aneurysms carries a high rate of mortality and morbidity which can be as high as 4% and 19%, respectively.[21] Technical refinements like bypass surgery help to reduce this effectively as shown in Kims series, where the mortality and morbidity rates are 0% and 20%, respectively.[16]

Assessment of cerebrovascular reserve to determine the indications for bypass surgery

In patients with giant ICA aneurysms, standard clipping procedures are often unsuitable and the majority of reported cases were managed by carotid ligation procedures[26] which carry a risk of morbidity and mortality between 10% and 20%.[27] It is therefore important to evaluate the risk of infarction from carotid occlusion before permanent ICA sacrifice and management essentially depends on the adequacy of collateral cerebral circulation.

Many techniques have been developed to evaluate cerebrovascular reserve, of which BTO is the most commonly used one. Attempts to assess the risk of ischemic complications following ICA ligation was first done by Matas in 1911 through manual carotid compression. Matas test has shortcomings in that it detects only the most catastrophic degree of inadequate collateral circulation and this test proved to be unreliable. Cross compression angiography and presence of good collaterals are a good predictor but again not a reliable tool as they do not simulate a real time ICA occlusion scenario. The introduction of BTO has reduced the risk of stroke and death after carotid ligation which used to be approximately 25% and 12%, respectively.[22-24,28,29] However, a significant percentage of patients with acceptable BTO results still develop infarction.[28,30] Other techniques used in combination with BTO include quantitative CBF analysis using SPECT, ocular plethysmography, somatosensory-evoked potentials, xenon-enhanced computed tomography, and PET.[31-33] The addition of physiologic stressors (eg, induced hypotension and acetazolamide injection) aids in the identification of patients with compromised cerebrovascular reserves.[34,35] If there is evidence of insufficient cerebral reserve, an extracranial-intracranial bypass is performed followed by either surgical trapping or endovascular ICA coil occlusion. If there is evidence of adequate cerebral collateral flow, carotid occlusion without bypass may be performed. Heros *et al*. advocate monitoring the carotid stump pressure prior to carotid occlusion to decide on the treatment strategy.[31] If the mean stump pressure decreases by 30 to 70% of the mean preclamping pressure and electroencephalograms do not change during the 15 minutes of temporary CCA occlusion, the patient is a good candidate for permanent ICA occlusion. If stump pressure decreases by more than 70% with CCA occlusion, the risk of ischemia is high, and the patient should be considered for an EC-IC bypass before trapping. Moreover, if the pressure does not decrease by more than 30%, chance of aneurysm thrombosis is low and the aneurysm needs to be trapped either surgically or endovascularly. However, it is well documented that none of these tests are fool proof and 5% of patients with good cross circulation carry a risk of ischemia after carotid occlusion.

Uncertainty of Balloon test occlusion and the need for bypass in patients with good cross circulation and collateral reserve

BTO alone or in combination with other cerebral blood flow studies are now considered standard of care in the preoperative assessment of patients warranting ICA ligation. Previous series have reported the stroke rate of 10-12% after permanent ICA occlusion based on clinically tolerated BTO, which is significantly lesser than the 32-60% risk of complications associated with carotid ligation done without any preoperative assessment.[36,37] The sensitivity of BTO can be increased by combining it with cerebral blood flow studies like SPECT, PET and xenon enhanced CT and stump pressure measurements. Although xenon enhanced CBF studies are reported to reduce the risk of ischemic complications from 13% to 10%, xenon CT studies are insensitive to vascular border zone in deep white matter and cerebral cortex. ICA occluded 99 Technetium HMPAO SPECT relies on development of cerebral blood flow asymmetry and is very sensitive, but baseline asymmetries may be overlooked. Contrast enhances MR imaging following TBO has been found to show clinically silent ischemic areas in 27% of patients having a negative BTO. These patients are theoretically at risk of permanent ischemic sequelae following ICA ligation.[36]

The predictive value of a negative test occlusion was 94% for all methods of ICA occlusion and failure during BTO indicates gross inadequacy of collaterals and higher risk of infarction even with temporary occlusion. Reported false-negative rates, however, may be as high as 15%, primarily as the result of delayed hemodynamic complications. Passing BTO and showing a relative decrease in cerebral perfusion on flow studies indicate that the patient is at some risk of having flow related infarction. However, passing BTO with flow studies does not rule out the chance of infarction which can still be as high as 20-22% rate of infarction.[37,38]

Segal *et al*. after analyzing their series and those in published literature conclude that failure of BTO can identify those patients at increased risk for stroke after carotid ligation.[37,38] However, a normal BTO and cerebral blood flow studies does not indicate that carotid ligation can be performed safely. Prohylactic revascularization surgeries help to prevent the uncertainties of ischemic complications in spite of a positive BTO. A variety of revascularization procedures are available none of them are without risk. Graft occlusion is the most common complication with patency rates reported from 66 to 95%. Most of the causes of graft occlusion are technical

and majority of them can be avoided by practicing meticulous techniques.

The role of cerebral vascularization together with proximal vessel occlusion is controversial, especially in patients with good cross circulation. Kuratsu *et al*. have evolved a treatment strategy of bypass selection based on BTO and SPECT.[32] Patients with BTO evidence of profound ischemia undergo a high-flow venous bypass graft before ICA sacrifice. Patients without ischemic symptoms during BTO, but having at-rest SPECT evidence of hypoperfusion in the ipsilateral hemisphere undergo a medium-flow bypass. Patients without ischemic symptoms during BTO, normal at-rest SPECT results but having hypo-vasoreactivity of the ipsilateral hemisphere under acetazolamide stress, undergo low-flow (STA-MCA) bypass. Only patients who tolerate BTO and manifest no hypoperfusion on at-rest and acetazolamide-stressed SPECT study during ICA occlusion were considered candidates for direct ICA occlusion by Kuratsu. Available literature is divided on this issue and some authors recommend revascularization bypass procedures for all patients (the universal approach).[7,20] Yet another group advocate high flow bypass in all patients to ensure maximum safety.

Ten of our twelve patients had a good outcome, one expired and one had a vegetative outcome. Graft patency was observed in ten patients and two patients did well in spite of an occluded graft. Our data does not effectively prove the necessity of a graft, but it does not disprove it either. These surgeries can be considered as relatively safe procedures which probably provide an added safety against ischemic events and over the years we have adopted the universal principle – a bypass in all cases of ICA sacrifice. The absence of PET, SPECT, and other advanced techniques for cerebral blood flow assessment in our institute has also partially influenced this decision. Our institute policy is essentially based on Balloon test occlusion with hypotensive challenge. Patients with good collateral circulation and not showing neurological change on test occlusion undergo augmentative low-flow bypass, whereas in patients with poor cross circulation, we perform a high flow bypass. STA-MCA anastomosis was the most commonly performed procedure in our series. ST MC is considered as low volume bypass since both donor and recipient arteries have a small diameter and the flow rate is limited to <50 ml/min. This type of bypass is commonly used for an area where large volumes of blood are not necessary, and we generally perform it to one of the cortical M4 branches. For high flow bypass, we prefer the use of saphenous vein graft due to the ease in harvesting and a lower risk of vasospasm. The choice of conduit for the bypass is optional between a saphenous vein graft (SVG) and a radial artery graft (RAG). The advantages of SVG include easy access, availability of longer lengths of harvestable conduit and low risk of vasospasm. RAG has the advantage of higher patency rate but also carry the risk of early spasm causing graft occlusion, intimal hyperplasia causing graft failure. Use of calcium channel blockers and pressure distension techniques help to reduce these complications.

Carotid ligation alone or carotid ligation with trapping of ICA distal to the aneurysm

Carotid ligation tends to be most effective for aneurysms of the petrous and cavernous carotid segments and most intracavernous aneurysms treated by proximal occlusion get thrombosed slowly over several months. The efficacy of carotid ligation for induction of aneurysm thrombosis is inversely proportional to the degree of collateral circulation.[31,39] The more proximal an aneurysm is located along the ICA, the less potential for retrograde flow and the higher the likelihood of successful treatment with carotid ligation alone.[31,39] However, in some patients of cavernous aneurysms and most patients with supraclinoid segment aneurysms including paraclinoid aneurysms, the chance of inducing thrombosis decreases as there is retrograde flow to the aneurysm from the ophthalmic artery and posterior communicating artery after ICA ligation. In these cases, proximal occlusion may not produce complete thrombosis of the aneurysm and also there is a risk of microemboli from the intra-aneurysmal thrombus to the distal ICA.[40] These patients require trapping of the aneurysmal segment by placing a clip just distal to the aneurysm. Heros *et al*. advocate monitoring the carotid stump pressure prior to carotid occlusion to decide on the treatment strategy.[31] If pressure did not decrease by more than 30%, the chance of aneurysm thrombosis tends to be low, and the aneurysm needs to be trapped either surgically or endovascularly. All our patients were managed with carotid ligation alone and the post operative angiogram revealed nonfilling of the aneurysm.

Internal carotid artery ligation vs common carotid artery ligation

Both procedures have been associated with a similar incidence of aneurysmal thrombosis, size reduction,[41-44] and rebleeding rates.[41,44-47] Although ICA ligation has been considered more effective than CCA ligation for inducing intra aneurysmal thrombosis,[48-50] the rate of ischemic complications has been reported to be significantly higher with ICA ligation compared with CCA ligation.[45,47,49,51] As we advocate a STMC anastomosis for all patients, irrespective of their collateral circulation, proximal clamping was restricted to ICA occlusion in our series.

Timing of parent vessel ligation

Hunterian ligation or balloon occlusion of the proximal vessel is based on the concept that diminished intralesional pressure promotes thrombosis.[27] However, the timing of IC ligation following the bypass procedure varies from center to center. While some surgeons prefer to do a check angiogram and balloon test occlusion prior to parent vessel ligation, others prefer to ligate the IC in the same sitting to facilitate graft patency. Our current practice is to ligate the IC in the same sitting provided the flow through the graft appears satisfactory, both clinically and on Doppler studies.

Clinical and radiological outcome

Most series report clinical improvement of presenting symptoms as well as radiological obliteration of the aneurysm in all surviving patients, regardless of the method of treatment. Moreover, Kuratsu *et al*. suggest that early treatment is important in patients with giant aneurysms in the cavernous portion of the ICA and treatment should be delivered within 3 months of symptom onset to facilitate complete recovery of cranial nerve deficits. Our experience too is similar; and angiogram checks revealed thrombosis of the aneurysm in all the 11 cases where parent artery ligation was carried out. Improvement of pre-treatment symptoms was noted in 9 of the 11 patients. The only patient who underwent high flow by pass using a saphenous vein graft too had a stormy post operative course. She developed a contralateral ICA infarct with associated deficits and was discharged in a vegetative state. All the other patients had a good recovery and were in Glasgow outcome score of 5 at last follow-up.

Complications and their avoidance

STA-MCA bypasses has its own share of complications the major ones being graft occlusion, subgaleal hematoma, scalp necrosis, and post-operative intracranial hemorrhage.[52] Graft occlusion can be prevented by meticulous dissection of both the donor and recipient artery with minimal handling of the endothelium. Most of our patients developed scalp problems, which literature suggests, can be prevented by limited lateral dissection of the STA and adequate hemostasis. We feel that the plane of dissection while harvesting the ST branches is very important. A superficial dissection just beneath the subcutaneous plane has a higher incidence of complications. The exact plane of superficial temporal artery should be identified and dissection should be carried out in that plane. Limited cortical dissection and preservation of veins have been said to prevent or decrease intracranial hemorrhage. Other major complications are due to occlusion of the major vessels and include cerebral ischemia and infarction.[53] Pre- and postoperative use of antiplatelet agents and anticoagulants may help to reduce thrombosis related problems. However, the intraoperative use of heparin may cause coagulopathy. Our present practice is to start anti-platelets preoperatively and continue them for at least one year. Intraoperative use of heparin is limited to high flow anastomosis and we routinely do not use heparin/anticoagulants for low flow anastomosis. During high-flow bypass procedures, 4000 to 5000 units of heparin is administered intravenously. Although the two patients in our series had imaging evidence of diffusion restriction following surgery, none of these patients developed any fresh deficits following surgery. The risk of ischemia in the donor artery territory is related to the clamp time, which is directly related to the learning curve. The risk of this complication is not high and can be reduced by the use of cerebral protection during clamp time. Brain protection provided using propofol or pentobarbital helps to protect the brain during temporary arterial occlusion for bypass but care must be taken to avoid hypotension during such burst suppression. The blood pressure is elevated 20% above the normal value in patients with unruptured aneurysms but maintained at normal in patients with ruptured aneurysms. These maneuvers reduce brain metabolism and increase collateral blood flow and greatly reduce or eliminate ischemic damage from the temporary vascular occlusion. Attempts to reduce clamp time at the expense of a meticulous anastomosis are to be avoided.

Conclusion

The natural history of large/giant cavernous carotid aneurysms is not well known, but current evidence recommends early occlusion of the aneurysm from circulation. Assessment of cerebro vascular reserve helps in identifying appropriate surgical strategy. Proximal carotid artery occlusion alone will suffice in carefully selected patients and trapping is often not required to induce thrombosis of the aneurysm. In patients in whom a complete mandated workup for cerebrovascular reserve is not feasible, combining cerebral revascularization through EC-IC bypass with parent vessel occlusion probably helps in reducing the risk of post operative ischemic complications.

References

1. Park EK, Ahn JS, Kwon do H, Kwun BD. Result of extracranial-intracranial bypass surgery in the treatment of complex intracranial aneurysms: Outcomes in 15 cases. J Korean Neurosurg Soc 2008;44:228-33.
2. Sanuş GZ, Akar Z, Tanriverdi T, Tütüncüler B, Uzan M, Işlak C, *et al*. Bypass to the Intracranial Giant or Large Internal Carotid Artery Aneurysms: Superficial Temporal Artery to Middle Cerebral Artery Bypass Re-visited. Turk Neurosurg 2007;17:60-5.
3. Donaghy R, Yasargil MG. Microvascular Surgery. St Louis: CV Mosby; 1967.
4. EC/IC Bypass Study Group. Failure of extracranial-intracranial arterial bypass to reduce the risk of ischemic stroke: Results of an international randomized trial. N Engl J Med 1985;313:1191-200.
5. Evans JJ, Sekhar LN, Rak R, Stimac D. Bypass grafting and revascularization in the management of posterior circulation aneurysms. Neurosurgery 2004;55:1036-49.
6. Sekhar LN, Bucur SD, Bank WO, Wright DC. Venous and arterial bypass grafts for difficult tumors, aneurysms, and occlusive vascular lesions: Evolution of surgical treatment and improved graft results. Neurosurgery 1999;44:1207-23.
7. Sekhar LN, Duff JM, Kalavakonda C, Olding M. Cerebral revascularization using radial artery grafts for the treatment of complex intracranial aneurysms: Techniques and outcomes for 17 patients. Neurosurgery 2001;49:646-58.
8. Sundt TM Jr, Piepgras DG, Marah WR, Fode NC. Saphenous vein bypass grafts for giant aneurysms and intracranial occlusive disease. J Neurosurg 1986;65:439-50.
9. Hacein-Bey L, Connolly Es Jr, Doung H, Vang MC, Lazar RM, Marshall RS, *et al*. Treatment of inoperable carotid aneurysms with endovascular carotid occlusion after extracranial-intracranial bypass surgery. Neurosurgery 1997;41:1225-34.
10. Ishikawa I, Kamiyama H, Kobayashi N, Tanikawa N, Takizawa K, Kazumata K. Experience from "double-insurance bypass." Surgical results and additional techniques to achievecomplex aneurysm surgery in a safer manner. Surg Neurol 2005;63:485-90.

11. Jafar JJ, Russell SM, Woo HH. Treatment of giant intracranial aneurysms with saphenous vein extracranial-to-intracranial bypasses grafting: Indications, operative technique, and results in 29 patients. Neurosurgery 2002;51:138-46.
12. Morgan MK, Ferch RD, Little NS, Harrington TJ. Bypass to the intracranial internal carotid artery. J Clin Neurosci 2002;9:418-24.
13. Yeh HS, Tomsick TA. Obliteration of a giant carotid aneurysm after extracranial-to-intracranial bypass surgery: Case report. Surg Neurol 1997;48:473-6.
14. Zhang YJ, Barrow DL, Day AL. Extracranial-intracranial vein graft bypass for giant intracranial aneurysm surgery for pediatric patients: Two technical case reports. Neurosurgery 2002;50:663-8.
15. Kang SD. Extracranial-intracranial bypass surgery: Surgical technique and perioperative management. Kor J Cerebrovasc Dis 2002;4:119-23.
16. Kim DS, Kim JK, Yoo DS, Huh PW, Cho KS, Kim MC. Current indication of extracranial-intracranial bypass surgery. Kor J Cerebrovasc Dis 2002;4:99-103.
17. Lawton MT, Hamilton MG, Morcos JJ, Spetzler RF. Revascularization and aneurysm surgery: Current techniques, indications, and outcome. Neurosurgery 1996;38:83-92. discussion 92-94.
18. Peerless SJ, Hampf CR. Extracranial to intracranial bypass in the treatment of aneurysms. Clin Neurosurg 1985;32:114-54.
19. Spetzler RF, Schuster H, Roski RA. Elective extracranial-intracranial arterial bypass in the treatment of inoperable giant aneurysms of internal carotid artery. J Neurosurg 1980;53:22-7.
20. Larson JJ, Tew JM Jr, Tomsick TA, van Loveren HR. Treatment of aneurysms of the internal carotid artery by intravascular balloon occlusion: Long-term follow-up of 58 patients. Neurosurgery 1995;36:26-30.
21. Nakase H, Shin Y, Kanemoto Y, Ohnishi H, Morimoto T, Sakaki T. Long-term outcome of unruptured giant cerebral aneurysms. Neurol Med Chir (Tokyo) 2006;46:379-84.
22. Barnett DW, Barrow DL, Joseph GJ. Combined extracranial-intracranial bypass and intraoperative balloon occlusion for the treatment of intracavernous and proximal carotid artery aneurysms. Neurosurgery 1994;34:92-7.
23. Date I, Ohmoto T. Long-term outcome of surgical treatment of intracavernous giant aneurysms, Neurol Med Chir (Tokyo) 1998;38:62-9.
24. Field M, Jungreis CA, Chengelis N, Kromer H, Kirby L, Yonas H. Symptomatic cavernous sinus aneurysms: Management and outcome after carotid occlusion and selective cerebral revascularization. AJNR Am J Neuroradiol 2003;24:1200-7.
25. Vasconcellos LP, Flores JA, Conti ML, Veiga JC, Lancellotti CL. Spontaneous thrombosis of internal carotid artery: A natural history of giant carotid cavernous aneurysms. Arq Neuropsiquiatr 2009;67:278-83.
26. Drake CG, Peerless SJ, Ferguson GG. Hunterian proximal arterial occlusion for giant aneurysms of the carotid circulation, J Neurosurg 1994;81;656-65.
27. Roski RA, Spetzler RF, Nulsen FE. Late complications of carotid ligation in the treatment of intracranial aneurysms. J Neurosurg 1981;54:583-7.
28. Linskey ME, Jungreis CA, Yonas H, Hirsch WL Jr, Sekhar LN, Horton JA, *et al*. Stroke risk after abrupt internal carotid artery sacrifice: Accuracy of preoperative assessment with balloon test occlusion and stable xenon-enhanced CT. AJNR Am J Neuroradiol 1994;15:829-43.
29. Erba SM, Horton JA, Latchaw RE, Yonas H, Sekhar L, Schramm V, *et al*. Balloon test occlusion of the internal carotid artery with stable xenon/CT cerebral blood flow imaging, AJNR Am J Neuroradiol 1988:9:533-8.
30. Diaz FG, Ausman JI, Pearce JE. Ischemic complications after combined internal carotid artery occlusion and extracranial-intracranial anastomosis. Neurosurgery 1982;10:563-70.
31. Elhammady MS, Wolfe SQ, Farhat H, Ali Aziz-Sultan M, Heros RC. Carotid artery sacrifice for unclippable and uncoilable aneurysms: Endovascular occlusion vs common carotid artery ligation Neurosurgery 2010;67:1431-6.
32. Kai Y, Hamada J, Morioka M, Yano S, Mizuno T, Kuroda J, *et al*. Treatment strategy for giant aneurysms in the cavernous portion of the internal carotid artery. Surg Neurol 2007;67:148-55.
33. Zhu W, Tian YL, Zhou LF, Song DL, Xu B, Mao Y. Treatment strategies for complex internal carotid artery (ICA) aneurysms: Direct ICA sacrifice or combined with extracranial-to-intracranial bypass. World Neurosurg 2011;75:476-84.
34. Tanaka F, Nishizawa S, YonekuraY, Sadato N, Ishizu K, Okazawa H, *et al*. Changes in cerebral blood flow induced by balloon test occlusion of the internal carotid artery under hypotension. Eur J Nucl Med 1995;22:1268-73.
35. Yamashita T, Kashiwagi S, Nakano S, Takasago T, Abiko S, Shiroyama Y, *et al*. The effect of EC-IC bypass surgery on resting cerebral blood flow and cerebrovascular reserve capacity studied with stable XE-CT and acetazolamide test. Neuroradiology 1991;33:217-22.
36. Sudhakar KV, Sawlani V, Phadke RV, Kuma S, Ahmed S, Gujral RB. Temporary balloon occlusion of internal carotid artery: A simple and reliable clinical test. Neurol India 2000;48:140-3.
37. Selkar L, Patel S. Permanent occlusion of the internal carotid artery during skull base surgery and vascular surgery – is it safe. Am J Otol 1993;14:421-2.
38. Segal DH, Sen C, Bederson JB, Catalano P, Sacher M, Stoliman AL, *et al*. Predictive value of Balloon Test occlusion of the internal carotid artery Skull Base Surg 1995;5:97-107.
39. Heros RC. Schmidek and Sweet Operative Neurosurgical Techniques: Indications, Methods, and Results. 4th ed. Philadelphia, PA: WB Saunders Co; 2000.
40. Ezura M, Takahashi A, Yoshimoto T. Combined intravascular parent artery and ophthalmic artery occlusion for giant aneurysms of the supraclinoid internal carotid artery. Surg Neurol 1997;47:360-3.
41. Giannotta SL, McGillicuddy JE, Kindt GW. Gradual carotid artery occlusion in the treatment of inaccessible internal carotid artery aneurysms. Neurosurgery 1979;5:417-21.
42. Odom GL, Tindall GT. Carotid ligation in the treatment of certain intracranial aneurysms. Clin Neurosurg 1968;15:101-16.
43. Pozzati E, Fagioli L, Servadei F, Gaist G. Effect of common carotid ligation on giant aneurysms of the internal carotid artery: Computerized tomography study. J Neurosurg 1981;55:527-31.
44. Tindall GT, Goree JA, Lee JF, Odom GL. Effect of common carotid ligation on size of internal carotid aneurysms and distal intracarotid and retinal artery pressures. J Neurosurg 1966;25:503-11.
45. Kak VK, Taylor AR, Gordon DS. Proximal carotid ligation for internal carotid aneurysms. A long-term follow-up study. J Neurosurg 1973;39:503-13.
46. McKissock W, Paine KE, Walsh LS. An analysis of the results of treatment of ruptured intracranial aneurysms: Report of 772 consecutive cases. J Neurosurg 1960;17:762-76.
47. Nishioka H. Report on the Cooperative Study of Intracranial Aneurysms and Subarachnoid Hemorrhage: Section VIII, Part 1. Results of the treatment of intracranial aneurysms by occlusion of the carotid artery in the neck. J Neurosurg 1966;25:660-82.
48. Gelber BR, Sundt TM Jr. Treatment of intracavernous and giant carotid aneurysms by combined internal carotid ligation and extra- to intracranial bypass. J Neurosurg 1980;52:1-10.
49. Mount LA. Results of treatment of intracranial aneurysms using the Selverstone clamp. J Neurosurg 1959;16:611-8.
50. Poppen JL, Fager CA. Intracranial aneurysms. Results of surgical treatment. J Neurosurg 1960;17:283-96.
51. Voris HC. Complications of ligation of the internal carotid artery. J Neurosurg 1951;8:119-31.
52. Kubo Y, Ogasawara K, Tomitsuka N, Otawara Y, Kakino S, Ogawa A. Revascularization and parent artery occlusion for giant internal carotid artery aneurysms in the intracavernous portion using intraoperative monitoring of cerebral hemodynamics. Neurosurgery 2006
53. Heros RC. Thromboembolic complications after combined internal carotid ligation and extra-to-intracranial bypass. Surg Neurol 1984;21:75-9.

How to cite this article: Menon G, Jayanand S, Krishnakumar K, Nair S. EC-IC bypass for cavernous carotid aneurysms: An initial experience with twelve patients. Asian J Neurosurg 2014;9:82-8.

Source of Support: Nil, **Conflict of Interest:** None declared.