

Idiopathic spinal cord herniation: Clinical review and report of three cases

Johanne C. Summers¹, Yagnesh V. Balasubramani¹, Patrick C. H. Chan^{1,2}, Jeffrey V. Rosenfeld^{1,2}

¹Department of Neurosurgery, The Alfred Hospital, ²Department of Surgery, Monash University, Victoria, Australia

ABSTRACT

Idiopathic spinal cord herniation (ISCH) is a rare condition, of unknown pathogenesis, that primarily affects the thoracic spinal cord. It is characterized by ventral displacement of the spinal cord through a dural defect. The aim of this study was to review the literature and to present a retrospective single center experience with three cases of ISCH. The literature review analyzed a total of 78 relevant publications on ISCH, which included a total of 171 patients, supplemented with 3 patients treated at our institution. Numerous case reports have demonstrated improvement in clinical outcomes after surgery; however, follow-up is predominantly short, data are incomplete, the condition is frequently misdiagnosed, and it is difficult to predict which patients will benefit from surgery. We identified 159 cases treated with surgical management. The mean symptom duration was 54 months, and the mean follow-up 33 months. The result at follow-up was improved neurological outcome in 74%, unchanged result in 18%, and worse outcome in 8%. There were 15 cases of conservative management, with mean symptom duration 52 months and mean follow-up 33 months. The neurological outcome was unchanged in 100%. ISCH is a rare condition causing progressive thoracic myelopathy, and the natural history is unknown. There is a lack of evidence-based treatment strategies, and the majority of cases are treated with surgical management at diagnosis. Management of ISCH needs to be individualized for each patient, and clinicians should be encouraged to report new cases, standardize case reports, and ensure long-term follow-up.

Key words: Dural defect, idiopathic, magnetic resonance imaging, spinal cord herniation

Introduction

Idiopathic spinal cord herniation (ISCH) is a rare condition, originally described in 1974 by Wortzman *et al.*^[1] It is characterized by ventral displacement of the spinal cord through a dural defect, resulting in neurological impairment secondary to adhesion and vascular compromise.^[2] The pathogenesis of the dural defect in the anterior surface of the dural sac is unknown.^[3] The condition primarily affects the thoracic spinal cord, and is more common in middle-aged patients, predominantly females.^[4] In this study, we report three cases of ISCH in the thoracic spine. We present a retrospective single-center experience, and

review the literature in regards to the management of this rare condition.

Methods

A PubMed, MEDLINE, EMBASE, and ISIS Web of Science literature search was conducted using the terms “spinal cord herniation,” “idiopathic spinal cord herniation,” “anterior spinal cord herniation,” and “spontaneous spinal cord herniation.” Relevant literature was also found by checking the reference lists of the selected articles. Articles with insufficient documentation, duplicate publications, pediatric patients, spinal disorders, acute traumatic spinal cord herniation cases, and papers in languages other than English were excluded from the study. A total of 78 relevant publications on ISCH were reviewed, and data collected from the case reports in the papers. A total of 171 patients from the literature were included in this study, supplemented with 3 patients treated at our institution. The data for the 174 cases are listed in Tables 1 to 6. The data analyzed included the symptom interval (duration of symptoms prior to diagnosis), diagnostic imaging, misdiagnosis, management (conservative or operative), operative interval (time to surgery after diagnosis), the follow-up period, and neurological outcome, which was recorded as “improved” (I), “unchanged” (U), or “worse” (W). The

Access this article online	
Quick Response Code:	Website: www.asianjns.org
	DOI: 10.4103/1793-5482.116386

Address for correspondence:

Dr. Johanne C. Summers, Department of Neurosurgery, The Alfred Hospital, 55 Commercial Road, Melbourne, Victoria 3004, Australia.
E-mail: johannesummers@gmail.com

Table 1: Demographic data of the three ISCH patients of the present study

Case	Age (years), sex	Symptoms	Symptom interval (months)	Imaging	ISCH level	Follow-up period (months)	Result
1	66, M	Thoracic back pain	216	MRI	T5	4	U
2	51, F	Thoracic back pain	36	MRI	T7	48	U
3	83, M	Lower limb MS Bladder sphincter dysfunction	60	MRI	T3-T5	3	U

M – Male; F – Female; MS – Motor and sensory deficit; MRI – Magnetic resonance imaging; U – Unchanged; ISCH – Idiopathic spinal cord herniation

Table 2: Imaging results of all series

Imaging	Patients (%)
MRI	81 (46.5)
MRI+CTM	90 (52)
CTM	1 (0.5)
My	2 (1)
Total	174 (100)

MRI – Magnetic resonance imaging; CTM – Computed tomography myelography; My – Myelography

Table 3: Misdiagnosis in all series

Series (reference)	Patients	Misdiagnosis	Surgery for misdiagnosis
Arts <i>et al.</i> ^[5]	2	2 (CSM, DAC)	Y (2)
Barrenechea <i>et al.</i> ^[6]	7	7 (DAC)	Y (3)
Borges <i>et al.</i> ^[2]	3	1 (TDH)	Y (1)
Chaichana <i>et al.</i> ^[7]	1	1 (DAC)	Y (1)
Darbar <i>et al.</i> ^[4]	3	2 (A, DAC)	Y (2)
Gwinn <i>et al.</i> ^[8]	3	1 (DAC)	Y (1)
Hausmann <i>et al.</i> ^[9]	4	2 (IDM, TM)	Y (2)
Hassler <i>et al.</i> ^[10]	10	2 (DAC)	Y (1)
Iyer <i>et al.</i> ^[11]	1	1 (DAC)	Y (1)
Karadeniz-Bilgili <i>et al.</i> ^[12]	1	1 (DAC)	Y (1)
Massicotte <i>et al.</i> ^[13]	8	2 (DAC, TDH)	Y (1)
Najjar <i>et al.</i> ^[14]	1	1 (TM, DAC)	Y (1)
Nakazawa <i>et al.</i> ^[15]	2	1 (DAC)	Y (1)
Pereira <i>et al.</i> ^[16]	1	1 (DAC)	Y (1)
Prada <i>et al.</i> ^[17]	12	1 (DAC)	Y (1)
Selviaridis <i>et al.</i> ^[18]	1	1 (DAC)	Y (1)
Sioutos <i>et al.</i> ^[19]	1	1 (DAC)	Y (1)
Slavotinek <i>et al.</i> ^[20]	1	1 (DAC)	Y (1)
Tronnier <i>et al.</i> ^[21]	1	1 (DAC)	Y (1)
Uchino <i>et al.</i> ^[22]	2	1 (DAC)	Y (1)
Watanabe <i>et al.</i> ^[23]	9	1 (DAC)	Y (1)
Watters <i>et al.</i> ^[24]	1	1 (DAC)	Y (1)
Wortzman <i>et al.</i> ^[1]	1	1 (EDC)	Y (1)
Zairi <i>et al.</i> ^[25]	3	2 (TDH, DAC)	Y (2)
Present study	3	1 (DAC)	

CSM – Cervical spondylotic myelopathy; DAC – Dorsal arachnoid cyst; TDH – Thoracic disc herniation; IDM – Intradural mass; TM – Transverse myelitis; A – Arachnoiditis; EDC – Extradural compression

terminology used to describe spinal cord herniation includes idiopathic, spontaneous, and anterior thoracic spinal cord herniation. We chose to use the term idiopathic spinal cord herniation (ISCH).

This study reports the cases of three patients with ISCH treated at our institution between 2008 and 2012. The relevant data were obtained by retrospective review of the medical records and radiographic imaging. All patients had documented detailed neurological examinations by a consultant neurosurgeon. Gadolinium-enhanced magnetic resonance imaging (MRI) of the thoracic spine was obtained in all patients initially and at follow-up. All three patients were treated with conservative management, consisting of outpatient clinical and radiological follow-up.

Case Reports

Case 1

A 66-year-old previously well man presented with an 18-year history of upper thoracic spine pain. The pain was initially intermittent and mild, but in the 14 months prior to presentation, it had gradually increased in severity and persistence. The pain radiated to the left side of the neck, and when severe, spread around both sides of the chest. The patient reported two episodes of left arm weakness lasting a few hours with spontaneous resolution, but denied paresthesia, sensory loss, or sphincter disturbance. There was no history of spinal surgery, trauma, or spinal disorders. Clinical examination demonstrated an upper thoracic spine gentle kyphosis. There were no abnormal findings on neurological motor, sensory, and reflex examination. A suboptimal quality MRI of the thoracic spine performed at a different institution was interpreted as an intradural mid-thoracic lesion, with a described intradural extramedullary mass indenting the dorsal aspect of the spinal cord. These findings were initially thought to be a dorsal arachnoid cyst. Repeat MRI at our institution demonstrated findings consistent with the characteristic features of ISCH. T2-weighted images showed anterior kinking and mild flattening of the spinal cord at T5, with widening of the subarachnoid space posterior to the cord and pulsation artifact within the CSF space [Figure 1]. The patient was treated with conservative management, with clinical and radiological surveillance. The patient remained neurologically stable at 4 months after presentation.

Case 2

A 51-year-old female presented with a 3-year history of thoracic back pain. Her medical history included diabetes, rheumatoid arthritis, and Sjögren's syndrome. The pain,

Table 4: Surgical management

Series (reference)	Patients	Symptom interval range (months)	Operative interval	Follow-up period range (months)	Result
Abe et al. ^[26]	1	48	SAD	36	I
Aizawa et al. ^[27]	3	36-240	SAD-3	12	I-3
Akaza et al. ^[28]	1	60	SAD	?	I
Ammar et al. ^[29]	1	12	SAD	84	I
Aquilina et al. ^[30]	1	12	SAD	3	I
Arts et al. ^[5]	2	?	SAD-2	?	I-1 U-1
Barbagallo et al. ^[31]	2	60-120	SAD-2	6, ?	U-1 W-1
Barrenechea et al. ^[6]	7	12-84	SAD-6 18 months, RO1	10-147	I-1 U-4 W-2
Bartolomei et al. ^[32]	1	120	SAD	3	I
Baur et al. ^[33]	1	84	SAD	?	I
Borges et al. ^[2]	3	84-144	SAD-3	2-12, ?	I-3
Brugieres et al. ^[34]	2	5-60	SAD-2	?	I-2
Cellerini et al. ^[35]	2	5-12	SAD-2	3	I-2
Chaichana et al. ^[7]	1	60	SAD	2	I
Darbar et al. ^[4]	3	36-60, ?	SAD-3	1, ?	I-3
Dix et al. ^[3]	1	?	SAD	6	I
Eguchi et al. ^[36]	1	120	SAD	3	W
Ellger et al. ^[37]	1	30	SAD	4	I
Ewald et al. ^[38]	1	24	SAD	2	U
Ferre et al. ^[39]	2	12-18	SAD-2	12-24	I-1 W-1
Francis et al. ^[40]	1	18	SAD	?	I
Ghostine et al. ^[41]	1	36	SAD	?	I
Groen et al. ^[42]	3	24-60	SAD-2 ? -1	10-30	I-2 W-1
Gwinn et al. ^[8]	3	6-72, ?	SAD-3	3	I-3
Hassler et al. ^[10]	10	6-96	SAD-10	6-110	I-6 U-3 W-1
Hausmann et al. ^[9]	2	84-96	SAD-2	?	I-1 W-1
Imagama et al. ^[43]	12	12-180	?	24-168	I-12
Inoue et al. ^[44]	1	24	SAD	24	I
Ishida et al. ^[45]	1	36	SAD	?	I
Isu et al. ^[46]	2	12-21	SAD-2	?	I-2
Iyer et al. ^[11]	1	36	SAD	6	I
Karadeniz-Bilgili et al. ^[12]	1	18	SAD	2	I
Kim et al. ^[47]	1	36	SAD	6	I
Kumar et al. ^[48]	1	24	SAD	2	I
Maira et al. ^[49]	5	24-288	SAD-4 72 months, RO1	24-156	I-4 W
Marshman et al. ^[50]	1	168	SAD	12	I
Massicotte et al. ^[13]	4	12-96, ?	SAD-4	12-48	I-2 U-2

Contd...

Table 4: Contd..

Series (reference)	Patients	Symptom interval range (months)	Operative interval	Follow-up period range (months)	Result
Masuzawa et al. ^[51]	1	14	SAD	36	I
Miura et al. ^[52]	1	13	SAD	6	I
Miyaguchi et al. ^[53]	1	25	SAD	6	I
Miyake et al. ^[54]	2	48-72	SAD-2	1	I-2
Morley et al. ^[55]	1	24	SAD	24	I
Morokoff et al. ^[56]	1	96	SAD	3	I
Najjar et al. ^[14]	1	96	SAD	2	I
Nakagawa et al. ^[57]	1	108	SAD	12	I
Nakazawa et al. ^[15]	2	48-60	SAD-2	48, ?	I-2
Novak et al. ^[58]	3	24-72	?-3	3-12	I-1 U-2
Pereira et al. ^[16]	1	48	SAD	18	I
Prada et al. ^[17]	12	12-84	SAD-9 SACM-3	6-84	I-6 U-6
Roland et al. ^[59]	1	?	SAD	?	I
Sagiuchi et al. ^[60]	1	240	SAD	?	I
Saito et al. ^[61]	1	432	SAD	40	U
Saito et al. ^[62]	1	168	SAD	1	I
Sasani et al. ^[63]	1	24	SAD	30	I
Sasaoka et al. ^[64]	1	180	SAD	24	U
Selviaridis et al. ^[18]	1	24	SAD	120	I
Sioutos et al. ^[19]	1	12	SAD	3	W
Slavotinek et al. ^[20]	1	48	SAD	?	I
Spissu et al. ^[65]	1	12	SAD	12	I
Sugimoto et al. ^[66]	1	12	SAD	12	I
Taghipour et al. ^[67]	1	36	SAD	?	I
Tekkok ^[68]	1	36	SAD	5	I
Tronnier et al. ^[21]	1	84	SAD	4	W
Uchino et al. ^[22]	2	24	SAD-2	?	I-1 U-1
Uhl et al. ^[69]	1	48	SAD	1	I
Ulivieri et al. ^[70]	1	?	SAD	?	U
Urbach et al. ^[71]	1	24	SAD	?	I
Vallee et al. ^[72]	4	14-72	SAD-4	2-6	I-2 U-2
Wada et al. ^[73]	3	24-120	SAD-3	48	I-3
Watanabe et al. ^[23]	9	24-60	SAD-9	6-156	I-8 W-1
Watters et al. ^[24]	1	120	SAD	18	I
White et al. ^[74]	2	17	SAD-2	?	U-2
White et al. ^[75]	3	17-96	SAD-3	9-12	I-3
Wortzman et al. ^[1]	1	32	SAD	24	I
Zairi et al. ^[25]	3	24-48	SAD-3	48, ?	I-3
Total	159	5-432 (mean, 54)	3 SAD-138 18 months, RO1-1 72 months, RO1-1 SACM-3 ?-16	1-168 (mean, 33)	I-119 (74%) U-28 (18%) W-12 (8%)

SAD – Surgery at diagnosis; SACM – Surgery after conservative management; ? – Data not available; RO1 – Refused 1st operation; I – Improved; U – Unchanged; W – Worse

Table 5: Surgical management and misdiagnosis

Series (reference)	Symptom interval (months)	Operative interval (months)	Follow-up period (months)	Result
Arts <i>et al.</i> ^[5]	?	SAD, O ₂ (MD CSM, O ₁)	?	U
Arts <i>et al.</i> ^[5]	?	SAD, O ₂ (MD DAC, O ₁)	?	I
Barrenechea <i>et al.</i> ^[6]	36	SAD, O ₂ (MD DAC, O ₁)	60	U
Barrenechea <i>et al.</i> ^[6]	12	SAD, O ₂ (MD DAC, O ₁)	147	W
Barrenechea <i>et al.</i> ^[6]	84	SAD, O ₂ (MD DAC, O ₁)	16	U
Barrenechea <i>et al.</i> ^[6]	27	SAD (MD DAC)	42	I
Barrenechea <i>et al.</i> ^[6]	16	SAD, O ₂ (MD DAC) (TDH, O ₁)	40	W
Barrenechea <i>et al.</i> ^[6]	60	SAD (MD DAC)	30	U
Barrenechea <i>et al.</i> ^[6]	60	18, RO ₁ (MD DAC)	10	U
Borges <i>et al.</i> ^[2]	144	SAD, O ₂ (MD TDH, O ₁ NE)	12	I
Chaichana <i>et al.</i> ^[7]	60	SAD, O ₂ (MD DAC, O ₁)	2	I
Darbar <i>et al.</i> ^[4]	?	SAD, O ₂ DAS (MD DAC, O ₁)	?	I
Darbar <i>et al.</i> ^[4]	60	SAD, DAS (MD A)	?	I
Gwinn <i>et al.</i> ^[8]	?	SAD, O ₂ (MD DAC, O ₁)	3	I
Hassler <i>et al.</i> ^[10]	36	SAD, O ₂ (MD DAC, O ₁)	95	W
Hassler <i>et al.</i> ^[10]	46	SAD (MD DAC)	40	U
Hausmann <i>et al.</i> ^[9]	96	SAD (MD IDM)	?	I
Hausmann <i>et al.</i> ^[9]	84	SAD (MD TM) (MD ₂ IDM)	?	W
Iyer <i>et al.</i> ^[13]	36	SAD, O ₂ (MD DAC, O ₁ NE)	6	I
Karadeniz-Bilgili <i>et al.</i> ^[12]	18	SAD, O ₂ (MD DAC, O ₁)	2	I
Massicotte <i>et al.</i> ^[13]	96	SAD, O ₂ (MD DAC, O ₁)	36	U
Najjar <i>et al.</i> ^[14]	96	SAD, O ₂ (MD TM) (MD ₂ DAC, O ₁)	2	I
Nakazawa <i>et al.</i> ^[15]	60	SAD, DAS (MD DAC)	48	I
Pereira <i>et al.</i> ^[16]	48	SAD, DAS (MD DAC)	18	I
Prada <i>et al.</i> ^[17]	60	SAD, O ₂ (MD DAC, O ₁)	24	I
Selviaridis <i>et al.</i> ^[18]	24	SAD, DAS (MD DAC)	120	I
Sioutos <i>et al.</i> ^[19]	12	SAD, O ₂ (MD DAC, O ₁)	3	W
Slavotinek <i>et al.</i> ^[20]	48	SAD, O ₂ (MD DAC, O ₁)	?	I
Tronnier <i>et al.</i> ^[21]	84	SAD, DAS (MD DAC)	4	W
Uchino <i>et al.</i> ^[22]	24	SAD, DAS (MD DAC)	?	U
Watanabe <i>et al.</i> ^[23]	48	SAD, O ₂ (MD DAC, O ₁)	12	I
Watters <i>et al.</i> ^[24]	120	SAD, O ₂ (MD DAC, O ₁)	18	I
Wortzman <i>et al.</i> ^[1]	32	SAD (MD EDC)	24	I
Zairi <i>et al.</i> ^[25]	36	SAD, O ₂ (MD DAC, O ₁)	?	I
Zairi <i>et al.</i> ^[25]	24	SAD, O ₂ DAS (MD TDH, O ₁)	?	I

SAD – Surgery at diagnosis; DAS – Diagnosis at surgery; MD – Misdiagnosis; MD₂ – Second misdiagnosis; O₁ – 1st operation; O₂ – 2nd operation; RO₁ – Refused 1st operation; NE – Negative exploration; I – Improved; U – Unchanged; W – Worse; CSM – Cervical spondylotic myelopathy; DAC – Dorsal arachnoid cyst; TDH – Thoracic disc herniation; IDM – Intradural mass; TM – Transverse myelitis; A – Arachnoiditis; EDC – Extradural compression

when severe, was associated with nausea and vomiting. The patient reported longstanding reduced sensation bilaterally, in the L5 and S1 distribution, secondary to chronic lumbar spondylosis. There was no change in her lower limb neurological symptoms, specifically, no

Table 6: Conservative management

Series (reference)	Symptom interval (months)	Follow-up period (months)	Result
Adams <i>et al.</i> ^[76]	21	12	U
Ammar <i>et al.</i> ^[29]	?	60	U
Ammar <i>et al.</i> ^[29]	9	15	U
Ferre <i>et al.</i> ^[39]	48	12	U
Hausmann <i>et al.</i> ^[9]	12	?	?
Hausmann <i>et al.</i> ^[9]	36	?	?
Kwong <i>et al.</i> ^[77]	36	?	U
Massicotte <i>et al.</i> ^[13]	168	96	U
Massicotte <i>et al.</i> ^[13]	12	72	U
Massicotte <i>et al.</i> ^[13]	48	72	U
Massicotte <i>et al.</i> ^[13]	24	1	U
Senturk <i>et al.</i> ^[78]	6	6	U
Present study	216	4	U
Present study	36	48	U
Present study	60	3	U

U – Unchanged; ? – Data not available

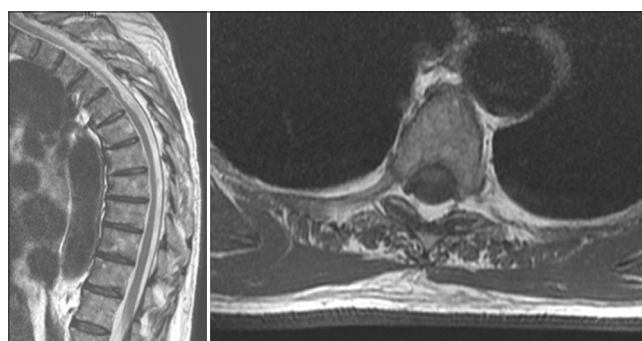


Figure 1: MRI T2-weighted sagittal and axial images. Anterior kinking and flattening of the spinal cord at T5, widening of the subarachnoid space posterior to the cord

radicular pain or sphincter disturbance. There was no history of spinal trauma. Upon clinical examination, there was mild mid-thoracic tenderness. Lower limb neurological examination was complicated by leg stiffness related to the Sjögren's syndrome. There was global mild weakness Medical Research Council (MRC) grade 4/5 in bilateral lower limbs, and reflexes were normal. There was reduced sensation in the L5 and S1 distribution, which was a longstanding finding. MRI of the thoracic spine demonstrated features consistent with ISCH. T2-weighted images showed anterior deviation and flattening of the spinal cord at the T7 vertebral body level, with a small ventral dural defect and mild cord herniation [Figure 2]. The patient was treated conservatively, and at 4-year follow-up, her neurological condition remained stable.

Case 3

An 82-year-old man presented with a 10-day history of progressive bilateral lower limb weakness and generalized numbness in his thorax and lower limbs. He reported a

3-week history of worsening gait ataxia, on a background history of 5 years of mild gait disturbance. On admission, the patient denied having problems with defecation, but had acute difficulty with micturition which resulted in catheter insertion. There was no history of spinal surgery, trauma, or spinal disorders. His medical history included ischemic heart disease, stroke, prostate cancer, and Paget's disease. Clinical examination was significant for a T4 sensory level, with reduced sensation to pin prick and light touch. Motor assessment revealed reduced power in bilateral lower limbs, with the following MRC grades: 1+/5 proximal and 3/5 distal. MRI was diagnostic for ISCH. T2-weighted images demonstrated ventral displacement of the thoracic spinal cord with moderate flattening, focal atrophy, and anterior herniation through the dura at T3-5 [Figure 3]. The CSF flow pattern dorsal to the cord at that level was preserved, but ventral to the cord, the CSF flow pattern was absent. Following a full discussion of the options with the patient, the decision was made for non-operative management. At 3 months after presentation, the patient remained neurologically stable.

Discussion

ISCH is a rare, potentially under-diagnosed cause of progressive thoracic myelopathy, with around 170 cases reported in the literature. It is more common in middle-aged patients, with a mean age of 49 years (range, 22-75 years), and occurs predominantly in females.^[4,37] The condition is characterized by a spontaneous displacement of the spinal cord through an anterior dural defect. Several theories on the pathogenesis have been proposed, including congenital dural deficiency, history of trauma, pressure erosion of the dura, and duplication of the ventral dura.^[3,53,55] The thoracic spine is predominantly involved, with levels T3-T7 more frequently affected.^[42] It has been proposed that thoracic spine involvement can be explained by the normal kyphosis of the thoracic spine, the anterior position of the thoracic spinal cord, the impact of flexion and extension movements, and the physiological ventral movement of the spinal cord secondary to cardiac and pulmonary actions.^[63]

Clinical symptoms are largely dependent on the site of spinal cord herniation, and are usually longstanding before the diagnosis, with the mean duration of symptoms of 40 months.^[4,10] Progressive Brown-Séquard syndrome is the most common clinical presentation, with variable deficits of ipsilateral hemiparesis and proprioception loss, and contralateral loss of pain and temperature sensation.^[42] Other reported presentations include paraparesis, sensory disturbance, bowel and bladder sphincter dysfunction, and chest pain.^[4,53,78]

MRI is the investigation of choice for the diagnosis of ISCH. Sagittal sections often demonstrate enlargement of the dorsal subarachnoid space, with ventral displacement and an

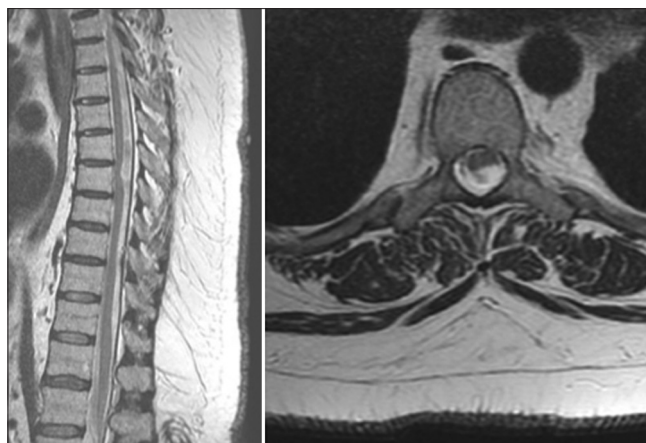


Figure 2: MRI T2-weighted sagittal and axial images. Anterior deviation and flattening spinal cord at T7, small ventral dural defect, mild cord herniation

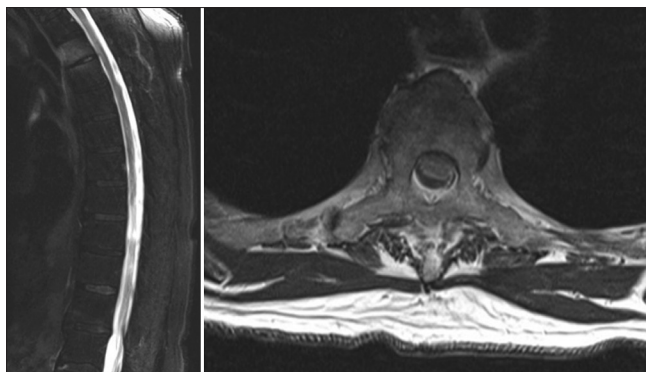


Figure 3: MRI T2-weighted sagittal and axial images. Ventral displacement thoracic spinal cord, moderate flattening, anterior herniation through the dura T3-5

anterior C- or S-shaped kink of the thoracic spinal cord.^[6,39] On axial imaging, the cord herniation is attached to the anterior dura mater with no intervening CSF, and the herniated cord may be thinned secondary to atrophy with or without signal change.^[14] Axial images may allow visualization of the nerve roots traversing the dorsal subarachnoid space, in contrast to dorsal arachnoid cysts, where the nerve roots are seen at the periphery of the cyst.^[6] Phase-contrast MRI and CT myelogram can be used to confirm the diagnosis of ISCH and differentiate between a widened dorsal subarachnoid space and a dorsal arachnoid cyst. In cases of ISCH, phase-contrast MRI typically demonstrates normal dorsal pulsatile CSF flow and CT myelogram demonstrates obliteration of CSF space ventral to the spinal cord with no differential contrast medium retention dorsal to the cord.^[3,4,14,34,76] High-resolution MRI has enhanced diagnostic ability and reduced the need for CT myelography.^[6,43] The rare use of thoracic myelography imaging has been documented.^[1,4] In this review of 174 cases of ISCH, MRI alone was performed in 81 patients (46.5%), combined MRI and CT myelography in 90 (52%), and CT myelography alone in 1 patient. Only two cases used thoracic myelography.^[1,4] In the three patients that we have presented in this study, the

classic MRI features of ISCH were present and were diagnostic in all three cases.

Misdiagnosis is reported in a number of ISCH case reports. The most frequent misinterpretation is as a dorsal arachnoid cyst^[1,4-8,10-21,23-25] previously reported as a false diagnosis in around 45% of cases,^[79,80] but it has been reported that an associated dorsal arachnoid cyst is potentially present in 20-25% of patients with ISCH.^[79,80] Other misdiagnoses include thoracic disc herniation,^[1,2,13] transverse myelitis,^[9,14] arachnoiditis,^[4] intradural mass,^[9] and extradural compressive lesion.^[1] Misdiagnosis has been reported to result in erroneous surgery, with lack of clinical improvement or progressive neurological symptoms resulting in a second operation to address the spinal cord herniation.^[4,6,14,15,19,22,24] In this literature review, misdiagnosis was reported in 37 ISCH cases (21%), and in 30 patients an operation was performed as a result of the misdiagnosis. In some cases, ISCH was identified and treated during surgery. However, in 23 cases, a second operation was required to treat the spinal cord herniation. In this study, misdiagnosis occurred in case 1. MRI performed at a different institution was initially misinterpreted as a dorsal arachnoid cyst. Suboptimal quality images appeared to show an intradural–extramedullary mass indenting the dorsal aspect of the spinal cord. Repeat MRI was diagnostic for ISCH.

Management of ISCH

Treatment of ISCH consists of either conservative management or surgery, but owing to the unclear natural history of the condition, an optimal treatment strategy has not been formulated, and management needs to be individualized for each patient. Surgery is generally recommended for patients with motor function deficit or progressive neurological symptoms.^[42,63,81] Surgical treatment aims to reduce the spinal cord herniation and prevent recurrence. Various operative techniques have been described, including dorsal and ventral surgical approaches, with use of a dural patch or widening the dural defect to prevent cord strangulation.^[2,7] Pre-operative Brown-Séquard syndrome and release of the herniated spinal cord have been identified as independent factors associated with favorable postoperative outcome.^[42]

The majority cases of ISCH are treated with surgical management, but there is limited evidence in the literature to predict which patients will benefit from surgery.^[81] Most patients undergo surgery at the time of diagnosis, with only a small number of reported cases of trialed conservative management prior to proceeding to operative intervention.^[17] The condition is rare, case reports document a wide range of clinical presentations, and the follow-up periods are variable. Cases of recurrence of symptoms after ISCH surgery are reported, ranging from 18 months to 10 years,^[18,29,57] highlighting the need for long-term follow-up. It is reported that surgery for ISCH generally results in improvement or stabilization of neurological symptoms, but deterioration with worsening

neurology is also reported. Reviews of the literature outline observations on case reports and the experience of individual institutions.^[4,42,63] Most reports have limited information on the neurological assessment and do not use validated outcome scores to allow for standardized comparison. Neurological outcome data are generally documented as “improved” (I), “unchanged” (U), or “worse” (W). The meta-analysis by Groen *et al.*,^[42] reported the surgical results of 121 ISCH patients, with neurological improvement in 73%, unchanged result in 20%, and worse outcome in 7%. The follow-up period data were available in 73% of cases, with a relatively short mean follow-up of 24 months. Hassler *et al.*,^[10] in their series of 10 surgically managed patients, with mean follow-up of 61 months, reported improved results in 6 patients, unchanged results in 3, and worse outcome in 1 patient. Sasani *et al.*,^[63] in their review of the literature of ISCH surgery, identified improvement in clinical outcomes in 73%, unchanged result in 20%, and deterioration in 7% of patients. Prada *et al.*^[17] reported a series of 12 ISCH cases, with 50% of patients showing improved symptomatology after surgery, and the others remained free from symptom progression. Another series of 12 patients, with a mean follow-up period of 74 months, described postoperative improvement in all cases.^[43] The series of seven ISCH surgical cases by Barrenechea *et al.*^[6] reported improved result in one patient, unchanged result in four, and worse outcome in two patients.

In this study, the review of the literature identified 159 cases of ISCH treated with surgical management. The symptom interval was specified for 151 patients, ranging between 5 and 432 months (mean, 54 months). Data on the result of neurological outcome after surgery were available for all 159 patients. Improvement in neurological outcome was reported in 119 patients (74%). In 28 patients (18%), the neurological outcome was unchanged, and in 12 patients (8%), the result at follow-up was worse after operative intervention. The follow-up period data were reported for 129 cases, ranging from 1 to 168 months, with a mean follow-up of 33 months. In order to better define the outcomes of the surgical management of ISCH, long-term follow-up is required.

A conservative treatment approach for ISCH, with clinical and radiological surveillance, has been suggested for patients without progressive myelopathy or significant motor deficits.^[9,13,29,76,78] Twelve cases of conservative management have been reported in the literature.^[9,13,29,39,76-78] We reviewed 15 patients managed with non-operative management, including the 3 cases in this study. The symptom interval was specified in 14 cases, ranging between 6 and 216 months (mean, 52 months). Follow-up period data were available for 12 cases, ranging between 1 and 96 months (mean, 33 months). Data on the neurological outcome at follow-up were documented for 13 patients, with the result unchanged in all 13 cases (100%). The Ammar *et al.*^[29] series reported on two ISCH non-operative

cases with follow-up periods 15 and 60 months, and Massicote *et al.*^[13] reported four patients with follow-up periods up to 96 months. In all six cases, there was no weakness or spasticity on clinical presentation. In the two cases of conservative management described by Hausmann *et al.*,^[9] the patients presented with motor deficit, but outcome data were not specified. There were two patients who presented with thoracic back pain without motor, sensory, or sphincter disturbance, one in Senturk *et al.*'s^[78] paper with 6 months follow-up and the other one described by Kwong *et al.*,^[77] but the follow-up period was not specified. Two conservatively managed ISCH cases with 12-month follow-up periods were reported, one in the Ferré *et al.*^[39] series with right hemi-sensory deficit below T6 and the other one in the Adams *et al.*'s^[76] paper with right hemi-sensory deficit below T10. In the series by Prada *et al.*,^[17] conservative management was initially undertaken in three cases, but worsening in neurology and imaging resulted in surgical intervention. In this study, we presented three ISCH patients treated with non-operative management. In two of the cases, the clinical presentation was thoracic back pain. In case 2, back pain was the only symptom, and in case 1, there was a history of two short episodes of left arm weakness with spontaneous resolution but no sensory symptoms or sphincter disturbance. In case 3, the patient presented with motor and sensory impairment, with a T4 sensory level, bilateral lower limb motor deficit, and bladder sphincter disturbance. The mean symptom interval was 104 months (range, 36-216 months), and the mean follow-up was 18 months (range, 3-48 months). The neurological result was unchanged in all three cases.

The natural history of ISCH remains unknown, as it is difficult to predict the course of this rare condition,^[13,20] and the majority of cases in the literature have been treated with surgical management at diagnosis. It has been suggested that a conservative management approach should be trialed when possible, in order to attempt to define the natural history, as the clinical presentation is often nonspecific and neurological deterioration may not occur.^[29] Based on the results of our literature review, we formulated a treatment algorithm [Figure 4]. According to this algorithm, conservative treatment should be considered for patients without progressive myelopathy or significant motor deficits, and surgical treatment for patients with motor function deficits or progressive neurological symptoms. Surveillance with clinical assessment should be undertaken in both conservative and surgical treatment, and repeat MRI performed for patients with neurological deterioration.

In this paper, we report a retrospective single-center experience with three cases of ISCH and review the literature on this rare condition. Potential publication bias could arise with analysis of data on management outcome; however, the objective of this review article was not to create treatment

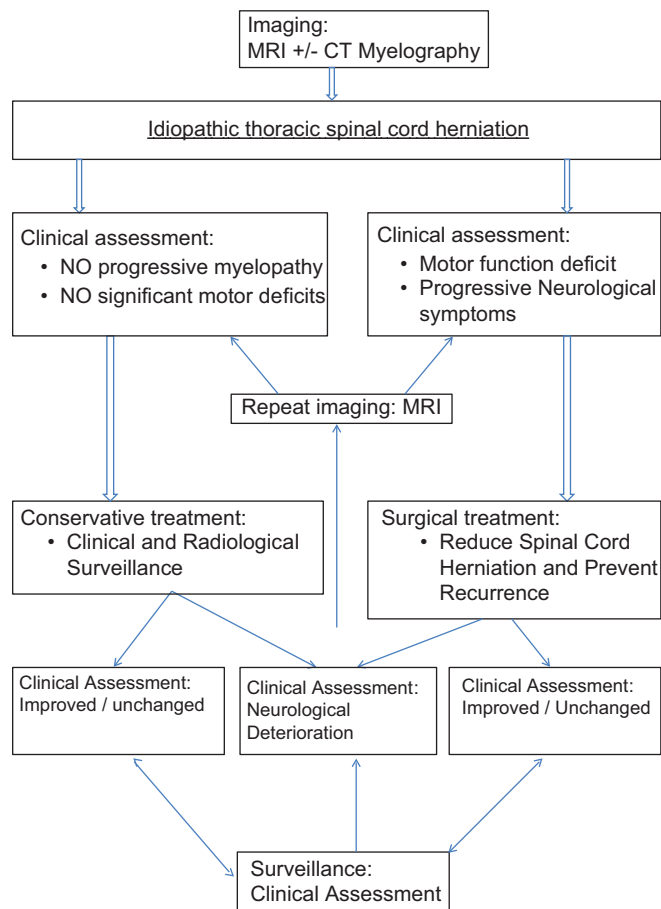


Figure 4: Treatment algorithm

guidelines or favorable results toward a certain treatment. The limitation of this study was the retrospective nature and short follow-up periods for the three reported cases. However, follow-up is ongoing, and we are aware of the lack of and need for long-term follow-up in the ISCH literature.

Conclusion

ISCH is a rare condition causing progressive thoracic myelopathy. Clinical experience is limited, and the condition is often misdiagnosed, most commonly as a dorsal arachnoid cyst. The literature consists of individual case reports and small series, resulting in a lack of evidence-based treatment strategies. The natural history of ISCH remains unknown, with most cases treated with surgical management at diagnosis. For patients with motor function deficit or progressive neurological symptoms, surgical treatment is generally recommended, with the aim of reducing the spinal cord herniation and preventing recurrence. Conservative treatment, with clinical and radiological surveillance, should be considered for patients without progressive myelopathy or significant motor deficits. Management of ISCH needs to be individualized for each patient, and long-term follow-up is required in order to better define the outcomes of both

conservative and surgical management. Clinicians should be encouraged to report new cases, standardize case reports, and ensure long-term follow-up.

References

- Wortzman G, Tasker RR, Rewcastle NB, Richardson JC, Pearson FG. Spontaneous incarcerated herniation of the spinal cord into a vertebral body: A unique cause of paraplegia: Case report. *J Neurosurg* 1974;41:631-5.
- Borges LF, Zervas NT, Leirich JR. Idiopathic spinal cord herniation: A treatable cause of the Brown-Sequard syndrome: Case report. *Neurosurgery* 1995;36:1028-33.
- Dix JE, Griffit W, Yates C, Johnson B. Spontaneous thoracic spinal cord herniation through an anterior dural defect. *AJNR Am J Neuroradiol* 1998;19:1345-8.
- Darbar A, Krishnamurthy S, Holsapple JW, Hodge CJ Jr. Ventral thoracic spinal cord herniation: Frequently misdiagnosed entity. *Spine (Phila Pa 1976)* 2006;31:E600-5.
- Arts MP, Lycklama à Nijeholt G, Wurzer JA. Surgical treatment of idiopathic transdural spinal cord herniation: A new technique to untether the spinal cord. *Acta Neurochir (Wien)* 2006;148:1005-9.
- Barrenechea IJ, Lesser JB, Gidekel AL, Turjanski L, Perin NI. Diagnosis and treatment of spinal cord herniation: A combined experience. *J Neurosurg Spine* 2006;5:294-302.
- Chaichana KL, Sciubba DM, Li KW, Gokaslan ZL. Surgical management of thoracic spinal cord herniation: Technical considerations. *J Spinal Disord Tech* 2009;22:67-71.
- Gwinn R, Henderson F. Transdural herniation of the thoracic spinal cord: Untethering via a posterolateral transpedicular approach. Report of three cases. *J Neurosurg Spine* 2004;1:223-7.
- Hausmann ON, Moseley IF. Idiopathic dural herniation of the thoracic spinal cord. *Neuroradiology* 1996;38:503-10.
- Hassler W, Al-Kahlout E, Schick U. Spontaneous herniation of the spinal cord: Operative technique and follow-up in 10 cases. *J Neurosurg Spine* 2008;9:438-43.
- Iyer RV, Coutinho C, Lye RH. Spontaneous spinal cord herniation. *Br J Neurosurg* 2002;16:507-10.
- Karadeniz-Bilgili MY, Castillo M, Bernard E. Transdural spinal cord herniation: Pre- and post-operative MRI findings. *Clin Imaging* 2005;29:288-90.
- Massicotte EM, Montanera W, Ross Fleming JF, Tucker WS, Willinsky R, ter Brugge K, et al. Idiopathic spinal cord herniation: Report of eight cases and review of the literature. *Spine (Phila Pa 1976)* 2002;27:E233-41.
- Najjar MW, Baeesa SS, Lingawi SS. Idiopathic spinal cord herniation. A new theory of pathogenesis. *Surg Neurol* 2004;62:161-71.
- Nakazawa H, Toyama Y, Satomi K, Fujimura Y, Hirabayashi K. Idiopathic spinal cord herniation. Report of two cases and review of the literature. *Spine (Phila Pa 1976)* 1993;18:2138-41.
- Pereira P, Duarte F, Lamas R, Vaz R. Idiopathic spinal cord herniation: Case report and literature review. *Acta Neurochir (Wien)* 2001;143:401-6.
- Prada F, Saladino A, Giombini S, Erbetta A, Saini M, DiMeco F, et al. Spinal cord herniation: Management and outcome in a series of 12 consecutive patients and review of the literature. *Acta Neurochir* 2012;154:723-30.
- Selviaridis P, Balogiannis I, Foroglou N, Hatzisotiriou A, Patsalas I. Spontaneous spinal cord herniation: Recurrence after 10 years. *Spine J* 2009;9:e17-9.
- Sioutos P, Arbit E, Tsairis P, Gargan R. Spontaneous thoracic spinal cord herniation. A case report. *Spine (Phila Pa 1976)* 1996;21:1710-3.
- Slavotinek JP, Sage MR, Brophy BP. An unusual spinal intradural arachnoid cyst. *Neuroradiology* 1996;38:152-4.
- Tronnier VM, Steinmetz A, Albert FK, Scharf J, Kunze S. Hernia of the spinal cord: Case report and review of the literature. *Neurosurgery* 1991;29:916-9.
- Uchino A, Kato A, Momozaki N, Yukiwake M, Kudo S. Spinal cord herniation: Report of two cases and review of the literature. *Eur Radiol* 1997;7:289-92.
- Watanabe M, Chiba K, Matsumoto M, Maruiwa H, Fujimura Y, Toyama Y. Surgical management of idiopathic spinal cord herniation: A review of nine cases treated by the enlargement of the dural defect. *J Neurosurg* 2001;95:169-72.
- Watters MR, Stears JC, Osborn AG, Turner GE, Burton BS, Lillehei K, et al. Transdural spinal cord herniation: Imaging and clinical spectra. *AJNR Am J Neuroradiol* 1998;19:1337-44.
- Zairi F, Thines L, Bourgeois P, Dereeper O, Assaker R. Spinal cord herniation: A misdiagnosed and treatable cause of thoracic myelopathy. *Acta Neurochir* 2010;152:1991-6.
- Abe M, Komori H, Yamaura I, Kayano T. Spinal cord herniation into an extensive extradural meningeal cyst: Postoperative analysis of intracystic flow by phase-contrast cine MRI. *J Orthop Sci* 1999;4:450-6.
- Aizawa T, Sato T, Tanaka Y, Kotajima S, Sekiya M, Kokubun S. Idiopathic herniation of the thoracic spinal cord: Report of three cases. *Spine (Phila Pa 1976)* 2001;26:E488-91.
- Akaza M, Tsunemi T, Hotate M, Toru S, Mizusawa H. Spinal cord herniation which manifested stepwise deterioration. *Intern Med* 2007;46:537-8.
- Ammar KN, Pritchard PR, Matz PG, Hadley MN. Spontaneous thoracic spinal cord herniation: Three cases with long-term followup. *Neurosurgery* 2005;57:E1067.
- Aquilina K, Nanra JS, Rawluk D. Idiopathic spinal cord hernia. *Ir Med J* 2004;97:115-6.
- Barbagallo GM, Marshman LA, Hardwidge C, Gullan RW. Thoracic idiopathic spinal cord herniation at the vertebral body level: A subgroup with a poor prognosis? Case reports and review of the literature. *J Neurosurg* 2002;97:369-74.
- Bartolomei J, Wong J, Awad IA, Dickman CA, Das K, Kalfas I, et al. Case problems conference: Thoracic spinal cord hernia. *Neurosurgery* 2000;46:1408-15.
- Baur A, Stähler A, Psenner K, Hamburger C, Reiser M. Imaging findings in patients with ventral dural defects and herniation of neural tissue. *Eur Radiol* 1997;7:1259-63.
- Brugières P, Malapert D, Adle-Biasette H, Fuerxer F, Djindjian M, Gaston A. Idiopathic spinal cord herniation: Value of MR phase-contrast imaging. *AJNR Am J Neuroradiol* 1999;20:935-9.
- Cellerini M, Bayon S, Scazzari F, Mangiafico S, Amantini A, Guizzardi GC, et al. Idiopathic spinal cord herniation: A treatable cause of Brown-Séquard syndrome. *Acta Neurochir (Wien)* 2002;144:321-5.
- Eguchi T, Yokota H, Nikaido Y, Nobayashi M, Nishioka T. Spontaneous thoracic spinal cord herniation: Case report. *Neurol Med Chir (Tokyo)* 2001;41:508-12.
- Ellger T, Schul C, Heindel W, Evers S, Ringelstein EB. Idiopathic spinal cord herniation causing progressive Brown-Séquard syndrome. *Clin Neurol Neurosurg* 2006;108:388-91.
- Ewald C, Kühne D, Hassler WE. Progressive spontaneous herniation of the thoracic spinal cord: Case report. *Neurosurgery* 2000;46:493-5.
- Ferré JC, Carsin-Nicol B, Hamlat A, Carsin M, Morandi X. MR imaging features of idiopathic thoracic spinal cord herniations using combined 3D-fiesta and 2D-PC Cine techniques. *J Neuroradiol* 2005;32:125-30.
- Francis D, Batchelor P, Gates P. Posttraumatic spinal cord herniation. *J Clin Neurosci* 2006;13:582-6.
- Ghostine S, Baron EM, Perri B, Jacobson P, Morsette D, Hsu FP. Thoracic cord herniation through a dural defect: Description of a case and review of the literature. *Surg Neurol* 2009;71:362-7.
- Groen RJ, Middel B, Meilof JF, de Vos-van de Biezenbos JB, Enting RH, Coppes MH, et al. Operative treatment of anterior thoracic spinal cord herniation: Three new cases and an individual patient data meta-analysis of 126 case reports. *Neurosurgery* 2009;64(Suppl 3):145-60.
- Imagama S, Matsuyama Y, Sakai Y, Nakamura H, Katayama Y, Ito Z, et al. Image classification of idiopathic spinal cord herniation based on symptom severity and surgical outcome: A multicenter study. *J Neurosurg Spine* 2009;11:310-9.
- Inoue T, Cohen-Gadol AA, Krauss WE. Low-pressure headaches and spinal cord herniation. Case report. *J Neurosurg* 2003;98:93-5.
- Ishida M, Maeda M, Kasai Y, Uchida A, Takeda K. Idiopathic

- spinal cord herniation through the inner layer of duplicated anterior dura: Evaluation with high-resolution 3D MRI. *J Clin Neurosci* 2008;15:933-7.
46. Isu T, Iizuka T, Iwasaki Y, Nagashima M, Akino M, Abe H. Spinal cord herniation associated with an intradural spinal arachnoid cyst diagnosed by magnetic resonance imaging. *Neurosurgery* 1991;29:137-9.
 47. Kim J, Oh SH, Kim K, Park S, Park KS. Idiopathic spinal cord herniation as a treatable cause of progressive brown-sequard syndrome. *J Clin Neurol* 2007;3:204-7.
 48. Kumar R, Taha J, Greiner AL. Herniation of the spinal cord: Case report. *J Neurosurg* 1995;82:131-6.
 49. Maira G, Denaro L, Doglietto F, Mangiola A, Colosimo C. Idiopathic spinal cord herniation: Diagnostic, surgical, and follow-up data obtained in five cases. *J Neurosurg Spine* 2000;4:10-9.
 50. Marshman LA, Hardwidge C, Ford-Dunn SC, Olney JS. Idiopathic spinal cord herniation: Case report and review of the literature. *Neurosurgery* 1999;44:1129-33.
 51. Masuzawa H, Nakayama H, Shitara N, Suzuki T. Spinal cord herniation into a congenital extradural arachnoid cyst causing Brown-Séquard syndrome: Case report. *J Neurosurg* 1981;55:983-6.
 52. Miura Y, Mimatsu K, Matsuyama Y, Yoneda M, Iwata H. Idiopathic spinal cord herniation. *Neuroradiology* 1996;38:155-6.
 53. Miyaguchi M, Makamura H, Shakudo M, Inoue Y, Yamano Y. Idiopathic spinal cord herniation associated with intervertebral disc extrusion: A case report and review of the literature. *Spine (Phila Pa 1976)* 2001;26:1090-4.
 54. Miyake S, Tamaki N, Nagashima T, Kurata H, Eguchi T, Kimura H. Idiopathic spinal cord herniation: Report of two cases and review of the literature. *J Neurosurg* 1998;88:331-5.
 55. Morley S, Naidoo P, Robertson A, Chong W. Thoracic ventral dural defect: Idiopathic spinal cord herniation. *Australas Radiol* 2006;50:168-70.
 56. Morokoff AP, Tress BM, Kaye AH. Idiopathic spinal cord herniation. *J Clin Neurosci* 2001;8:180-3.
 57. Nakagawa H, Kamimura M, Uchiyama S, Takahara K, Itsubo T, Miyasaka T. Idiopathic spinal cord herniation associated with a large erosive bone defect: A case report and review of the literature. *J Spinal Disord Tech* 2003;16:299-305.
 58. Novak K, Bueno de Camargo A, Knosp E, Perin N, Widhalm G, Deletis V, et al. Motor evoked potentials in three cases of thoracic spinal cord herniation. *Clin Neurophysiol* 2006;117:115-6.
 59. Roland T, Haven F, Gillie M, Van Campenhoudt M. Idiopathic spinal cord herniation. *JBR-BTR* 2006;89:101.
 60. Sagiuchi T, Iida H, Tachibana S, Utsuki S, Tanaka R, Fujii K. Idiopathic spinal cord herniation associated with calcified thoracic disc extrusion-case report. *Neurol Med Chir (Toyko)* 2003;43:364-8.
 61. Saito T, Anamizu Y, Nakamura K, Seichi A. Case of idiopathic thoracic spinal cord herniation with a chronic history: A case report and review of the literature. *J Orthop Sci* 2004;9:94-8.
 62. Saito A, Takahashi T, Sato S, Kumabe T, Tominaga T. Modified surgical technique for the treatment of idiopathic spinal cord herniation. *Minim Invasive Neurosurg* 2006;49:120-3.
 63. Sasani M, Ozer AF, Vural M, Sarioglu AC. Idiopathic spinal cord herniation: Case report and review of the literature. *J Spinal Cord Med* 2009;32:86-94.
 64. Sasaoka R, Nakamura H, Yamano Y. Idiopathic spinal cord herniation in the thoracic spine as a cause of intractable leg pain: Case report and review of the literature. *J Spinal Disord Tech* 2003;16:288-94.
 65. Spissu A, Peltz MT, Matta G, Cannas A. Traumatic transdural spinal cord herniation and the nuclear trail sign: Case report. *Neurol Sci* 2004;25:151-3.
 66. Sugimoto T, Kasai Y, Takegami K, Morimoto R, Maeda M, Uchida A. A case of idiopathic spinal cord herniation with duplicated dura mater. *J Spinal Disord Tech* 2005;18:106-11.
 67. Taghipour M, Zamanizadeh B, Zare Z, Haghnegahdar A, Javadi S. Herniation of the spinal cord: Case report and review of the literature. *Neurosurg Q* 2004;14:105-7.
 68. Tokkök IH. Spontaneous spinal cord herniation: Case report and review of the literature. *Neurosurgery* 2000;46:485-92.
 69. Uhl E, Holtmannspötter M, Tonn JC. Improvement of Brown-Sequard syndrome after surgical repair of an idiopathic thoracic spinal cord herniation. *J Neurol* 2008;255:125-6.
 70. Ulivieri S, Olivieri G, Petrini C, D'Elia F, Cuneo GL, Cerase A. Thoracic spinal cord herniation: Case report and technical note. *Neurol Neurochir Pol* 2009;43:86-9.
 71. Urbach H, Kaden B, Pechstein U, Solymosi L. Herniation of the spinal cord 38 years after childhood trauma. *Neuroradiology* 1996;38:157-8.
 72. Vallée B, Mercier P, Menei P, Bouhour F, Fischer C, Fournier D, et al. Ventral transdural herniation of the thoracic spinal cord: Surgical treatment in four cases and review of the literature. *Acta Neurochir (Wien)* 1996;141:907-13.
 73. Wada E, Yonenobu K, Kang J. Idiopathic spinal cord herniation: Report of three cases and review of the literature. *Spine (Phila Pa 1976)* 2000;25:1984-8.
 74. White BD, Firth JL. Anterior spinal hernia: An increasingly recognized cause of thoracic cord dysfunction. *J Neurol Neurosurg Psychiatry* 1994;57:1433-5.
 75. White BD, Tsegaye M. Idiopathic anterior spinal cord hernia: Under-recognized cause of thoracic myelopathy. *Br J Neurosurg* 2004;18:246-9.
 76. Adams RF, Anslow P. The natural history of transdural herniation of the spinal cord: Case report. *Neuroradiology* 2001;43:383-7.
 77. Kwong Y, Jakanani G, Rao N, Fang CS. MRI findings in herniation of the spinal cord. *J Radiol Case Rep* 2010;4:1-5.
 78. Senturk S, Guzel A, Guzel E. Atypical clinical presentation of idiopathic thoracic spinal cord herniation. *Spine (Phila Pa 1976)* 2008;33:474-7.
 79. Asgari S, Brondics A, Sandalcioğlu IE, Schaefer H, Stolke D. Idiopathic herniation of the spinal cord: Review of the literature and own experiences. *Akt Neurol* 2002;29:383-8.
 80. Blasel S, Hattungen E, Baas H, Zanella F, Weidauer S. Spontaneous spinal cord herniation: MR imaging and clinical features in six cases. *Clin Neuroradiol* 2008;4:224-30.
 81. Shin JH, Krishnaney AA. Idiopathic ventral spinal cord herniation: A rare presentation of tethered cord. *Neurosurg Focus* 2010;29:E10.

How to cite this article: Summers JC, Balasubramani YV, Chan PC, Rosenfeld JV. Idiopathic spinal cord herniation: Clinical review and report of three cases. *Asian J Neurosurg* 2013;8:97-105.

Source of Support: Nil, **Conflict of Interest:** None declared.