Article published online: 2022-09-27

ORIGINAL ARTICLE

Posterior fossa meningioma "our experience" in 64 cases

Vernon Velho, Vivek Agarwal, Rahul Mally, D. A. Palande
Department of Neurosurgery, Grant Medical College and Sir J. J. Group of Hospitals, Mumbai, Maharashtra, India

ABSTRACT

Background: Posterior fossa meningiomas are 20% of all intracranial meningiomas. These are slow-growing tumors thus become large before presentation. Microsurgical resection is the treatment of choice for the majority of these lesions, but variable locations, large size at diagnosis, frequent encroachment of neural and vascular structures, and their potentially invasive behavior are some of the features of these tumors that make their resection challenging.

Materials and Methods: We studied 64 cases of posterior fossa meningioma operated in last 6 years, and analysed the technical difficulties encountered during excision of these tumors. Postoperative complications and outcomes of these patients were also analysed.

Results: Gross total excision was achieved in 72% cases. Partial excision or subtotal excision was more in petroclival, jugular foramen with extra cranial extension, tentorial with intrasinus extension and ventral foramen magnum. Postoperative complication in form of new or aggravation of existing neurological deficit was found in 33% cases and CSF leak in 12.5% cases. We encountered the recurrence of total 10 cases (16%) over mean follow-up of 4 years. Most of the recurrent cases were seen in petroclival and tentorial subgroups with partial or subtotal excision.

Conclusion: Posterior fossa meningiomas are difficult to excise due to close relation to cranial nerves and vessels. Use of microscope, CUSA, intraoperative nerve monitor help in removal and preserving surrounding important anatomical structures. Although neurological deterioration is common postoperatively, recovery does occur completely after total removal thus increasing the recurrence free period and improving the outcome.

Key words: Complication, fossa, meningioma, posterior, technique

Introduction

Meningiomas are benign neoplastic lesions constitute about 20% of all intracranial tumors. Posterior fossa meningiomas are 10% of all intracranial meningiomas.[1,2] These are slow-growing tumors thus become large before presentation.[3] Posterior fossa meningiomas include (1) Cerebellar convexity, Lateral tentorial, (2) C P Angle, (3) Jugular foramen, (4) Petroclival, (5) Foramen Magnum, 6. Unclassified groups (Sekhar and Wright) [Table 1].[4] Microsurgical resection is the treatment of choice for the majority of these lesions but variable locations, large size at diagnosis, frequent encroachment of neural and vascular structures, and their potentially invasive behavior are some of the features of these tumors that make their resection challenging.[5]

Out of 440 cases of intracranial meningioma managed in our institute in last 6 years, 64 cases were posterior fossa meningioma, constituting about 14.5%.

Aims and objectives

The study is done to highlight the technical difficulties encountered during excision of these tumors and discuss their modes of management.

Materials and Methods

This is a retrospective study of 64 cases having various subgroups of posterior fossa meningioma operated in 6 years (April 2004 to 2010) at the neurosurgery department, Sir J. J. Hospital, Mumbai.

All the patients were investigated by contrast enhanced CT scan brain, MRI brain with contrast, MR angiogram and

Access this article online	
Quick Response Code:	Website: www.asianjns.org
	DOI: 10.4103/1793-5482.103710

Address for correspondence:
Dr. Vivek Agarwal, Department of Neurosurgery, Grant Medical College and Sir J. J. Group of Hospital, Mumbai, Maharashtra, India.
E-mail: neuro.vi@gmail.com

venogram. Postoperative complications and outcomes of these patients were analysed.

Observation and results

There were 64 cases of posterior fossa meningioma, of whom 48(75%) were females and 16 (25%) were males. Their age ranged from 18 to 71 years with a mean of 44 years.

Most of the patients presented with cranial nerves dysfunction, of which otologic symptoms were most frequent. Beside that headache, cerebellar compression syndrome, brain stem compression syndrome and features of raised ICP were other common presentations at the time of diagnosis [Table 2].

Hydrocephalus was present in 28 cases in our study. In sixteen cases ventriculo-peritoneal shunt was done. And in rest, EVD was inserted before surgery

CP angle meningioma was commonest followed by Petroclival subgroup in this study.

Retromastoid suboccipital craniectomy was the commonest approach taken for CP angle, petroclival, lateral tentorial and Jugular foramen meningioma [Figures 1-4]. Transpetrous approach was used in one case of petroclival meningioma

Table 1: Classification of posterior fossa meningioma "Sekhar and Wright"

Type	Location	Anatomical extension
I	Cerebellar convexity, lateral tentorial	Tentorium, transverse and sigmoid sinus
II	CP angle	Petrous ridge, IAC
III	Jugular foramen	Cerebello-medullary angle, internal jugular vein, extracranial
IV	Petro clival	Upper 2/3rd clivus, cavernous sinus, meckles cave, petrous ridge
V	Foramen magnum	Lower 1/3rd Clivus and C1, C2 Area
VI	Unclassified	Entire clivus, mid and lower clivus and other types

Table 2: Lists the different clinical features in the cases of posterior fossa meningiomas

Clinical presentations	No. of patients (*n*=32)	%
Hearing loss/Tinnitus	34	53
Headache	32	50
Ataxia	30	46
Trigeminal anaesthesia/Neuralgia	24	37
Dysphonia-dysphagia	10	15
Facial palsy	8	12
Diplopia	6	9

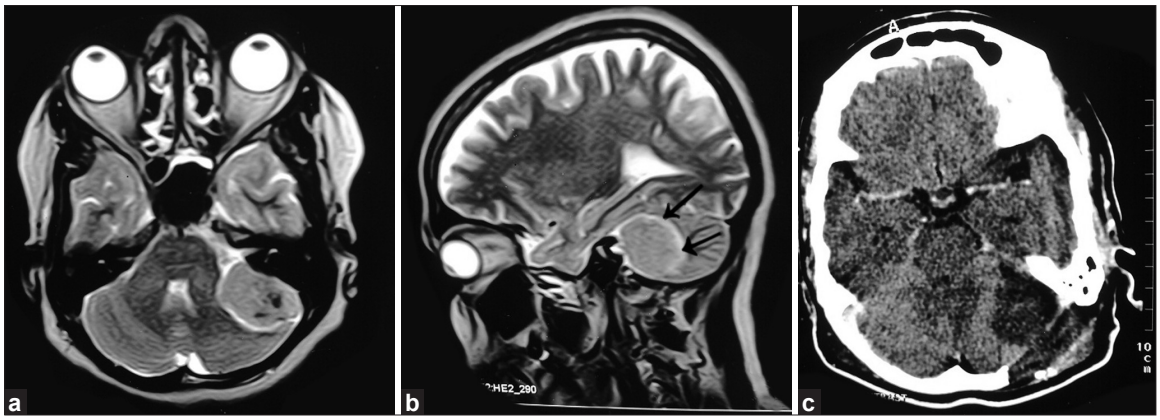

Figure 1: Left lateral petrous meningioma with postoperative CT scan s/o retromastoid craniectomy defect with gross total excision of lesion

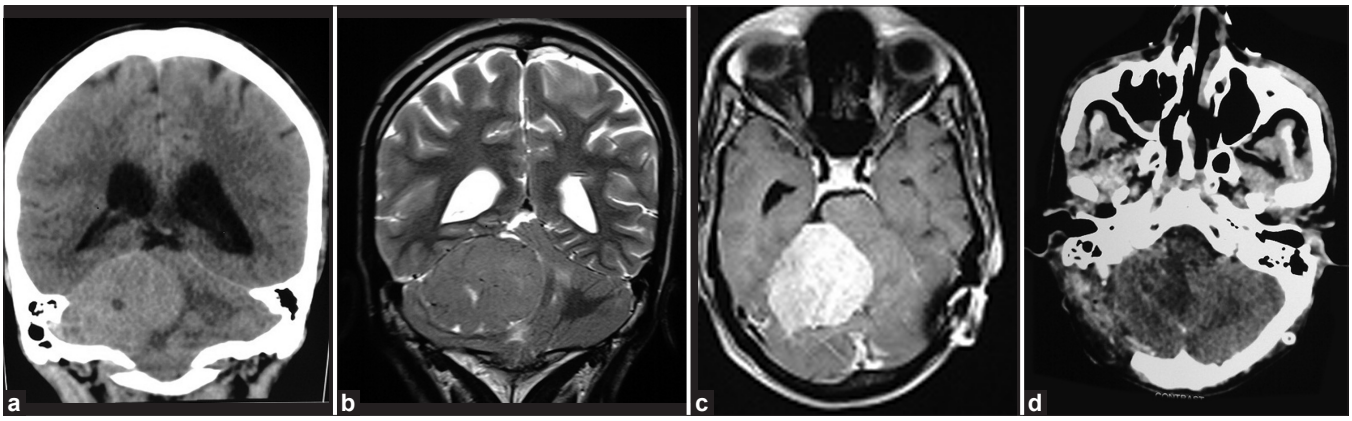

Figure 2: Right CP angle meningioma with post operative CT scan s/o retromastoid craniectomy defect with gross total excision

because the tumor was extending into the petrous bone with profound hearing loss in the patient.

Midline suboccipital craniectomy with C1 laminectomy was performed in cases of the foramen magnum meningioma [Figure 5] except two ventral foramen magnum meningiomas where far lateral approach was taken to excise the tumor [Figure 6]. Among 64 cases of posterior fossa meningiomas gross total excision was achieved in 46 cases (72%), in rest of the cases either subtotal excision (>90%), or partial excision (<90%) was done due to adhesion to nerves, vessels, brain stem or intrasinus extensions. Gross total excision was maximum in cerebellar convexity subgroup and was minimum in petroclival group [Table 3].

Postoperatively, patients developed complications in the form of cranial nerve dysfunction, CSF leakage, long tract signs, sinus thrombosis, stupor and coma. Cranial nerve dysfunction was found in 14 cases (21%) which was either aggravation

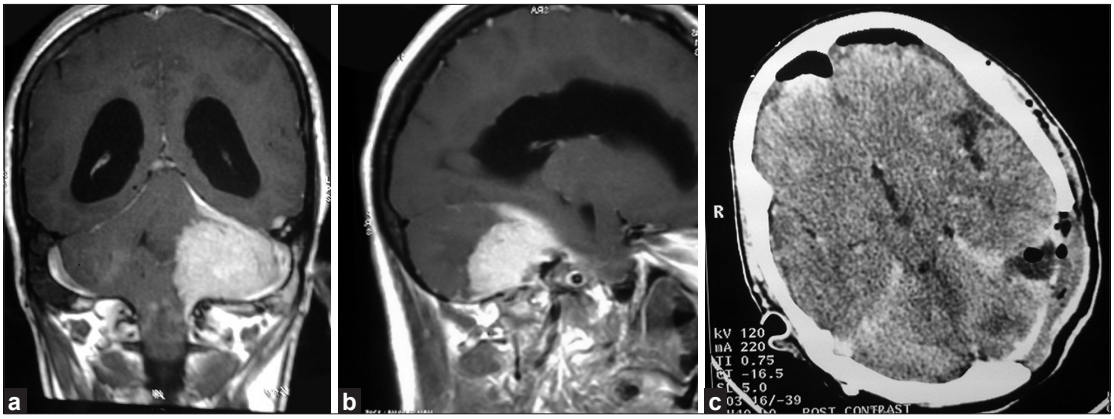

Figure 3: (a and b) Left tentorial meningioma preoperative and (c) postoperative images

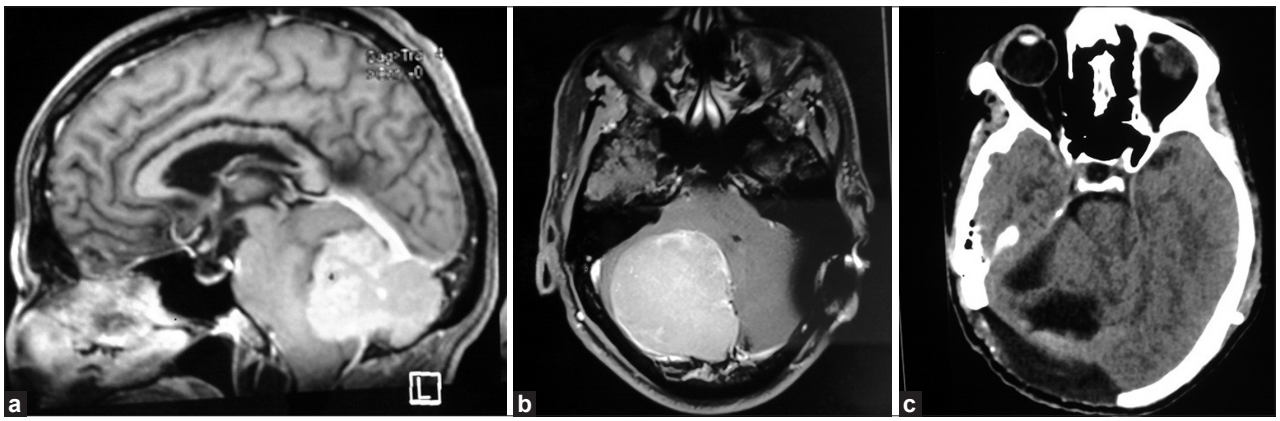

Figure 4: Tentorial meningioma with postoperative CT scan

Table 3: Lists the number of cases of various subgroups of posterior fossa meningioma, the approach taken for their surgery and extent of excision

Tumor locations	No. of cases (*n*=64)	Surgical approaches	Extent of excision	
			Gross total	Subtotal/Partial
CP angle meningioma	20 (31.2)	Retromastoid suboccipital craniectomy – all cases	14	6
Petroclival	12 (18.8)	Retromastoid suboccipital craniectomy - 11 cases Transpetrous approach- 1 case	8	4
Lateral tentorial	8 (12.5)	Retromastoid suboccipital craniectomy- all cases	4	4
Cerebellar convexity	8 (12.5)	Subocccipital craniectomy- all cases	8	–
Jugular foramen	4 (6.3)	Retromastoid suboccipital craniectomy- all cases	4	4
Foramen magnum	8 (12.5)	Midline suboccipital craniectomy ± C1 laminectomy - 6 Cases Far lateral approach -2 Case	6	2
Unclassified	4 (6.3)	Retromastoid suboccipital craniectomy- all cases	2	2

Figures in parenthesis are in percentage

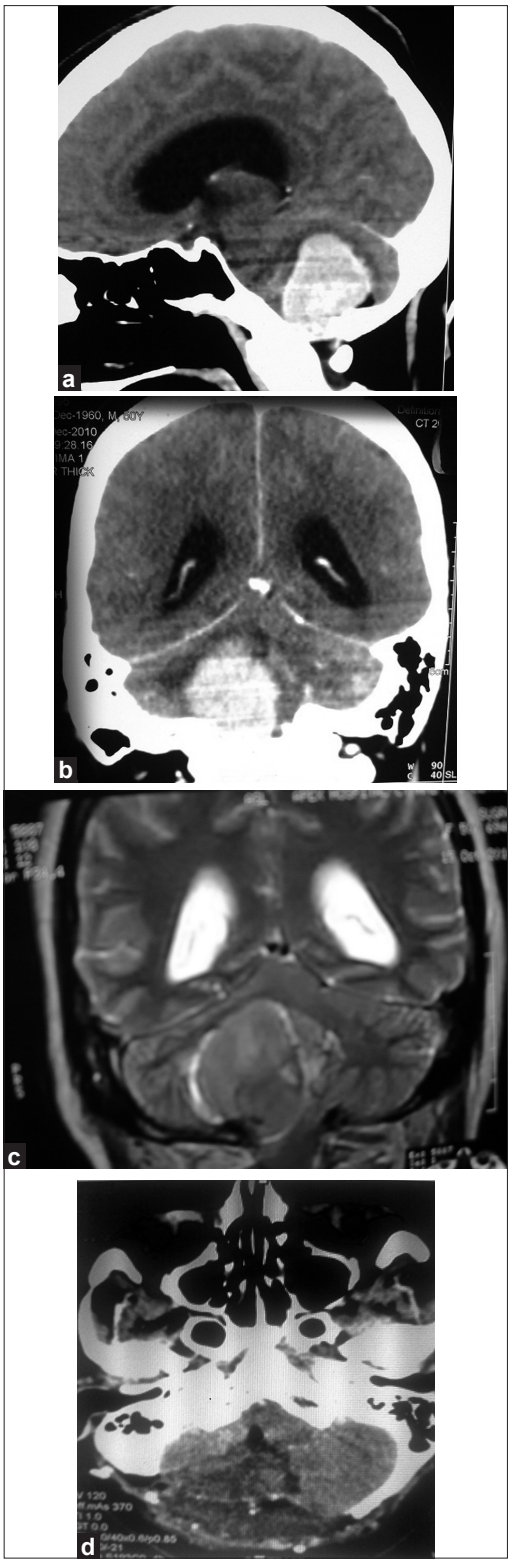

Figure 5: Dorsal foramen magnum meningioma with post op CT scan s/o suboccipital craniectomy defect with gross total excision

of previous dysfunctions or new dysfunction. Cranial nerve deficit was commonest in petroclival subgroup. Second commonest complication was CSF leakage, found in 12.5 % cases. Postoperative mortality noted in two cases (3.2%)

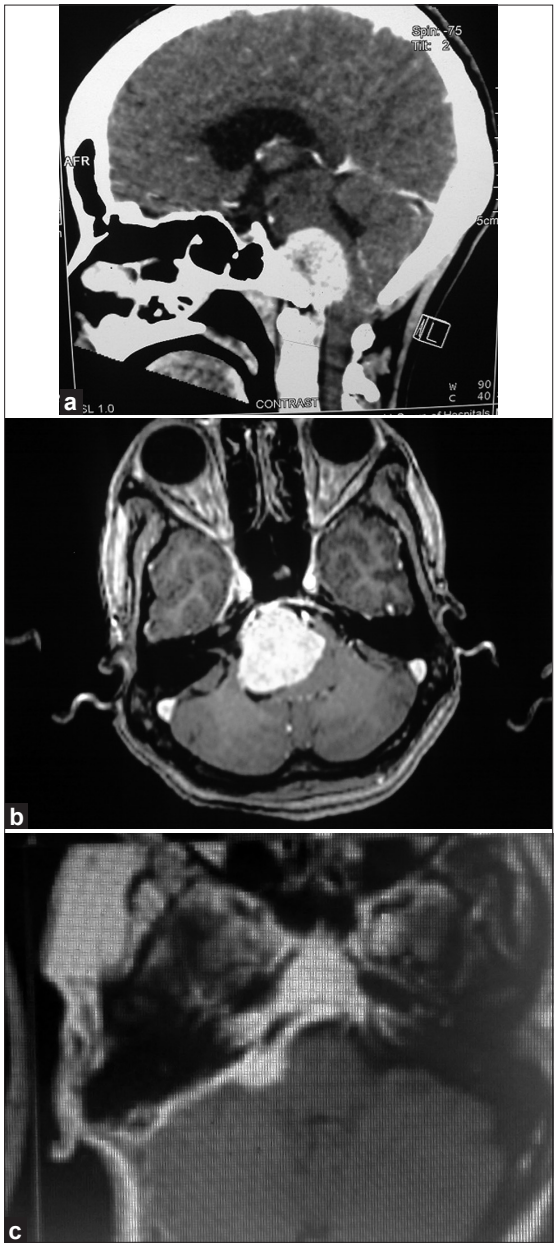

Figure 6: Ventral foramen magnum meningioma with post op MRI s/o residual adherent to cranial nerves

due to sinus thrombosis in one case and in other because of postoperative pneumonitis and septicemia. We encountered recurrence in total 10 cases of various subgroups over average follow up of 4 years.

Technical difficulties encountered during operating posterior fossa tumors and the measures to overcome

Sinus infiltration

Sinus infiltration is found commonly in the tentorial and jugular foramen meningioma. In the cases of tumor infiltration with partially patent sinus, leaving behind the intrasinus part with adjuvant radiosurgery or follow-up with plan of re-excision at later date when sinus will be

completely blocked was planned as per discussion with family.

Vascularity

Surgical approach was planned to address the tumor attachment first. Digital subtraction angiography with embolization was not performed in any of the case.

Large size and trajectory through cranial nerves and vessels

Internal debulking of the tumor gave enough of the space to work in between the nerves and vessels.

Adhesions to cranial nerves, vessels and brain stem

Preservation of arachnoid plane, copious saline wash instead of coagulation, avoiding traction, and use of intraoperative neurophysiologial monitors.

Loss of tumor – brain interface

In some of meningiomas (atypial and malignant subtype) breech in arachnoid and infiltrated in brain parenchyma was noted. In these invasive meningiomas, we took great care while dissection, avoided disrupting the small vessels and remained on tumor's immediate surface.

Discussion

Posterior fossa meningiomas can be found anywhere in posterior fossa and individualized management recommendations depend primarily on size, growth rate, clinical presentations and location. These tumors are classified by their anatomical origin given by Sekhar and Wright [Table 1].[4]

In classical series of Yassargil *et al*, 30% posterior fossa meningioma were located in CP angle region while 20% in Petroclival region, in our study CP angle meningioma subgroup was commonest (31.4%) followed by lateral tentorial and cerebellar subgroup.[6]

Despite the advent of CT scan and MRI studies, many of these tumors continue to be diagnosed too late due to indolent growth pattern.[7] Cranial nerve dysfunction and gait disturbance are the most common presenting symptoms, and involvement of V and VIII nerves is more frequently found in these tumors. Features of raised ICP due to hydrocephalus may be presenting symptoms in certain subgroup of posterior fossa meningioma.

High–field thin section MRI is very useful for planning the surgical approach as it provide the information about the site of origin and secondary tumor extensions either intra or extradural, the interface between the tumor and the brain surface, relationships of the lesion and cranial nerves and the major vessels.[8-10] The point of skull attachment is indicated by osseous reaction appreciated better with CT scan brain.[10]

MRI angiography technique is substituting conventional cerebral angiography in the study of skull base meningiomas. Although it has been argued that embolization makes the tumor softer and less vascular, we did not perform preoperative embolization in our series because intratumoral embolization of feeders from ICA and meningeal branches of ECA are difficult and the procedure have its own morbidity of lower cranial nerve damage and brain ischemia.[11]

MR venography done to demonstrate the venous sinus infiltration, venous anatomy with dominance of the transverse and sigmoid sinuses, the size of the jugular bulb, superior and inferior petrosal sinuses and temporal lobe drainage pattern.

There are four therapeutic options for posterior fossa meningiomas 1) Observation 2) Surgical resection 3) Radiotherapy or radiosurgery 4) Combination of surgery and radiosurgery.

Observation is selected when patient is neurologically intact, the lesion is small and especially if the patient is elderly or has significant co morbidities. MRI imaging every 6-12 months interval is recommended and if the lesion grows more than couple of millimetre in 6-month interval surgical treatment would be judicious.

Microsurgical excision is the main treatment in the cases of posterior fossa meningioma especially if the patient is young with tumor larger than 3 cm in diameter, with neurological symptoms or the asymptomatic patient with preference for removal.

The general concept that is important for the successful removal of the posterior fossa meningioma include adequate bony exposure, early eradication of vascular supply, debulking of the tumor mass and maintenance of arachnoid plane. Surgical approaches for posterior fossa meningiomas depend on aim of the surgery, locations, dural attachment, extension of tumor, preference and familiarity of the neurosurgeon.[12-14]

As in other series, the surgical approach most commonly used by us was the lateral suboccipital retromastoid craniectomy which is suitable not only for small and medium-sized tumors, but also for large one, even if the tumor involves the upper clivus and tentorial notch. Through this familiar approach the surgeon finds the posterior and laterally displaced or engulfed cranial nerves and the brainstem in the way to the tumor and he has to work through the narrow fissure left between the tentorium and cranial nerves; however, because of the large size and lateral extension of the tumor the exposure is usually good, and allows complete removal as progressive tumor hollowing and shrinking provide the room needed for reaching the far limits without additional retraction of the brain stem and cranial nerves.[15,16] The presigmoid approach is a good option in microsurgical excision of the petroclival and premeatal CP angle meningiomas as it allows the surgeon

to work approximately 2 cm closer to tumor than would be possible through retromastoid approach and to remain in front of the brain stem. But in recent studies radical excision of the petroclival meningiomas by using presigmoid approach was equal to conventional retromastoid suboccipital craniectomy; operation took longer time and carried more complications such as CSF leak and hearing loss [Table 4].[17]

Surgical results with skull base meningiomas have improved during the last two decades, but radical excision continues to produce high morbidity rate and occasional mortality.[23,24] Postoperative complications are comparatively higher in the subgroup with petroclival meningiomas which in experienced hands are completely removed in only 53-79% of the cases. Hakuba *et al* reported 17% mortality and new neurological deficit in 83% cases, Mayberg and Symon reported 9% mortality with 50% permanent morbidity rates.[23,24] Sekhar *et al* achieved complete tumor removal in 73% cases with operative mortality in 4% cases.[4] As with others in our series the rate of complete excision and postoperative neurological deficit were better with CP angle meningioma in comparison to petroclival meningioma. Over all we achieved 72% gross total excision with new or aggravation of existing neurological deficit in 33% cases. Partial excision or subtotal excision were more in petroclival, jugular foramen with extracranial extension, tentorial with intrasinus extension and ventral foramen magnum meningiomas in our series [Table 5].

Table 4: List the common surgical approach options in various subgroups of the posterior fossa meningiomas with their advantage and disadvantage

Location	Common surgical approaches advantage	Advantages	Disadvantage
Petroclival[15,18,19]	Retromastoid craniotomy	Simplicity and familarity of approach to neurosurgeons	Working between the neurovascular structure
		Provides a wide exposure of the CPA structures	Retraction of cerebellum is required in large tumors [2]
		Generous drainage of the CSF at the beginning of the intervention by opening the cisterna magna usually avoids cerebellar retraction	
		Possibility of hearing preservation	
		Less morbidity in comparison to other extensive skull base approaches[1]	
	Petrous craniotomy ± anterior petrosectomy	Shorter trajectory	Higher chances of cochlear damage so indicated only in cases with non serviceable hearing loss
		Direct approach to base of meningioma	Extensive
		No retraction of cerebellum required even in larger tumors	Higher chances of CSF leak and meningitis
Cerebello-pontine angle[18,19]	Retromastoid craniotomy	Simplicity and familarity of approach to neurosurgeons	Working tracjectory between the neurovascular structures
		Provides a wide exposure of the CPA structures	
		Generous drainage of the CSF at the beginning of the intervention by opening the cisterna magna usually avoids cerebellar retraction	
		Chance of hearing preservation	
		Less morbidity in comparison to other extensive skull base approaches	
	Translabrinthine craniotomy	Indicated in premeatal CPA meningioma (medial CP Meningioma)	Indicated only in cases with non serviceable hearing loss
		Short trajectory	Extensive
		Early exposure of facial nerve	Higher chances of CSF leak
Jugular foramen[20]	Retromastoid craniotomy	Good for intradural jugular meningioma part	Difficult to excise the extradural extension of tumor
	Transjugular variants	Postauricular transtemporal approach- for anterior extradural extension of the lesion	Working between the neurovascular structure so chances of lower cranial nerve deficit

Contiuned/-

Table 4: Contd/-

Location	Common surgical approaches advantage	Advantages	Disadvantage
		Preauricular subtemporal-infratemporal approach- Selected for tumors with extension along the petrous portion of the internal carotid artery, through the eustachian tube, or through the cancellous portion of the petrous apex	Extensive Venous plexsus injury and bleed
		Far lateral- for tumor with downward extension towards foramen magnum	Chances of injury to lower cranial nerves hearing impairment CSF leak
Foramen magnum[16,21]	Suboccipital craniotomy ± C1 laminectomy	Easier, safer,and quicker as compared with any anterior or lateral approach	Difficult in strictly ventral tumor
		No extensive drilling of the occipital condyle, lateral mass of the atlas so no possibility of injury to the hypoglossal nerve, vertebral artery and spinalinstability	Retraction on cerebellum
		The vertebral artery was exposed easily in the region of the arch of atlas so proximal control and mobilization possible	Extensive
		For ventro-lateral meningiomas	
	Far lateral approach	Wider corridor	Lower cranial nerve injury
		Less lower cranial nerve manipulation	Vertebral artery injury CVJ Instability
	Trans oral	Direct approach to meningioma base in ventral meningioma	High rate of CSF leak and meningitis Difficult to deal with lateral extension of the tumor Long working distance
Tentorial[22]	Retromastoid craniotomy	Simplicity and Familarity of approach to neurosurgeons	Difficult to deal intrasinus and supratentorial extension [Figure 7]
	Subtemporal craniotomy	Provides direct excess to base of the tumor and wide exposure	temporal lobe edema and venous injury
	Combined	Provide excess to supratentorial extension	
Cerebellar convexity	Suboccipital craniotomy	Easy, safe and with direct excess to base of tumor	Cerebellar edema Venous thrombosis

Table 5: Comparison of our study with earlier studies of posterior fossa meningioma

Studies	No. of cases	% Gross total resection	% CSF leak	% Over all complication	% Recurrence	% Mortality
Roberti *et al.*[4]	161	57	13.6	41	13.7	2.5
Saleh *et al.*[18]	40	97	5	54	nil	2.5
Lobato *et al.*[19]	80	62.5	2.5	67.5	28.7	6.2
Cudlip *et al.*[25]	52	84	4	54	21	11
Symon *et al.*[26]	73	78	4	72	*	9
Our study	64	72	12.5	45	15	3.2

*not mentioned

Subtotal excision carries lesser risk of complications than radical excision, but residual tumors may lead to recurrence sooner or later and reoperation is usually less successful and risky especially if radiation is given after the initial operation. At the present moment the majority of the authors recommend subtotal resection for old patients or when there are factors defying complete removal.[18,19]

Meningiomas may recur after an apparently radical excision, but it is clear that completeness of the resection is the main factor preventing regrowth in all locations. In various studies the rate of recurrence was five to ten times higher in the patients with subtotal or partial excision compared from radical excision. In the series of Couldwell *et al* in which gross total excision was achieved in 69% of the patients, 13% had

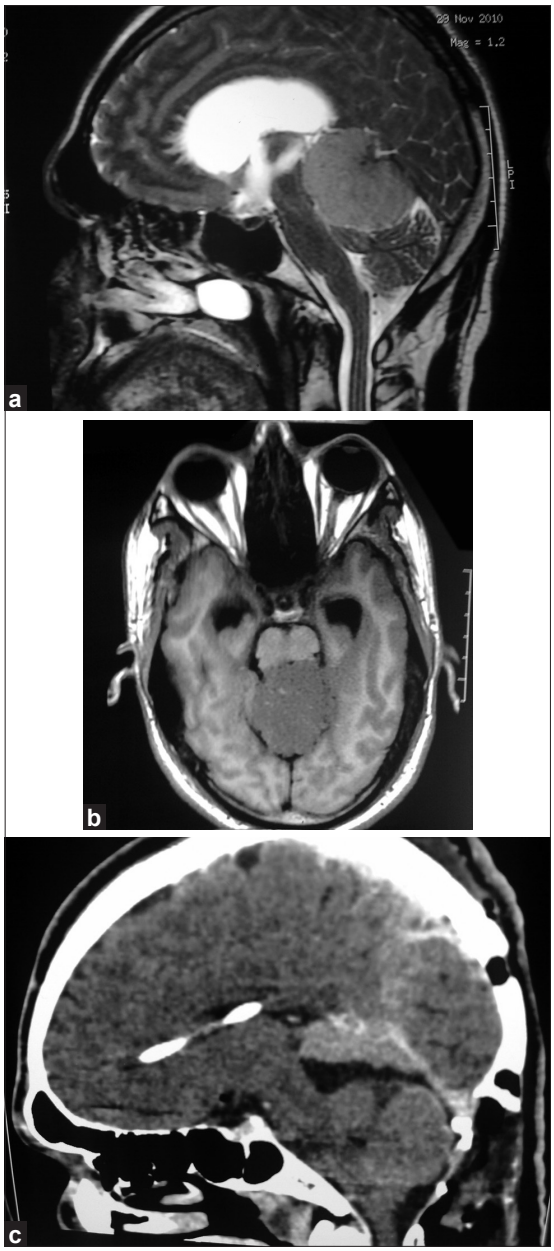

Figure 7: Tentorial meningioma with post op CT scan s/o residual adherent to deep veins

documented recurrence or progression over 6.1 year follow-ups.[27] In our series, we have recurrence of total 10 cases (16%) over the average follow-up of 4 years. Most of the recurrent cases were seen in petroclival and tentorial subgroups with partial or subtotal excision.

The critical issue of identifying the factors influencing the possibility of radical and safe excision is tumor-vascular relationships, the integrity of the arachnoid plane between tumor and brain stem, tumor consistency and vascularity. Levine *et al* have proposed a grading system for predicting the likelihood of complete resection of basal meningiomas, which includes radiotherapy, vessels encasement and number of cranial nerves involved. Preoperative MRI T2-weighted higher intensity images are associated with increase tumor vascularity, softer tumor consistency and histological aggressiveness.[9]

As subtotal resection is associated with higher chance of tumor recurrence addition of radiosurgery as a secondary treatment modality has been studied. Stereotactic radiosurgery provides a conformal, highly focused, single fraction radiation field essentially confined to the tumor, which may reduce the incidence of complications that are associated with fractionated radiation therapy. The goals of radiosurgery are to prevent tumor progression, prolong the interval to recurrence and improve survival.[28]

A combination of surgical resection and radiosurgery for the management of many of these patients has been considered in studies. Taylor *et al* determined a 10-year progression-free survival rate in cases of subtotal, gross total and subtotal plus radiosurgery subgroups of meningioma and found that recurrence was very high in subtotal subgroup but was same in gross total and subtotal plus radiosurgery subgroups. In this way the surgeon can remove the bulk of the tumor and residual lesion can be treated with radiosurgery but the benefit is limited as tumor volumes increases.[29]

Conclusions

- Posterior fossa meningioma are difficult to excise due to close relation to cranial nerves and vessels
- The use of microscope, CUSA, intraoperative nerve monitor help in removal and preserving surrounding important anatomical structures
- Although neurological deterioration is common postoperatively, recovery does occur completely after total removal thus increasing the recurrence free period and improving the outcome.

References

1. Castellano F, Ruggiero G. Meningiomas of the posterior fossa. Acta Radiol suppl 1953;104:1-177.
2. Laird FJ, Harmer SG, Laws ER, Reese DF. Meningiomas of the cerebellopontine angle. Otolaryngol Head Neck Surg 1985;93:163-7.
3. Rock JP, Ryu S, Anton T. Posterior fossa meningioma. In: Schmidek HH, Roberts DW, editors. Operative neurosurgical techniques indication, methods, and results. 5th ed. Philadelphia: Elsevier; 2006. p.851-71.
4. Roberti F, Sekhar LN, Kalavakonda C, Wright DC. Posterior fossa meningiomas: surgical experience in 161 cases. Surg Neurol 2001;20:20-31.
5. Sekhar LN, Jannetta PJ. Cerebellopontine angle meningiomas: Microsurgical excision and follow-up results. J Neurosurg 1984;60:500-5.
6. Yasargil MG, Mortara RW, Curcic M. Meningiomas of basal posterior cranial fossa. In: Krayenbuhl K, Editor, Advances and Technicalstandards in neurosurgery. Wien: Springer Verlag; 1980. p. 3-115.
7. Bricolo AP, Turazzi S, Talacchi A, CristoFori L. Microsurgical removal of petroclival meningioma: A report of 33 patients. Neurosurgery 1992;31:813-28.
8. Canvalho GA, Marthles C, Tatagiba M, Eghhal, Samii M. Impact of computed tomography and maganetic resonance imaging findings

on surgical outcome in petroclival meningioma. Neurosurgery 2000;47:1287-94.
9. Levine ZT, Buchana I, Sekhar LN, Rosen CL, Wright DC. Proposed grading system to predict extent of resection and outcome for cranial base meningioma. Neurosurgery 1999;45:221-30.
10. Helie O, Soulie D, Sarrazin JL, Dewrosier C, Cordoliani YS, Cosnard G. Magnetic resonance imaging and meningioma of posterior cerebral fossa, 31 cases. J Neuroradiol 1995;22:252-70.
11. Rosen CL, ammerman JM, Sekhar LN, Bank WO. Outcome analysis of preoperative embolization in cranial base surgery. Acta Neurochir 2002;144:1157-64.
12. Al-Mefty, Fox SL, Smith RR. Petrosal approach for petroclival meningioma. Neurosurgery1988;22:510-7.
13. Spallone A, Makhmudov UB, Mukhamedjanov DJ, Tcherekajev VA. Petroclival meningioma An attempt to define the role of skull base approach in their surgical management. Surg Neurol 1999;51:412-9.
14. Spezler RF, Daspit CP, Pappas CT. The combined supra and infratentorial approach for lesion of petrous and clival region: Experience with 46 cases. J Neurosurg 1992;76:588-99.
15. Samii M, Tatagiba M. Experience with 36 surgical cases of petroclivalmeningiomas. Acta Neurochir 1992;118:27-32.
16. Goel A, Desai K, Muzumdar D. Surgery on anterior foramen magnum meningiomas using a conventional posterior suboccipital approach: A report on an experience with 17 cases. Neurosurgery 2001;49:102-6.
17. Chen CM, Huang AP, Kuo LT, Tu YK. Contemporary surgical outcome for Skull base meningiomas. Neurosurg Rev 2011;34:281-96.
18. Saleh EA, Taibah AK, Achilli V, Aristegui M, Mazzoni A, Sanna M. Posterior Fossa Meningioma Surgical Strategy. Skull Base Surg 1994;4:202-12.
19. Lobato RD, Gonzaáez P, Alday R, Ramos A, Lagares A, Alen JF, et al. Meningiomas of the basal posterior fossa. Surgical experience in 80 cases. Neurocirugia 2004;15:525-42.
20. Katsuta T, Rhoton AL Jr, Matsushima T. The Jugular Foramen: Microsurgical Anatomy and Operative Approaches. Neurosurgery 1997;41:149-202.
21. Margalit NS, Lesser JB, Singer M, Sen C. Lateral approach to anterolateral tumors at the foramen magnum: Factors determining surgical procedure. Neurosurgery 2005;56:324-36.
22. Shukla D, Behari S, Jaiswal AK, Benarji D, Tyagi l, Jain VK. Tentorial meningiomas: Operative nuances and perioperative management dilemmas. Acta Neurochir (Wein) 2009;151:1037-51.
23. Hakuba A, Nishimura S, Tanaka K, Kishi H, Nakamura T. Clivus Meningioma,: Six cases of total removal. Neurol med Chir 1977; 17:63-77.
24. Mayberg MR, Symon L. Meningiomas of the clivus and apicalpetrous bone: Report of 35 cases. J Neurosurg 1986;65:160-7.
25. Cudlip SA, Wilkin PR, Johnston FG, Moore AJ, Marsh HT, Bell BA. Posterior Fossa Meningiomas: Surgical Experience in 52 Cases. Acta Neurochir (wein) 1998;140:1007-12.
26. Symon L, Pell M, Singh L. Surgical management of posterior cranial fossa meningiomas. Br J Neurosurgery 1993;7:599-609.
27. Coudwell WT, Fukushima T, Giannotta SL, Weiss MH. Petroclival meningioma, Surgical experience in 109 cases. J Neurosurgery 1996;84:20-8.
28. Subach BR, Lunsford LD, Kondziolka D, Maitz AH, Flickinger JC. Management of petroclival meningiomas by stereotactic radiosurgery. Neurosurgery 1998;42:437-43.
29. Taylor BW, Marcus RB, Friedman WA, Ballinger WE, Million RR. The meningioma controversy: Postoperative radiation therapy. Int J Radiat Oncol Biol Phys 1988;15:299-304.

How to cite this article: Velho V, Agarwal V, Mally R, Palande DA. Posterior fossa meningioma "our experience" in 64 cases. Asian J Neurosurg 2012;7:116-24.

Source of Support: Nil, **Conflict of Interest:** None declared.