

Case report

Giant Schmorl's Node may Cause High Uptake and Mimic a Bone Metastasis on ^{18}F -Choline Positron Emission Tomography/Computed Tomography

Gabriele Masselli, Riccardo Monti, Marianna Guida, Gianfranco Gualdi

Department of Radiology, Umberto I Hospital, Sapienza University, Rome, Italy

Abstract

Bone metastasis in prostate cancer are detected by choline positron emission tomography/computed tomography (PET/CT) with high sensitivity and specificity. We report the case of a patient with previous prostatectomy for prostate cancer who underwent F-choline PET/CT for a recent increased of prostate-specific antigen value and showed focal vertebral uptake suggestive for skeletal metastasis; magnetic resonance imaging revealed unexpectedly a Schmorl's node (SN). False positives on choline PET-CT caused by SN has not been reported in the literature and the present case highlights that this possibility should be considered in case of choline vertebral increased uptake in the patient with prostate cancer.

Keywords: Bone metastasis, F-choline positron emission tomography/computed tomography, prostate cancer, Schmorl's node

Introduction

Choline positron emission tomography (PET) imaging has been proposed to early detect primary prostate cancer, to stage the tumor, mainly for the identification of nodal involvement, and finally for the detection of tumor recurrence in case of biochemical relapse because choline kinase activity is substantially up regulated in tumor cells.^[1-3]

Schmorl's nodes (SNs) were first described by the pathologist Christian Georg Schmorl in 1927 as a herniation of nucleus pulposus through the cartilaginous and bony endplate into the body of an adjacent vertebra.^[4]

We report the case of a patient with the previous prostatectomy for prostate cancer who underwent F-choline PET/computed tomography (CT) for a recent increased of prostate-specific antigen (PSA) value

and showed focal vertebral uptake typical of skeletal metastasis; the next magnetic resonance imaging (MRI) revealed unexpectedly an SN.

Case Report

A 75-year-old-man, with previous 4-year-old prostatectomy for prostate adenocarcinoma, because of recent increased PSA value (0.8 ng/ml), underwent to ^{18}F -fluorocholine PET/CT.

^{18}F -choline PET/CT demonstrated a focal site of increased uptake (SUV max 7) at level of D12 inferior vertebral plate, where CT imaging showed a lytic lesion. The scanning did not reveal abnormal ^{18}F -choline avid activity in the pelvic cavity, or other pathological increased radiotracer uptake have been detected in the skeleton [Figure 1a-1c].

For the discrepancy between the lytic nature of the lesion and the uptake of the PET/CT, the patient underwent to MRI with intravenous gadolinium to obtain a further characterization of the lesion.

Magnetic resonance imaging showed a large extension of the nucleus pulposus into the vertebral body of D12 with low signal intensity on T1-weighted and peripheral

Access this article online

Quick Response Code:



Website:
www.wjnm.org

DOI:
10.4103/1450-1147.154233

Address for correspondence:

Dr. Gabriele Masselli, Department of Radiology, Umberto I Hospital, Sapienza University, Viale del Policlinico 155, 00161 Rome, Italy.
E-mail: g.masselli@policlinicoumberto1.it

enhancement after gadolinium administration; T2-weighted images demonstrated high signal intensity of the vertebral body marrow around caused by edema; these findings are characteristic of a bulky SN in acute phase [Figure 1d-1f].

Discussion

Schmorl's node are protrusions of disc materials into the surface of the vertebral body, which may contact the marrow of the vertebra and lead to inflammation, resulting in increased fluorodeoxyglucose (FDG) activity, and it is widely demonstrated in the literature as false positives at FDG PET/CT images.^[5]

Monitoring PSA serum level is the best approach to follow prostate cancer patients after treatment and to detect early recurrence. In the case of PSA relapse, imaging should be able to distinguish between local recurrence and distant metastasis and to establish a correct therapy. The study of tissue metabolism using PET/CT could play an important role in this context especially in the detection of lymph node and distant metastasis and in characterizing images which are questionable or difficult to interpret on conventional imaging modalities.^[1,6]

Vertebral increased activity on choline PET/CT in patients with prostate cancer history is indicative for bone metastasis. The sensitivity, specificity, and accuracy of F-choline PET/CT in the detection of bone metastasis in prostate cancer are 74%, 99%, and 85%, respectively.^[7]

False positives caused by SN has not be reported in the literature to our knowledge; our case points out that SN

can cause increased uptake on ¹⁸F-choline PET/CT and can represent a pitfall in patients with prostate cancer history because it shows the same high uptake of bone metastasis.

Magnetic resonance imaging is the most sensitive noninvasive procedure for imaging acute-stage SNs. Magnetic resonance can show loss of signal intensity in the affected intervertebral disk space, the herniated fragment of the nucleus pulposus in some cases, and signal changes in the underlying cancellous bone of the vertebral body, with low signal intensity on T1-weighted images and high signal intensity on T2-weighted images. These features are due to inflammation decreasing in 3–12 months.^[8-10]

Consistency

Our case draws nuclear medicine physician's attention to the possible false positive results of bone F-choline PET/CT in patients with prostate cancer history because it may lead to inappropriate staging.

References

1. Fuccio C, Rubello D, Castellucci P, Marzola MC, Fanti S. Choline PET/CT for prostate cancer: Main clinical applications. *Eur J Radiol* 2011;80:e50-6.
2. Ackerstaff E, Pflug BR, Nelson JB, Bhujwalla ZM. Detection of increased choline compounds with proton nuclear magnetic resonance spectroscopy subsequent to malignant transformation of human prostatic epithelial cells. *Cancer Res* 2001;61:3599-603.
3. Sutinen E, Nurmi M, Roivainen A, Varpula M, Tolvanen T, Lehtikoinen P, et al. Kinetics of [(11) C] choline uptake in prostate cancer: A PET study. *Eur J Nucl Med Mol Imaging* 2004;31:317-24.
4. Mattei TA, Rehman AA. Schmorl's nodes: Current pathophysiological, diagnostic, and therapeutic paradigms. *Neurosurg Rev* 2014;37:39-46.
5. Lin CY, Chen HY, Ding HJ, Chen YK, Kao CH. Evaluation of Schmorl's nodes using F-18 FDG PET/CT. *Clin Radiol* 2012;67:e17-21.
6. Hodolic M. Role of (18) F-choline PET/CT in evaluation of patients with prostate carcinoma. *Radiol Oncol* 2011;45:17-21.
7. Igerc I, Kohlfürst S, Gallowitsch HJ, Matschnig S, Kresnik E, Gomez-Segovia I, et al. The value of ¹⁸F-choline PET/CT in patients with elevated PSA-level and negative prostate needle biopsy for localisation of prostate cancer. *Eur J Nucl Med Mol Imaging* 2008;35:976-83.
8. Stähler A, Bellan M, Weiss M, Gärtner C, Brossmann J, Reiser MF. MR imaging of enhancing intraosseous disc herniation (Schmorl's nodes). *AJR Am J Roentgenol* 1997;168:933-8.
9. Smith DM. Acute back pain associated with a calcified Schmorl's node: A case report. *Clin Orthop Relat Res* 1976:193-6.
10. Seymour R, Williams LA, Rees JL, Lyons K, Lloyd DC. Magnetic resonance imaging of acute intraosseous disc herniation. *Clin Radiol* 1998;53:363-8.

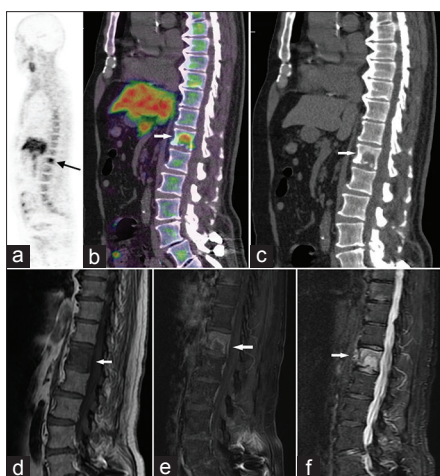


Figure 1: Whole body ¹⁸F-choline positron emission tomography/computed tomography (CT) showed on sagittal images (a, b) a focal site of increased tracer uptake (SUV max 7) on D12 inferior vertebral plate, where CT imaging (c) showed a lytic lesion. Magnetic resonance imaging sagittal sequences showed a nucleus pulposus herniation through the vertebral body of D12 with low signal intensity on T1-weighted and peripheral enhancement after gadolinium administration (d, e); T2-weighted images (f) demonstrated high signal intensity of the vertebral body marrow around caused by edema as seen in Schmorl's node in acute phase

How to cite this article: Masselli G, Monti R, Guida M, Gualdi G. Giant Schmorl's Node may Cause High Uptake and Mimic a Bone Metastasis on ¹⁸F-Choline Positron Emission Tomography/Computed Tomography. *World J Nucl Med* 2015;14:140-1.

Source of Support: Nil. **Conflict of Interest:** None declared.