

Case report

Primary Retroperitoneal Seminoma Staging and Surveillance by Means of Fluoro-2-Deoxyglucose-Positron Emission Tomography/Computed Tomography

Tianye Liu, Carina Mari Aparici¹

Department of Radiology and Biomedical Imaging, University of California, ¹Department of Radiology and Nuclear Medicine, VA Medical Center, San Francisco, USA

Abstract

Primary retroperitoneal seminoma is a very rare entity. We present a case of 39-year-old male with primary retroperitoneal seminoma with staging and surveillance by means of F-18 fluoro-2-deoxyglucose-positron emission tomography/computed tomography (FDG-PET/CT). The case demonstrates that primary retroperitoneal seminoma can be easy to identify with FDG-PET/CT and potential follow-up on recurrence, or metastatic disease can be performed using this technique.

Keywords: 18 fluoro-2-deoxyglucose, retroperitoneal, seminoma

Introduction

Primary retroperitoneal seminoma is a very rare entity.^[1] Unlike metastatic seminoma to the retroperitoneum, primary retroperitoneal seminoma occurs without confirmation of the presence of a primary malignancy in the testes. Very few cases of such extragonadal retroperitoneal germ cell tumor without involvement of the testes have been reported. Although the condition has been described before, there has been no reported case in which primary retroperitoneal seminoma was characterized by 18 fluoro-2-deoxyglucose-positron emission tomography/computed tomography (FDG-PET/CT). We present a case of 39-year-old male with primary retroperitoneal seminoma with staging and surveillance by means of FDG-PET/CT.

Case Report

A 39-year-old man was awakened by a sudden onset of abdominal pain during sleep. He presented to the emergency room where an abdominal/pelvic CT showed a bulky 8 cm × 7 cm retroperitoneal mass next to the left kidney. Scrotal ultrasound 2 days later did not show evidence of testicular masses or any other abnormalities. A subsequent FDG-PET/CT [Figure 1] showed a hypermetabolic 8 cm × 7 cm retroperitoneal mass with a maximum standardized uptake value (SUV_{max}) of 22 and mild asymmetric FDG activity in the right testis with SUV_{max}: 4.46. Subsequent radical resection of the retroperitoneal mass was complicated by left renal vein injury due to tumor invasion. The estimated blood loss was 2 L and the left renal vein was ligated to stop bleeding. The final pathology revealed that the mass had characteristics consistent with seminoma with margin <0.05 cm, and it was unable to determine whether the tumor was primary or metastatic. An FDG-PET/CT 2 weeks after surgery [Figure 2] showed postoperative changes without convincing evidence of residual disease or metastases, as well as interval improvement of the asymmetric mild FDG activity seen before within the testis.

Access this article online

Quick Response Code:



Website:
www.wjnm.org

DOI:
10.4103/1450-1147.153910

Address for correspondence:

Mr. Tianye Liu, 185 Berry Street, Suites 190 and 180, Lobby 6, San Francisco, CA 94107, USA. E-mail: tianye.liu@ucsf.edu

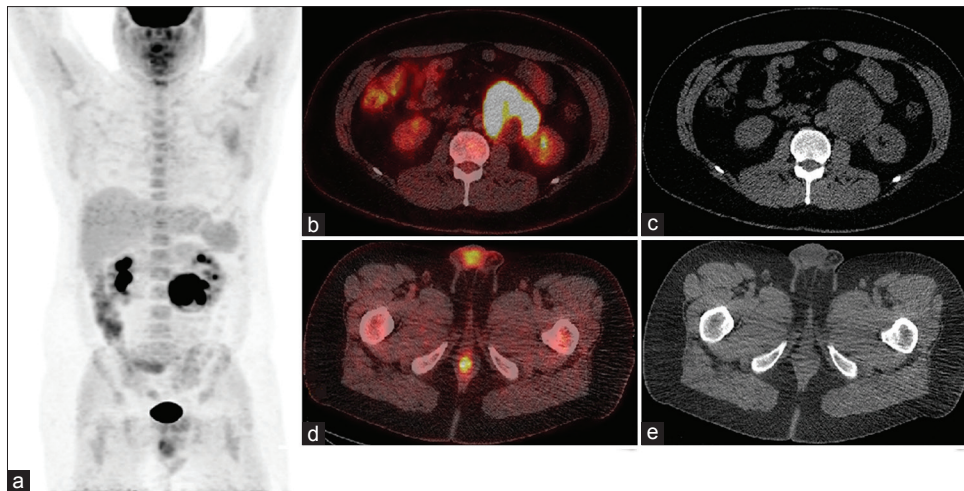


Figure 1: (a) 18 fluoro-2-deoxyglucose-positron emission tomography/computed tomography (FDG-PET/CT) maximum intensity projection image showing intensely hypermetabolic retroperitoneal mass maximum standardized uptake value ([SUVmax]: 22) and mild asymmetric FDG activity in the right testis with (SUVmax: 4.4). (b) Axial hybrid PET/CT showing high FDG activity in the retroperitoneal mass. (c) Computed tomography attenuation correction (CTAC) image showing the same mass. (d) Axial hybrid PET/CT showing mild FDG activity in the right testis. (e) CTAC image of the same axial cut

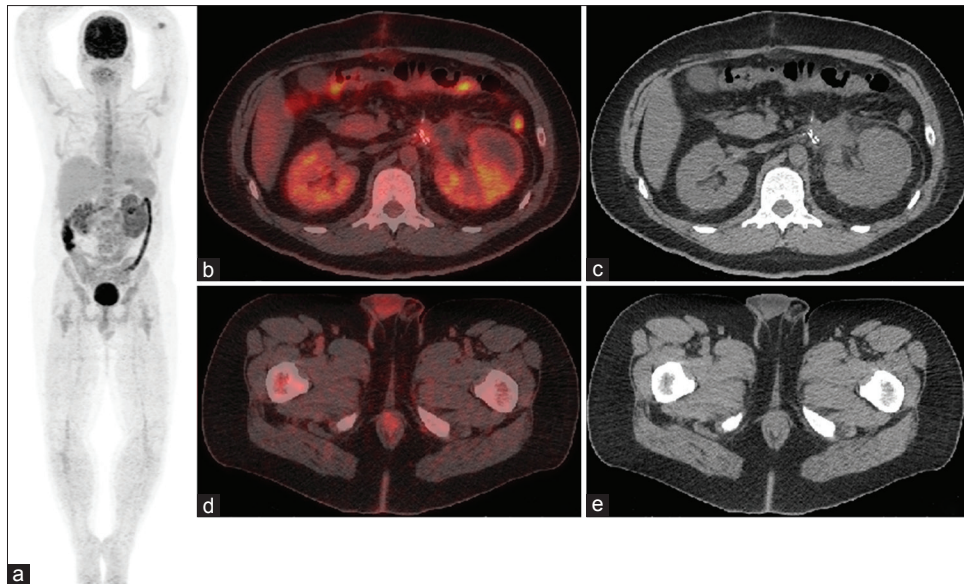


Figure 2: (a) 18 fluoro-2-deoxyglucose-positron emission tomography/computed tomography (FDG-PET/CT) maximum intensity projection image weeks after surgery. (b) Axial hybrid PET/CT of the region that previously showed high FDG activity in the retroperitoneal mass. (c) Corresponding computed tomography attenuation correction (CTAC) image. (d) Axial hybrid PET/CT showing decreased FDG activity in the right testis after surgery. (e) Corresponding CTAC image

Discussion

Primary retroperitoneal seminoma is a rare entity that accounts for approximately 2% of all seminomas.^[1] The origin of extragonadal retroperitoneal germ cell tumors is controversial. One of the theories suggests that the tumors originate embryologically from displaced germ cells situated along the midline of the body.^[2] Another explanation suggests that these tumors are metastatic lesions from spontaneously regressed (burned-out) testicular carcinomas.^[3,4] This is why in some cases, in spite of negative imaging, elective orchiectomy is part

of the treatment plan of these patients, with most of the cases showing no significant evidence of the primary malignancy after pathology. In our case, pathology was unable to determine whether the tumor was primary or metastatic. The patient's scrotal ultrasound did not show evidence of testicular masses or other abnormalities. It is true that the staging FDG-PET/CT showed a mild diffuse testicular asymmetry, but the findings were not consistent with malignancy. In addition, the surveillance follow-up scan postresection of the retroperitoneal mass showed spontaneous improvement. Although primary retroperitoneal seminoma has been previously described

in the literature,^[5,6] to the best of our knowledge, this is the first case in which a primary retroperitoneal seminoma was characterized by FDG-PET/CT. Based on the experience with our patient, these tumors show high-FDG uptake (in our case SUVmax: 22) and, therefore, should be easy to identify and can be used to follow-up recurrence or metastatic disease. It would be interesting further to assess the meaning of the mild asymmetric FDG activity seen in the testis at the time of staging, and document if similar patterns happen in other cases of retroperitoneal seminoma assessed with FDG-PET/CT.

References

1. Walsh PC, Retik AB, Darracott Vaughan E, Wein AJ. Neoplasms of the testis. Campbell's Urology. 8th ed. London: WB Saunders; 2002.
2. Scholz M, Zehender M, Thalmann GN, Borner M, Thöni H, Studer UE. Extragonadal retroperitoneal germ cell tumor: Evidence of origin in the testis. *Ann Oncol* 2002;13:121-4.
3. Fabre E, Jira H, Izard V, Ferlicot S, Hammoudi Y, Theodore C, *et al.* 'Burned-out' primary testicular cancer. *BJU Int* 2004;94:74-8.
4. Burt ME, Javadpour N. Germ-cell tumors in patients with apparently normal testes. *Cancer* 1981;47:1911-5.
5. Payombarnia SA, Safavi S, Azarpira N. Primary retroperitoneal seminoma: A case report. *Iran Red Crescent Med J* 2008;10:127-30.
6. Anglade RE, Chang B, Siroky MB. Primary retroperitoneal seminoma with ultrasonically abnormal testes. *Urology* 2001;57:800.

How to cite this article: Liu T, Aparici CM. Primary Retroperitoneal Seminoma Staging and Surveillance by Means of Fluoro-2-Deoxyglucose-Positron Emission Tomography/Computed Tomography. *World J Nucl Med* 2015;14:128-30.

Source of Support: Nil. **Conflict of Interest:** None declared.