

Benign schwannoma of the maxillary antrum

Oshin Hegde¹, Dinkar Desai², Gowri P. Bhandarkar¹, Tony Paul²

Correspondence: Dr. Oshin Hegde
Email: oshinldc@gmail.com

¹Department of Oral Medicine and Radiology,
A.J. Institute of Dental Sciences, Mangalore,
Karnataka, India,

²Department of Oral Pathology, A.J. Institute of Dental
Sciences, Mangalore, Karnataka, India

ABSTRACT

Schwannoma also known commonly as neurilemmoma and schwann cell tumor is a benign nerve sheath tumor. About 1/3rd cases of schwannoma arise from the head and neck region but rarely from the nasal and paranasal sinuses. The recurrence rate in these cases has reported to be very rare. We report a rare case of schwannoma in a 60-year-old woman arising from the maxillary sinus further eroding the orbital floor and nasal bone. We have also described the clinical presentation, radiological, histological findings, and management of the case.

Key words: Maxillary sinus, neurilemmoma, schwannoma

INTRODUCTION

Schwannoma of nasal and paranasal sinuses are rare. About 25% and 45% cases of schwannoma occur in the head and neck region, but only about 4% involves the nasal and paranasal sinuses. Schwannomas are benign tumors originating from the neural crests (Schwann cells). They are often encapsulated and connected to nerve tissue. In microscope examination, they present a combination of two growth patterns, Antoni A and B, both with elongated spindle-shaped cells and regular oval nuclei. Malignant transformation occurs in only 2% of the cases. Local recurrence is common in cases of incomplete tumor resection.^[1]

To our knowledge, only six cases of schwannomas arising solely from maxillary sinus have been reported.^[2] Our report would be the seventh-one arising purely from the maxillary sinus.

CASE REPORT

A 60-year-old South Indian female presented with a swelling on the left zygomatic region of the face since a year with a history of the swelling initially appearing small in size which subsided. It later recurred a month before visiting the clinic. The swelling was associated with fever with no other associated history of epistaxis or headache.

On clinical examination, extraoral inspection revealed slight fullness in the left maxillary region. There was a firm, nontender mass palpable in the floor of left orbit just below the inferior orbital margin. The swelling measured about 4 cm in diameter with the surface appearing normal [Figure 1]. Visual acuity, visual field, and eyeball movements were normal. There was no regional lymphadenopathy. A small nasal polyp

This is an open access article distributed under the terms of the Creative Commons Attribution-NonCommercial-ShareAlike 3.0 License, which allows others to remix, tweak, and build upon the work non-commercially, as long as the author is credited and the new creations are licensed under the identical terms.

For reprints contact: reprints@medknow.com

How to cite this article: Hegde O, Desai D, Bhandarkar GP, Paul T. Benign schwannoma of the maxillary antrum. Eur J Dent 2016;10:281-5.

DOI: 10.4103/1305-7456.178307

Access this article online	
<p>Quick Response Code:</p> 	<p>Website: www.eurjdent.com</p>

was noted on the left nasal cavity. Palpation revealed it to be tender and soft.

The intraoral inspection revealed her oral hygiene to be poor. Malaligned dentition with calculus debris and mobility was seen. There was an intraoral swelling seen at the palatal region measuring about 5 cm in diameter extending from 24 to maxillary tuberosity region. On palpation, it revealed to be tender and hard to firm [Figure 2].

Radiological investigations

Occlusal radiograph and orthopantomogram revealed the presence of minute radiopaque structures resembling calcifications in an ill-defined hazy radiopacity in the left maxillary sinus suggestive of the residues of the eroded bone [Figures 3a, b and 4a]. Cone-beam computed tomography (CBCT) revealed soft tissue opacity in the left maxillary sinus with the extension of the mass into the left nasal cavity almost invading the nasal septum along with prominence in the calcification seen in the center of the sinus cavity as well [Figure 4b]. Bony erosions were seen involving the left floor of the orbit, nasal wall, and nasal septum. The sinus cavity appeared expanding as an expression of the pressure due to the growing mass [Figure 4c].

Histopathological findings

The patient was further sent to the Department of Oral Pathology for a biopsy which conferred to be schwannoma. The given hematoxylin and eosin section showed a spindle cell proliferation with some areas showing palisaded arrangement of the nuclei around a central acellular eosinophilic area. Other areas showed cellular, unorganized spindle cells arranged randomly in a loose myxomatous stroma. Focal areas of nuclear atypia were seen. The lesion was capsulated. Focal areas of dilated blood vessels were also seen. A biphasic pattern was seen with the presence of both Antoni Type A and Type B cells [Figure 5a]. Necrotic areas and degenerative changes were not evident. Confirmation was carried out on performing immunohistochemical (IHC) staining using S-100 marker [Figure 5b].

Differential diagnosis

Clinical differential diagnosis can be given as odontogenic tumors such as ameloblastoma but in our case there was no unerupted teeth or egg shell crackling, fibro-osseous lesions like fibrous dysplasia but it does not occur in older age groups, a soft tissue malignancy due to its enormous growth. Neurofibroma also originates from Schwann cells

and must be considered as a differential during the histopathologic examination.

Management

On being diagnosed with schwannoma, the patient

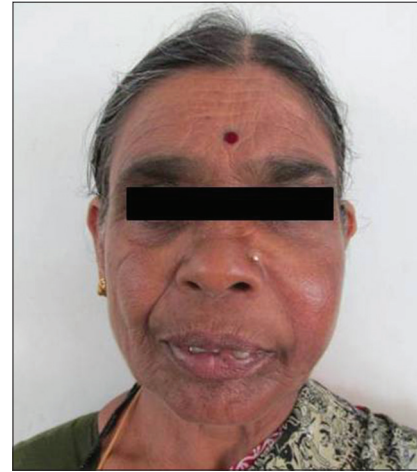

Figure 1: Extraoral picture showing facial swelling on the left zygomatic region

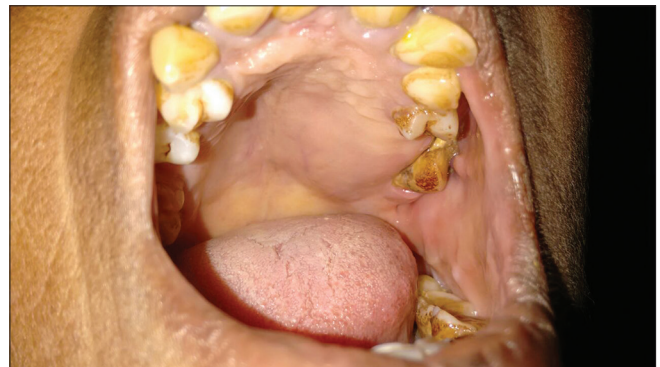


Figure 2: Intraoral picture showing a swelling in the hard palate region extending from 24 to 28

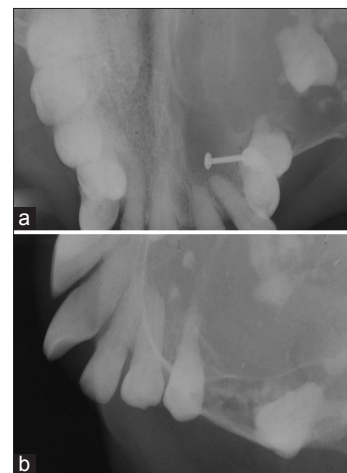


Figure 3: (a) Cross-sectional occlusal radiograph showed ill-defined radiolucency seen in the sinus with expanded cortical plate buccally. (b) Topographic occlusal showed radiopacities within the sinus cavity

underwent hemimaxillectomy by Modified Weber Fergusson approach (with Lynch extension). Initially, tarsorrhaphy sutures were given to close the patient's eyelids. The outline of the purposed approach was highlighted using a marker. The marking was drawn starting from the lower border of the left eye extending until 2 mm from the medial canthus, it was extended downward along the lateral border of the nose until the midpoint of the philtrum of the upper lip dividing it into two equal parts.

Intraorally the incision was continued through the gingival margin and was connected with a horizontal incision at the depth of the labiobuccal vestibule extending back to the maxillary tuberosity. The incision was then given medially across the posterior end of the hard palate further turning to 90° anteriorly to the proximal side of the midline.

Extraorally the incision was given deeper onto the bone following the markings right from the upper lip except for the lower eyelid area to preserve the orbicularis oculi muscle. The incision extending around the nose was deepened to the nasal cavity. The cheek flap was reflected and the lesion was exposed. The gingival and palatal mucosa were elevated back to the midline. The palatal bone was divided near the midline using a saw blade and bur, the basal bone was separated from the frontal process of the maxilla with an osteotome. The orbicularis oculi muscle was retracted superiorly and the bone was cut extending across the maxilla just below the inferior orbital rim. The entire specimen by hemimaxillectomy was removed in toto severing the remaining attachments using a large curved scissor placing behind the maxilla. The excessive bleeding was controlled with electrocautery, and all the sharp bony projections were trimmed off.

The palatal flap was turned up to cover the medial bony margin, and the hollow space created postsurgery below the orbital floor and the maxillary region was covered with a packing made up of acrylic resin, wrapped with the skin graft taken from the patients shin area of the leg was used. Finally, a prefabricated obturator was placed to seal the defect and support the packing. The obturator was fixed to the overlying zygomatic bone. The extraoral reflected cheek flap was sutured to its normal anatomical site [Figures 6a and 7b].

DISCUSSION

Benign schwannomas have also been called as neurilemmas, neurolemomas, neurinomas and

peripheral fibroblastomas. Head and neck are one of the most frequent sites for the occurrence of these tumors, intraorally the tongue is the most common site. Primary schwannomas arising in the nasal and paranasal sinuses are uncommon. Only 4% of these nerve sheath tumors develop in the head

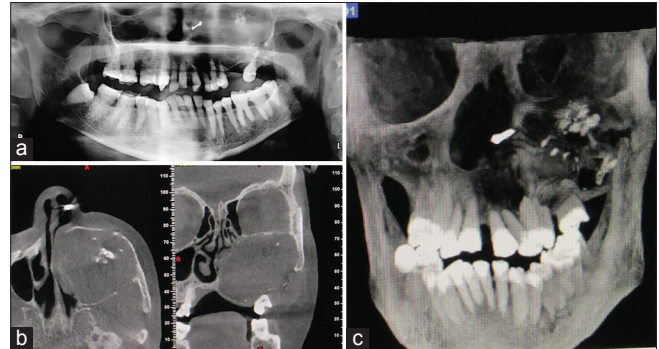


Figure 4: (a) Orthopantomogram showed radiopacity in the left maxillary sinus. (b) Axial and coronal cone beam computed tomography section showed soft tissue radiopacity within the maxillary sinus cavity. (c) Cone beam computed tomography three-dimensional view showed irregular bony erosions with radiopaque structures on left maxillary sinus

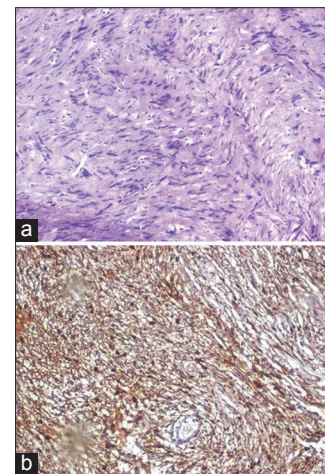


Figure 5: (a) H and E, ×40 magnifications. (b) Immunohistochemistry (S-100), showing diffuse positivity

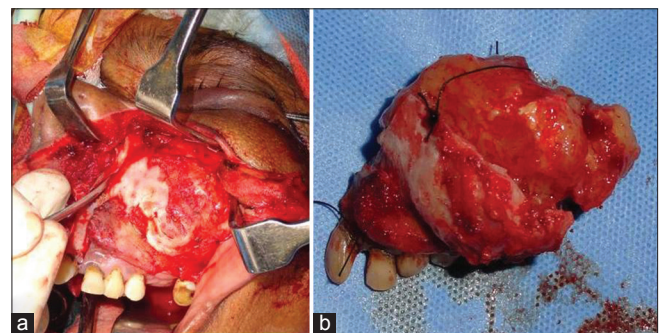


Figure 6: (a) Weber-Fergusson approach. (b) Gross excised specimen

and neck region, especially in the paranasal sinuses [Figure 6a and b].

In paranasal sinuses, these tumors arise from the ophthalmic and maxillary divisions of the trigeminal nerve. The neoplasm may develop at any age, and there is no sex predilection. The symptoms depend on the location/site of involvement and malignancy.^[1] Robitaille *et al.* while going through the previous studies and literature found that epistaxis is usually noticed in cases with nasal and ethmoid sinus neoplasms while the pain was more commonly associated with lesions of the maxillary sinus. Other symptoms associated were a nasal blockage, rhinorrhea, exophthalmous, hyposmia, and facial swelling.^[2] In our case as symptoms were facial swelling and pain, it therefore demanded a better explanation through radiological investigation. CBCT scans of nasal and paranasal sinuses is the most useful and upcoming investigation, as of current scenario, as it gives complete information about the size and extent of the tumor and involvement or erosion of the adjacent bony structures which in our case appeared very evident. Magnetic resonance imaging should also be performed to know the intracranial extension and differentiation of tumors.^[3] According to literature, bony erosions is not an independent diagnostic factor to prove a malignancy. However, the peculiarity of this case is the calcifications seen within the sinus cavity which could confuse our diagnosis as this would be the first case of schwannoma presenting radiopaque structures radiographically within the lesion.

The final diagnosis could be arrived only after histopathological examination, which is considered as the gold standard for diagnosis of any lesion.

Histopathological examination exhibited a typical biphasic pattern. There are two patterns being:

- Antoni Type-A which consists of spindle shaped cells with long, slender fibers forming a parallel arrangement of nuclei, known as the palisading arrangement of the cells
- Antoni Type-B are basically degenerative in nature with myxoid changes seen in the connective tissue stroma, the cells and fibers run in haphazard manner, the entire tissue is loose in texture present due to cystic degeneration.^[4] In the present case, the histopathology showed the presence of both Type A and B cells.

The important diagnostic tool used in this case was the IHC staining which gave positive results. The marker used was the S-100 protein which is basically

a neural crest marker antigen that gave the intense diffuse immune-staining thereby giving a clear cut diagnosis of schwannoma.^[5]

In the present case, there were no invasive areas observed histopathologically. Malignant transformation of these tumors is very rare. The treatment of choice is complete surgical excision of the tumor. The surgical approach depends on the location, extent and the close proximity of the tumor to the surrounding vital structures. In our case, hemimaxillectomy was performed with that region later being replaced with an artificial acrylic obturator to support the graft and the acrylic packing. The patient made an uneventful recovery and was discharged home on simple analgesia and antibiotics. No postoperative complications were reported a month after the surgery, and the patient returned to her normal functional level.

After 3 months, a follow-up was done where the previous obturator was replaced with a new interim acrylic obturator and furthermore, the patient was sent for receiving a permanent prosthodontic rehabilitation [Figure 7a-c].

The recurrence of these tumors after a successful *en bloc* removal is very rare. While treating benign schwannomas, functional, and esthetic considerations should be given prime importance as well as detailed attention because they may be impinging on critical structures.^[6]

Radiotherapy should be reserved for patients who are considered unsuitable for surgery and for patients with malignant schwannomas.^[7] The role of radiotherapy and chemotherapy in the treatment of this tumor is still controversial. Some recent reports

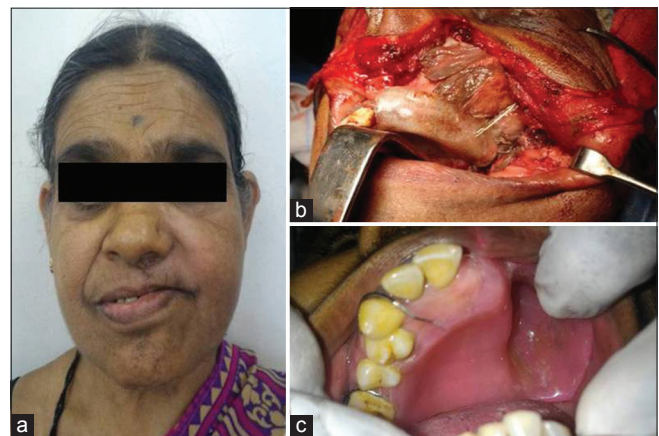

Figure 7: (a) Postoperative extraorally. (b) Obturator placed during surgery. (c) Postoperative interim obturator

recommend the use of postoperative radiotherapy, but there is no clear evidence of a definite benefit in malignancy. Since in our case, the lesion was benign, therefore, no radiotherapy/chemotherapy was required. Despite aggressive multimodal therapy, the long-term prognosis for malignant lesion remains poor, with reported 5-year survival rates ranging between 30% and 65% whereas for the benign lesion it has shown good prognosis.^[8] In our case, the prognosis was good, and the patient was satisfied.

Declaration of patient consent

The authors certify that they have obtained all appropriate patient consent forms. In the form the patient(s) has/have given his/her/their consent for his/her/their images and other clinical information to be reported in the journal. The patients understand that their names and initials will not be published and due efforts will be made to conceal their identity, but anonymity cannot be guaranteed.

Financial support and sponsorship

Nil.

Conflicts of interest

There are no conflicts of interest.

REFERENCES

1. Robitaille Y, Seemayer TA, El Deiry A. Peripheral nerve tumors involving paranasal sinuses: A case report and review of the literature. *Cancer* 1975;35:1254-8.
2. Sheikh HY, Chakravarthy RP, Slevin NJ, Sykes AJ, Banerjee SS. Benign schwannoma in paranasal sinuses: A clinico-pathological study of five cases, emphasising diagnostic difficulties. *J Laryngol Otol* 2008;122:598-602.
3. Calcaterra TC, Rich JR, Ward PW. Neurilemoma of the sphenoid sinus. *Arch Otolaryngol* 1974;100:383-5.
4. Khanna S, Gupta SC, Singh PA. Schwannoma of maxillary sinus. *Indian J Otolaryngol Head Neck Surg* 2003;55:132-5.
5. Donnelly MJ, Al-Sader MH, Blaney AW. View from beneath: Pathology in focus. benign nasal schwannoma. *J Laryngol Otol* 1992;106:1011-5.
6. Younis RT, Gross CW, Lazar RH. Schwannomas of the paranasal sinuses. Case report and clinicopathologic analysis. *Arch Otolaryngol Head Neck Surg* 1991;117:677-80.
7. Colreavy MP, Lacy PD, Hughes J, Bouchier-Hayes D, Brennan P, O'Dwyer AJ, *et al.* Head and neck schwannomas – A 10 year review. *J Laryngol Otol* 2000;114:119-24.
8. Anghileri M, Miceli R, Fiore M, Mariani L, Ferrari A, Mussi C, *et al.* Malignant peripheral nerve sheath tumors: Prognostic factors and survival in a series of patients treated at a single institution. *Cancer* 2006;107:1065-74.