

Root canal retreatment using reciprocating and continuous rotary nickel-titanium instruments

Patricia Fonseca de Souza¹, Leonardo Cantanhede Oliveira Goncalves¹,
Andre Augusto Franco Marques¹, Emilio Carlos Sponchiado Junior²,
Lucas da Fonseca Roberti Garcia³, Fredson Marcio Acris de Carvalho¹

¹Department of Endodontics, State University of Amazonas, Manaus, Amazonas, Brazil,

²Department of Endodontics, Federal University of Amazonas, Manaus, Amazonas, Brazil,

³Department of Physiology and Pathology, Araraquara School of Dentistry, Univ Estadual Paulista, Araraquara, São Paulo, Brazil

Correspondence: Dr. Lucas da Fonseca Roberti Garcia
Email: drlucas.garcia@gmail.com

ABSTRACT

Objective: The complete filling material removal during endodontic retreatment is a clinical procedure difficult to achieve. The aim of this study was to evaluate the efficacy of reciprocating and continuous rotary nickel-titanium instruments used in root canal retreatment. **Materials and Methods:** Forty freshly extracted human premolars were cleaned and shaped by the crown-down technique, followed by filling by the lateral compaction technique. The teeth were randomly separated into two groups ($n = 20$), according to the system used for filling material removal: G1 - Reciproc and G2 - ProTaper Universal Retreatment System. The teeth were photographed under operating microscope at $\times 8$ magnification; and the total area of the root canal and remaining filling material were quantified. **Results:** No statistically significant difference ($P > 0.05$) in residual filling material was observed between groups; however, the time required for filling removal was significantly shorter for Reciproc system ($P < 0.05$). **Conclusions:** It was observed remaining filling material in all teeth, irrespective of the system used; however, root canal retreatment was faster when reciprocating motion was used.

Key words: Reciprocating motion, root canal retreatment, rotary instruments

INTRODUCTION

About one-third of endodontically treated teeth do not have satisfactory outcomes, and periapical radiolucency can be seen in most of them, which requires retreatment.^[1] When treatment failure is identified during clinical/radiographic control, two procedures must be considered: root canal retreatment or apical surgery, both of which may be successful when correctly recommended.^[2] However, whenever access to the root canal is possible, endodontic retreatment should be the preferred choice.^[2,3]

Several techniques for filling materials removal are currently used, including manual and rotary

instruments, preceded by the softening of the filling material with heat or solvents appropriate for such purpose.^[4,5] However, no retreatment technique is capable of removing the filling material completely; resulting in residual debris attached to the root canal walls after reinstrumentation.^[4,5]

Nickel-titanium (NiTi) continuous rotary system called ProTaper Universal Retreatment (Dentsply/Maillefer, Ballaigues, Switzerland) was developed for filling material removal.^[6] The system consists of three instruments: D1, size 30 and 0.09 taper; D2, size 25 and 0.08 taper; and D3 size 20, 0.07 taper.^[6] Furthermore, D1 has an active tip that facilitates the initial penetration of the instrument into the filling material.^[6]

How to cite this article: de Souza PF, Oliveira Goncalves LC, Franco Marques AA, Sponchiado Junior EC, Roberti Garcia Ld, de Carvalho FM. Root canal retreatment using reciprocating and continuous rotary nickel-titanium instruments. *Eur J Dent* 2015;9:234-9.

Copyright © 2015 Dental Investigations Society.

DOI: 10.4103/1305-7456.156834

Instruments with reciprocating motion, such as Reciproc (VDW, Munich, Germany), were initially developed for root canal preparation; however, due to their flexibility and high resistance to cyclic fatigue, these files are a new alternative for filling material removal during endodontic retreatment.^[7] Although several studies have discussed the great potential of these instruments concerning the preparation of the root canals,^[8,9] few studies have evaluated the efficacy of these systems in gutta-percha and sealer removal during endodontic retreatment.

Thus, the aim of this study was to evaluate the efficacy of reciprocating and continuous rotary NiTi instruments in root canal retreatment of extracted human mandibular premolars. The null hypothesis tested was that there would be no difference between the systems tested.

MATERIALS AND METHODS

Teeth selection

Forty freshly extracted single-rooted human premolars with straight root canals, standardized root length of 16 mm and fully formed apices were provided by the Human Tooth Bank of the State University of Amazonas, with prior approval from the Research Ethics Committee (Process CAAE No 26938714.9.0000.5016). The teeth were kept in chloramine solution (0.5%) at 4°C for 48 h for the disinfection process, and then washed with running water for 24 h.

Root canal instrumentation

Coronal opening was performed with round diamond burs No. 1014 (KG Sorensen, Cotia, SP, Brazil) coupled to high-speed handpiece (Silent-MRS 350, Dabi Atlante Ribeirão Preto, SP, Brazil), followed by compensatory wear of the root wall using the Endo Z bur (Dentsply/Maillefer, Ballaigues, Switzerland) under constant water cooling. Then, a size 10 K-type file (Dentsply/Maillefer) was inserted in the apical direction until its tip was visible at the foramen. The instrument was retracted 1 mm to determine the working length, which was standardized at 15 mm. To standardize the apical diameter, a size 15 K-type file was inserted into the working length until it was fit into position.

For the teeth to remain in the same position during instrumentation of the root canals, an acrylic matrix divided into 18 compartments measuring 2.0 × 2.0 × 2.0 × 2.0 cm each was used. The compartments were filled with condensation silicone (Clonage, Nova DFL, Jacarepaguá, RJ, Brazil) for tooth fitting. The

buccal/lingual surfaces of the teeth were placed parallel to one side of the matrix, leaving only the canal entrance exposed.

The root canal was prepared by the crown-down technique as follows: Glide path was established with K-files sizes 15, 20 and 25 in the temporary working length (4 mm short); the cervical third was prepared with sizes 2 (0.70 mm), 3 (0.90 mm) and 4 (1.10 mm) Gates-Glidden burs (Dentsply/Maillefer); and apical preparation up to size 40 K-file. In order to improve the shaping of the apical third and fitting of the master gutta-percha cone, the step-back technique with programmed withdrawal of 1 mm up to a size 60 K-file was performed. For irrigation, 2 ml of 2.5% sodium hypochlorite (NaOCl) (Cloro Rio 2.5%, Indústria Farmacêutica Rioquímica LTDA, São José do Rio Preto, SP, Brazil) was applied with a 29-gauge needle (0.29 mm) (Blue NaviTip, Ultradent Products Inc., South Jordan, UT, USA) introduced to 4 mm short of the working length at each change of instrument. After instrumentation, passive ultrasonic agitation was performed in all teeth using a smooth, straight ultrasonic tip (TRA-12, Trinks, São Paulo, SP, Brazil) coupled to a low-power ultrasonic device NacPlus (Adiel, Ribeirão Preto, SP, Brazil). This procedure was performed with the pulp chamber flooded with 2.5% NaOCl for 1 min, followed by aspiration and irrigation with 5 ml of 17% ethylenediaminetetraacetic acid solution (Biodinâmica, Ibiporã, PR, Brazil), agitated for 3 min. Afterward, a final irrigation was performed with 5 ml of 2.5% NaOCl.

Root canal filling

Root canal filling was performed by the lateral compaction technique. First, the root canals were completely dried with sterile absorbent paper cones (Dentsply/Maillefer). Then, a size 40 gutta-percha master cone (Dentsply/Maillefer) was introduced in the root canal, with the first 5 mm were coated with sealer (AH Plus, Dentsply/Maillefer). Accessory fine medium cones (Dentsply/Maillefer) were laterally compressed with a size M spreader (Dentsply/Maillefer) until no other gutta-percha cones could be introduced at a depth >5 mm into the root canal. Each tooth was radiographed in the buccal-lingual and mesio-distal directions to ensure the root canal filling quality [Figure 1]. If any failure in filling were detected radiographically, the sample would be discarded. Afterward, the canal entrances were filled with a temporary restorative material (Coltosol/Vigodent, Rio de Janeiro, RJ, Brazil) and the teeth were stored at 100% humidity in artificial saliva at 37°C for 30 days

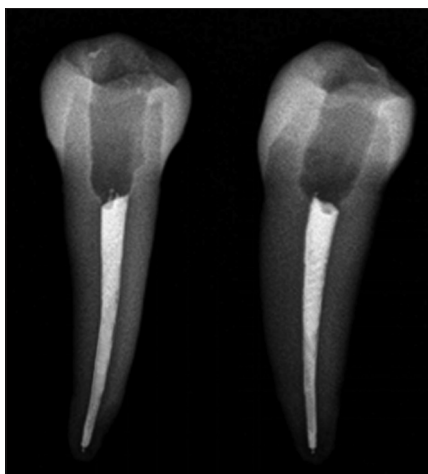


Figure 1: Radiographic examination of teeth after filling to ensure the filling quality

to simulate the oral conditions; and to allow complete setting of the cement and the temporary restorative material.

Root canal retreatment

The initial filling material removal from each tooth was performed, in the same way, following the methodology described by Zuolo *et al.*:^[8] initially, Largo burs (28 mm) sizes 1, 2 and 3 (tip sizes 0.70 mm, 0.90 mm and 1.10 mm, respectively) were used in the first four millimeters of the root canals to perforate the gutta-percha and facilitate the action of the instruments. After using the Largo burs, 0.1 ml of chloroform was applied inside the root canal for 30 s to soften the gutta-percha. The chloroform was introduced into the root canal using a 1 ml-insulin syringe.

Afterward, the teeth were randomly separated into two groups ($n = 20$) and the root canals were reinstrumented:

- Group 1: Root canal filling material was removed with Reciproc R50 (VDW, GmbH, Munich, Germany). The instrument was introduced inside the root canal in 3 in-and-out movements with an amplitude of approximately 3 mm. Apical pressure was applied with gentle movements against the root canal walls, as recommended by the manufacturer. As the instrument advanced inside the root canal, it was removed and cleaned with sterile gauze. This procedure was repeated until the instrument reached 0.5 mm beyond the original working length. The Reciproc instrument is designed for single use, and it was used only in one root canal and was then discarded
- Group 2: D1, D2 and D3 instruments (tip 0.20 mm) of the ProTaper Universal retreatment system was

used in sequence in in-and-out movements toward the apex until the working length was reached with the D3 instrument. The D1 instrument operated at a constant speed of 500 rpm and D2 and D3 instruments at 400 rpm with a torque of 3 Ncm, according to manufacturer's instructions. For reinstrumentation, the F2, F3, F4 and F5 instruments were used at 0.5 mm beyond the original working length. The ProTaper Universal F2, F3, F4 and F5 instruments and retreatment D1, D2 and D3 were used in four specimens and then discarded.

The motor used for reinstrumentation of the root canals was the VDW SILVER RECIPROC (VDW) with a 6:1 contra-angle handpiece (Sirona, SN S 12345, VDW GmbH, Munich, Germany) using the preprogrammed reciprocating motion for the Reciproc system in the "reciprocation all" mode, during which rotation speed and accuracy of motor torque were automatically calibrated by the calibration function (CAL). During retreatment, all teeth, regardless of the instrumentation system used, underwent the same irrigation protocol used during the previous instrumentation procedure of the root canals.

Each tooth was radiographed after filling material removal procedure. If any remaining filling material were observed, the canal would be reinstrumented until no remaining filling material could be observed radiographically in the root canal.

In all experimental groups, apical reparation was standardized with an instrument compatible with 50-gauge instrument (0.50 mm), or R50 Reciproc instrument (VDW) and F5 (Dentsply/Maillefer). A single operator, specialist in endodontics, performed all procedures for samples standardization.

Evaluation of the filling material removal effectiveness

After reinstrumentation of the root canals, the teeth were sectioned longitudinally using a single-faced diamond disc (Microdont, São Paulo, Brazil) and divided into two halves using the size 5 LeCron instrument (SSWhite/Duflex, Rio de Janeiro, Brazil). All samples were photographed at $\times 8$ magnification using a digital camera (Canon EOS, Digital Rebel XTi, Lake Success, NY, USA) coupled to dental surgical microscope (Alliance, São Carlos, SP, Brazil).

The images were transferred to a computer to outline the contour of each half of the canal and the areas

containing the remaining filling material [Figure 2]. The outlined areas were measured using the Image Tool software (University of Texas Health Science Center, San Antonio, TX, USA) to quantify the total area of the canal and remaining filling material in each tooth.

Two previously calibrated examiners evaluated the amount of remaining filling material blindly. For quantification, the total area of the two halves of the root canal was considered as 100%; and the area of remaining filling material was equal to 'X'. The numerical values obtained were calculated into percentage values. The proportion of filling material inside the root canal and the total area were calculated and expressed in mm. The set scale tool of Image Tool software transformed the known measurement of a real object in pixels into mm².

The total time required for retreatment since the introduction of the first instruments applied in the root canal until the recovery of the original working length according to the system used in each group were also considered. For this purpose, we used a digital stopwatch (Oregon Scientific-SI928 m, Portland, OR, USA) that was paused every time the instrument was removed from the canal, and restarted when preparation continued with another instrument. The time measurements were expressed in seconds(s).

Statistical analysis

The normal distribution of data was tested by the Kolmogorov-Smirnov test ($P < 0.05$) and the values obtained for filling material removal were statistically compared (one-way ANOVA, Student *t*-test, $P < 0.05$) using the GraphPad InStat software (GraphPad Software, La Jolla, CA, USA).

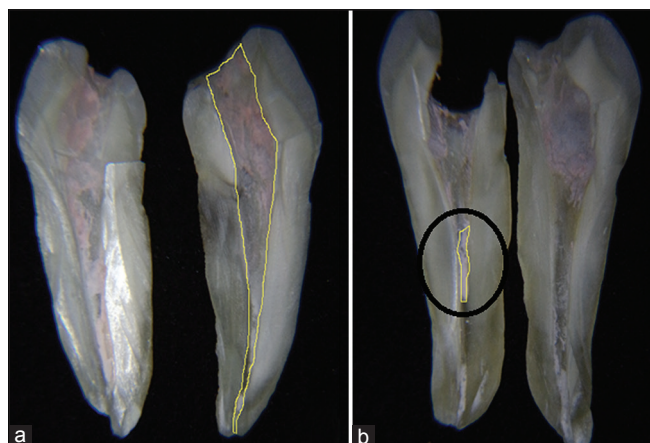


Figure 2: Remaining filling material evaluation. (a) Calculation of the total area (mm²). (b) Calculation of the remaining filling material area (mm²) (indication)

RESULTS

The mean percentage values of the remaining filling material on root canal walls are shown in Table 1.

Remnants of filling material (gutta-percha and sealer) were observed on the walls of the root canals of all examined teeth, regardless of kinematic motion used (reciprocating or continuous rotary) [Figure 3]. The mean percentage of remaining filling material on the root canal walls was 28.84% in Group 1; and 29.91% in Group 2, with no statistically significant difference ($P > 0.05$). However, the filling material removal from the root canal walls was significantly faster in Group 1 (76.17 s) than in Group 2 (118.31 s) ($P < 0.05$) [Table 2].

Table 1: Mean values (%) and SD of remaining filling material in the root canal walls after retreatment (n=20)

Groups	Mean value (SD)
Reciproc	28.84 (5.17) ^{a,*}
ProTaper retreatment	29.91 (5.59) ^a

*Lowercase letters compare groups in vertical lines. Means followed by different letters are significantly different ($P < 0.05$). $P = 0.05$. SD: Standard deviation

Table 2: Mean values (s)* and SD of time required to perform filling material removal

Groups	Mean value (SD)
Reciproc	76.17 (34.69) ^{a,**}
ProTaper retreatment	118.31 (31.40) ^b

*s=seconds. **Lowercase letters compare groups in vertical lines. Means followed by different letters are significantly different ($P < 0.05$). $P = 0.07$. SD: Standard deviation

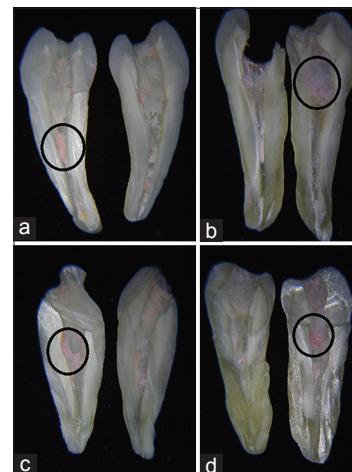


Figure 3: (a and b) Representative images of samples from Group 1. (c and d) Representative images of samples from Group 2. Note the presence of remaining filling material attached to the root canal walls (indication)

DISCUSSION

The aim of this study was to evaluate the efficacy of reciprocating and continuous rotary NiTi instruments during root canal retreatment. Based on these results, the null hypothesis was partially accepted since the instruments tested with different kinematic motion presented similar performance and effectiveness in filling material removal from the root canal. However, the instrument with reciprocating motion was able to perform the procedure faster.

Reciproc system represents a new concept for root canal treatment using only one motor-driven NiTi instrument, with no previous instrumentation.^[7,10] These instruments are made of M-wire NiTi alloy, which offers greater resistance to cyclic fatigue and greater flexibility than the traditional NiTi instruments.^[11] In reciprocating motion, the instrument rotates counterclockwise and clockwise with 120° of difference between the two movements.^[12,13] The kinematics motion promotes a significant reduction in the screwing-in effect, with a pronounced reduction of compression forces and bending fatigue.^[11,12,14]

Although the Reciproc system was not originally designed for root canal retreatment,^[7] the hypothesis that the specific design of the instruments, as well as reciprocating motion, can be potentially beneficial for the effective filling material removal was confirmed in the present study, as no significant difference was found for the ProTaper Universal Retreatment system, which was originally designed for this purpose.

In addition, considering the operative time for the completion of retreatment, the reciprocating motion system was able to perform the procedure faster than the continuous rotary system. This result can be explained by the amount of instruments used, since Reciproc system was designed to use only one file for biomechanical preparation, which significantly reduces working time.^[7,13] Studies reported that the Reciproc system decreases preparation time in 62% when compared with other conventional rotary systems.^[13] In addition, the instrument is discarded after each use, preventing cross-contamination between patients.^[15]

Beasley *et al.*^[16] reported fractures and deformations in the D3 instruments of the ProTaper Universal Retreatment system during retreatment of curved root canals. This inconvenience could be attributed to the high taper of the instrument and high-speed of rotation

during root canal preparation, factors that may increase torsional fatigue of instruments in contact with filling materials.^[16] The ProTaper Universal Retreatment system is capable of removing large amounts of filling material due to its negative cutting angle and lack of radial guide, which exert a cutting action instead of a smoothing action on the gutta-percha.^[17] In the present study, no fracture of the instruments during the filling material removal was observed, which may be related to the most favorable anatomy of the straight root canals. In addition, the instruments of the ProTaper Universal Retreatment system were used at a constant speed of 500 rpm for D1 and 400 rpm for D2 and D3 with a torque of 3 Ncm, as described by previous studies^[9] and according to the manufacturer's recommendations. This fact may also have been contributed to the no fracture of the instruments.

In a recent study, Zuolo *et al.*^[8] compared the efficacy of reciprocating motion and continuous rotary system with hand files for the removal of filling material from the root canal. The continuous rotary system was not as effective as the reciprocating system and hand instruments for filling material removal, findings that differ from the results of the present study. It is noteworthy that the continuous rotary system used in the study of Zuolo *et al.*^[8] was the MTwo R (VDW). According to Bramante *et al.*,^[4] the MTwo R system is less effective than the ProTaper Universal Retreatment instruments, the same used in this study, and the manual files for filling material removal.

It is valid to emphasize that no system tested in this study was able to completely remove the filling material from the root canal walls, findings that are corroborate for other studies.^[8,9,18,19] In addition, the results of the present study cannot be attributed only to the different kinematic motion of the instruments, since other factors, such as design of active tip, dimensions and number of instruments, might have influence on the amount and speed of filling material removal.^[8,9]

Regarding the method used in this study for root canal filling removal quantification, several studies have reported that the use of vertical split roots is an adequate technique, and more accurate than radiographic examinations, which produces only two-dimensional images of the samples.^[8,9,18,19] Also, the cleaving method was performed carefully to not displace the remaining filling material from the root canal walls. For this reason, teeth were initially sectioned longitudinally using a single-faced

diamond disc, and then cleaved with a size 5 LeCron instrument.^[9]

Despite the limitations of this *in vitro* study, it may be concluded that both systems tested were unable to completely remove the filling material from the root canal, leaving remaining material adhered to the dentin walls, which confirm that regardless of the kinematic motion, the endodontic retreatment is a clinical procedure difficult to achieve. However, the reciprocating system has proved to be capable of performing the procedure faster than the continuous rotary system.

REFERENCES

1. Kvist T, Reit C. Postoperative discomfort associated with surgical and nonsurgical endodontic retreatment. *Endod Dent Traumatol* 2000;16:71-4.
2. Del Fabbro M, Taschieri S. A systematic review on the outcome of surgical vs non-surgical procedure for the retreatment of periapical lesions. *Minerva Stomatol* 2007;56:621-32.
3. Kvist T. Endodontic retreatment. Aspects of decision making and clinical outcome. *Swed Dent J Suppl* 2001;144:1-57.
4. Bramante CM, Fidelis NS, Assumpção TS, Bernardineli N, Garcia RB, Bramante AS, *et al.* Heat release, time required, and cleaning ability of MTwo R and ProTaper universal retreatment systems in the removal of filling material. *J Endod* 2010;36:1870-3.
5. Jantarat J, Malhotra W, Sutimuntanakul S. Efficacy of grapefruit, tangerine, lime, and lemon oils as solvents for softening gutta-percha in root canal retreatment procedures. *J Investig Clin Dent* 2013;4:60-3.
6. Giuliani V, Cocchetti R, Pagavino G. Efficacy of ProTaper universal retreatment files in removing filling materials during root canal retreatment. *J Endod* 2008;34:1381-4.
7. Yared G. Canal preparation using only one Ni-Ti rotary instrument: Preliminary observations. *Int Endod J* 2008;41:339-44.
8. Zuolo AS, Mello JE Jr, Cunha RS, Zuolo ML, Bueno CE. Efficacy of reciprocating and rotary techniques for removing filling material during root canal retreatment. *Int Endod J* 2013;46:947-53.
9. Rios Mde A, Villela AM, Cunha RS, Velasco RC, De Martin AS, Kato AS, *et al.* Efficacy of 2 reciprocating systems compared with a rotary retreatment system for gutta-percha removal. *J Endod* 2014;40:543-6.
10. Prichard J. Rotation or reciprocation: A contemporary look at NiTi instruments? *Br Dent J* 2012;212:345-6.
11. Kim HC, Kwak SW, Cheung GS, Ko DH, Chung SM, Lee W. Cyclic fatigue and torsional resistance of two new nickel-titanium instruments used in reciprocation motion: Reciproc versus WaveOne. *J Endod* 2012;38:541-4.
12. Gavini G, Caldeira CL, Akisue E, Candeiro GT, Kawakami DA. Resistance to flexural fatigue of Reciproc R25 files under continuous rotation and reciprocating movement. *J Endod* 2012;38:684-7.
13. Bürklein S, Hinschitza K, Dammaschke T, Schäfer E. Shaping ability and cleaning effectiveness of two single-file systems in severely curved root canals of extracted teeth: Reciproc and WaveOne versus Mtwo and ProTaper. *Int Endod J* 2012;45:449-61.
14. De-Deus G, Moreira EJ, Lopes HP, Elias CN. Extended cyclic fatigue life of F2 ProTaper instruments used in reciprocating movement. *Int Endod J* 2010;43:1063-8.
15. Pedullà E, Grande NM, Plotino G, Gambarini G, Rapisarda E. Influence of continuous or reciprocating motion on cyclic fatigue resistance of 4 different nickel-titanium rotary instruments. *J Endod* 2013;39:258-61.
16. Beasley RT, Williamson AE, Justman BC, Qian F. Time required to remove guttacre, thermafil plus, and thermoplasticized gutta-percha from moderately curved root canals with protaper files. *J Endod* 2013;39:125-8.
17. Rödiger T, Hausdörfer T, Konietzschke F, Dullin C, Hahn W, Hülsmann M. Efficacy of D-RaCe and ProTaper Universal Retreatment NiTi instruments and hand files in removing gutta-percha from curved root canals-A micro-computed tomography study. *Int Endod J* 2012;45:580-9.
18. de Mello Junior JE, Cunha RS, Bueno CE, Zuolo ML. Retreatment efficacy of gutta-percha removal using a clinical microscope and ultrasonic instruments: Part I – an *ex vivo* study. *Oral Surg Oral Med Oral Pathol Oral Radiol Endod* 2009;108:e59-62.
19. Takahashi CM, Cunha RS, de Martin AS, Fontana CE, Silveira CF, da Silveira Bueno CE. *In vitro* evaluation of the effectiveness of ProTaper universal rotary retreatment system for gutta-percha removal with or without a solvent. *J Endod* 2009;35:1580-3.

Access this article online

Quick Response Code:



Website:
www.eurjdent.com

Source of Support: Nil.
Conflict of Interest: None declared.