

Evaluation of the apical adaptation performance of various root canal instruments

K. Tolga Ceyhanli¹, Murat Turkun², Necdet Erdilek³, Cem Peskersoy², Timur Kose⁴

Correspondence: Dr. K. Tolga Ceyhanli
Email: tolgaceyhanli@hotmail.com

¹Department of Endodontics, Faculty of Dentistry, Karadeniz Technical University, Trabzon, Turkiye,
²Department of Restorative Dentistry, Faculty of Dentistry, Ege University, Izmir, Turkiye,
³Department of Endodontics, Faculty of Dentistry, Ege University, Izmir, Turkiye,
⁴Department of Biostatistics and Medical Informatics, Faculty of Medicine, Izmir, Turkiye

ABSTRACT

Objective: The aim of this study was to evaluate the apical root canal adaptation performance of various root canal instruments. **Materials and Methods:** A total of 40 freshly extracted single-rooted mandibular incisors were used in this study. Coroner parts of all teeth were removed from cemento-enamel junction and root canal of each tooth was explored with a size 8 K-file until the tip of the file was just visible at the apex. Working lengths (WLs) were determined as 1 mm short of these measurements. ProTaper, K-file, profile and hedstroem files were inserted into the root canals of 10 teeth to the WL following the flaring of the coronal and middle thirds. Instruments were fixed in the root canals with acrylic resin. The apical 1 mm of each root tip was ground on wet sandpaper to expose the canal and the instrument at the WL and the apical region of each tooth was examined under stereomicroscope. The stereoscopic images of the teeth were digitized and analyzed with software in order to determine the differences between the areas of root canals and file tips. Result data were analyzed using the one-way analysis of variance test ($P = 0.05$). **Results:** There were no significant differences between apical file/root canal areas of the evaluated instruments ($P > 0.05$). **Conclusions:** None of the evaluated instruments performed a perfect adaptation with the apical root canal surface at the WL in mandibular incisors. Therefore, total removal of the debris from the apical canal surface may not be achieved when these filing instruments are used.

Key words: Apical adaptation, hand instruments, ProFile, ProTaper, stereomicroscope

INTRODUCTION

Bacteria were found in dentinal tubules of root canal dentine in histological sections of infected teeth and apical portion of root canal is an area of interest that may harbor a critical level of microorganisms, which is effective on apical periodontitis.^[1-4] Although cleaning of recessed surfaces is based more on irrigation, mechanical debridement at all circumferences of the apical root canal region is an important goal for endodontic instrumentation.^[5-7]

Horizontal dimension of the preparation at its most apical extend is a critical parameter that the

clinician must determine for preparation.^[8] In early literature; according to recommendations of Weine,^[9] enlargement of canals three sizes larger than the first file to bind was enough for apical preparation. The aim of this procedure was making up an apical stop to reduce the leakage and material extrusion. However, morphologic analyses have shown that apical foramen often does not have a round shape and to achieve a more accurate estimate of the apical diameter, removal of the interferences along the coronal and middle thirds of the root canal is necessary.^[10-13]

Coronal flaring may eliminate the coronal interferences of the narrow and irregular canals and provide a

How to cite this article: Ceyhanli KT, Turkun M, Erdilek N, Peskersoy C, Kose T. Evaluation of the apical adaptation performance of various root canal instruments. *Eur J Dent* 2013;7:41-4.

Copyright © 2013 Dental Investigations Society.

DOI: 10.4103/1305-7456.119070

reliable apical adaptation to instruments.^[14,15] Recently, rotary Ni-Ti instrumentation systems are popular for the preparation of root canals and most of these systems suggest coronal flaring before apical shaping with finisher instruments.

Apical adaptation of the first instrument can be a reference for determining the apical preparation size and it is important in terms of best possible debridement of the infected root canals.^[16,17] The aim of this study was to evaluate the adaptation of first hand files (K, H file) that bind at working lengths (WLs) and first finisher rotary instruments (ProTaper, profile) that reach to WL after coronal flaring. Tactile sensibility was considered as a reference and stereomicroscope was used for evaluations.

MATERIALS AND METHODS

A total of 40 freshly extracted single-rooted mandibular incisors were selected for the study. The teeth were cleaned with periodontal curettes and sterilized in the autoclave. Canal curvatures were determined on radiographs by Schneider's method. Teeth, which have complicated anatomy, external resorption or canal curvature more than 10° were excluded. The crowns of all teeth were removed from cemento-enamel junction to get an easy access and flat reliable reference point for length measurements. Access to the pulp chamber was performed with round diamond burs. Pulp tissues were removed with barbed broaches and root canal of each tooth was explored with a size 8 K-file until the tip of the file was just visible at the apical foramen. WLs were determined as 1 mm short of these measurements. ProTaper (Dentsply Maillefer, Ballaigues, Switzerland), ProFile (Dentsply Maillefer), K-file (Mani, Tokyo, Japan) and Hedstroem (Mani) files were used to evaluate apical binding.

Cervical and middle thirds of the teeth were flared with no. 2 and 1 gates-glidden burs for Hedstroem (H-file) and K-files. After irrigation of the canals with 5 mL NaOCl one investigator passively inserted increasing sizes of files started with size 10 until sense of binding. When binding was occurred only a bit short of WL one balanced force motion performed without apical pressure to reach to WL.

ProTaper rotary instrumentation group: SX, S1 and S2 files were used to the WL respectively and F1 or F2 files were the first finisher files that reached the WL with a sense of apical resistance. Apical stop

preparation was checked by the sense of apical resistance with hand usage of the last file at WL to see apical binding of the last former instrument. For ProFile group 6% tapered no. 30 and 25, 4% tapered no. 30 and 25, 2% tapered no. 30 and 25 sequence was followed with a crown down manner according to manufacturers' recommendations. Apical stop preparation was checked with the hand usage of the last file and if there was no apical resistance sense aforementioned profile sequence was used backwards until sense of binding with hand usage. Each canal was irrigated with 2 mL of 2.5% NaOCl after each instrument for the rotary instrumentations.

All instruments were fixed in the root canals with acrylic resin. The apical 1 mm of each root tip was ground on wet sandpaper in order to expose the canal and the instrument at the WL. Care was taken not to grind and dislodge the instrument. Apical debris was removed with an ultrasonic cleaner (E15H, Elmasonic, Elma Hans Schmidbauer Co., Singen Germany) and the apical region of each tooth was examined under stereomicroscope (Leica M60, Leica Microsystems GmbH, Wetzlar, Germany) at a ×40 magnification [Figure 1]. The pixel counts of the apical images were used for calculations on Adobe Photoshop image analyzing program (CS2 Version 9.0; Adobe Systems, San Jose, CA, USA). The differences between the area of root canals and file tips were described as gap areas and calculated with subtraction of the file area from root canal area. The discrepancy between mean gap areas were analyzed using one-way analysis of variance test ($P = 0.05$). The smaller the gap area was considered the better adaptation.

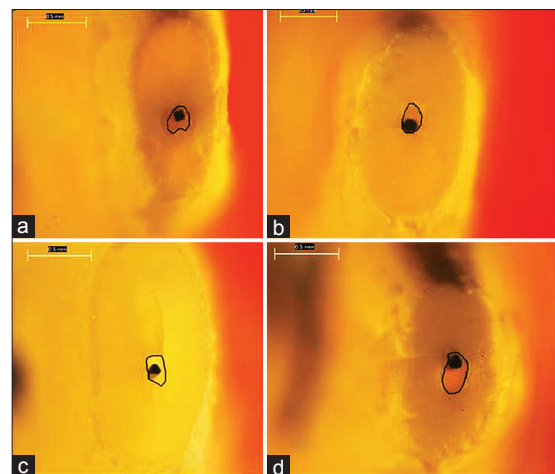


Figure 1: Samples from stereoscopic images, (a) K-file, (b) Hedstroemem, (c) ProFile, (d) ProTaper

RESULTS

Apical areas of the first files to bind and surrounding gap areas are shown in Table 1. There were big gap areas (78.23%) on apical image sections for total of the evaluated apical stereoscopic images. The mean gap areas and gap percentages for the instrument groups were as follows; K-file: 9999, 4 ± 3176 , 537 (76.53%), H-File: 12260, 6 ± 4795 (81.25%), ProFile: 10045, 5 ± 4409 , 256 (80.25%), ProTaper: 8883, 3 ± 3215 , 342 (74.91%). ProTaper showed the lowest mean gap area rate between evaluated instruments; however, the differences were not statistically significant ($P > 0.05$).

DISCUSSION

Mandibular incisors have a high incidence of isthmuses and are narrow in the proximal direction. Furthermore, apical root canals of mandibular incisors are oval and irregular shaped.^[18-21] This was the main reason that mandibular incisor teeth have been chosen in this study.

The root canal curvature controls the direction of the file and avoids a sufficient preparation of the apical part of the canal.^[22] Canal curvature beyond 10° is classified as moderate ($10-20^\circ$) or aggressive ($20-75^\circ$) according to Schneider.^[23] Therefore, teeth which have canal curvature more than 10° were excluded.

Preflaring of the coronal and middle-thirds of the root canal has been recommended prior to determining the initial file that binds.^[14,15] The dentine layer surrounding the apex and the root canal surfaces probably have been infected and must be instrumented after determination of the first binding file. However, the first file that binds at the root apex not properly reflects the diameter of the apical canal.^[5-7]

In an experimental study Weiger *et al.*^[22] used apex locator to find out WL in the determination of optimal apical preparation. However, apex locators don't perfectly determine the apical construction.^[24-26]

Table 1: Pixel values of the canal areas and apical gap areas surrounding the files

Instrument	No. of samples (n)	Mean canal area	Mean gap area	Standard deviation	Gap %
K-file	10	12135.6	9999.4	3176.537	76.52953
H-File	10	14315.9	12260.6	4795	81.24814
ProFile	10	11793.1	10045.5	4409.256	80.24583
ProTaper	10	10873.5	8883.3	3215.542	74.90974
Total	40	12279.53	10297.2	4005.879	78.23331

Some other experimental studies determined WL by subtracting 1 mm of the length of a small file whose tip was just visible at the apical foramen.^[15,27] We used this less time consuming technique for WL determination.

The aim of canal preparation is to widen the apical canal enough for irrigation and obturation procedures.^[12] However, widening and shaping processes are crucial steps for endodontic treatments because excess instrumentation can easily weaken the root and increase the risk of fracture as well as insufficient instrumentation can cause reinfection. The first binding file generally adapted to one side of the apical root canal, therefore apical stop may be formed only at one side. This one sided shelf may prevent the first binding file from apical movement, but it is uncertain that it can reduce leakage and material extrusion.^[28] Using this information, the decision should be made respecting shape and diameter of the apical foramen and root canal anatomy for a successful endodontic treatment. If the apical region is round, the first file that binds at the WL will most likely wear the entire canal perimeter with three more file diameters. When this region is oval the file will not simultaneously touch the whole diameter. Consequently, the objective of removing the infected dentin layer and preparing a round regular shaped apical stop might not be accomplished.^[28-34]

CONCLUSION

Considering the fact that the first file to bind frequently bound at one side of canal wall, the apical stop may be created only on one side. However, the results of this study have shown that even the first file binds the apical foramen did not reflect the apical diameter and the size of the file was relatively smaller than the exact size of apical foramen. Therefore, removing the infected dentine layer at the apical third of the root canal and preparing a round regular shaped apical stop might not be achieved without reshaping the apex. The similar and statistically insignificant results could be explained because of the non-circular and irregular shapes of the mandibular incisors' root canals and the discrepancy between root canals of the mandibular incisors.

REFERENCES

1. Armitage JP, Evans MC. The motile and tactic behaviour of *Pseudomonas aeruginosa* in anaerobic environments. *FEBS Lett* 1983;156:113-8.
2. Ando N, Hoshino E. Predominant obligate anaerobes invading the deep layers of root canal dentin. *Int Endod J* 1990;23:20-7.

3. Peters OA, Schönerberger K, Laib A. Effects of four Ni-Ti preparation techniques on root canal geometry assessed by micro computed tomography. *Int Endod J* 2001;34:221-30.
4. Nair PN, Sjögren U, Krey G, Kahnberg KE, Sundqvist G. Intraradicular bacteria and fungi in root-filled, asymptomatic human teeth with therapy-resistant periapical lesions: A long-term light and electron microscopic follow-up study. *J Endod* 1990;16:580-8.
5. Lussi A, Portmann P, Nussbächer U, Imwinkelried S, Grosrey J. Comparison of two devices for root canal cleansing by the noninstrumentation technology. *J Endod* 1999;25:9-13.
6. Hand RE, Smith ML, Harrison JW. Analysis of the effect of dilution on the necrotic tissue dissolution property of sodium hypochlorite. *J Endod* 1978;4:60-4.
7. Lumley PJ, Walmsley AD, Walton RE, Rippin JW. Cleaning of oval canals using ultrasonic or sonic instrumentation. *J Endod* 1993;19:453-7.
8. Jou YT, Karabucak B, Levin J, Liu D. Endodontic working width: Current concepts and techniques. *Dent Clin North Am* 2004;48:323-35.
9. Weine FS. The use of non-ISO-tapered instruments for canal flaring. *Compend Contin Educ Dent* 1996;17:651-6, 658.
10. Grande NM, Plotino G, Pecci R, Bedini R, Pameijer CH, Somma F. Micro-computerized tomographic analysis of radicular and canal morphology of premolars with long oval canals. *Oral Surg Oral Med Oral Pathol Oral Radiol Endod* 2008;106:e70-6.
11. Silveira LF, Martos J, Pintado LS, Teixeira RA, César Neto JB. Early flaring and crown-down shaping influences the first file bind to the canal apical third. *Oral Surg Oral Med Oral Pathol Oral Radiol Endod* 2008;106:e99-101.
12. Wu MK, Wesselink PR, Walton RE. Apical terminus location of root canal treatment procedures. *Oral Surg Oral Med Oral Pathol Oral Radiol Endod* 2000;89:99-103.
13. Martos J, Ferrer-Luque CM, González-Rodríguez MP, Castro LA. Topographical evaluation of the major apical foramen in permanent human teeth. *Int Endod J* 2009;42:329-34.
14. Tan BT, Messer HH. The effect of instrument type and preflaring on apical file size determination. *Int Endod J* 2002;35:752-8.
15. Contreras MA, Zinman EH, Kaplan SK. Comparison of the first file that fits at the apex, before and after early flaring. *J Endod* 2001;27:113-6.
16. Senia ES. Canal diameter: The forgotten dimension. *Dent Today* 2001;20:58-62.
17. Peters OA. Current challenges and concepts in the preparation of root canal systems: A review. *J Endod* 2004;30:559-67.
18. Boruah LC, Bhuyan AC. Morphologic characteristics of root canal of mandibular incisors in North-East Indian population: An *in vitro* study. *J Conserv Dent* 2011;14:346-50.
19. Huang DM, Hao YQ, Luo SG, Jia LH, Zhou XD. Morphology of cross-sectioned root canal in Chinese mandibular permanent incisors. *Sichuan Da Xue Xue Bao Yi Xue Ban* 2006;37:916-8.
20. Kartal N, Yanikoğlu FC. Root canal morphology of mandibular incisors. *J Endod* 1992;18:562-4.
21. Mauger MJ, Schindler WG, Walker WA 3rd. An evaluation of canal morphology at different levels of root resection in mandibular incisors. *J Endod* 1998;24:607-9.
22. Weiger R, Bartha T, Kalwitzki M, Löst C. A clinical method to determine the optimal apical preparation size. Part I. *Oral Surg Oral Med Oral Pathol Oral Radiol Endod* 2006;102:686-91.
23. Schneider SW. A comparison of canal preparations in straight and curved root canals. *Oral Surg Oral Med Oral Pathol* 1971;32:271-5.
24. Vasconcelos BC, Matos Lde A, Pinheiro-Júnior EC, Menezes AS, Vivacqua-Gomes N. *Ex vivo* accuracy of three electronic apex locators using different apical file sizes. *Braz Dent J* 2012;23:199-204.
25. Comin Chiaramonti L, Menini M, Cavalleri G. A comparison between two fourth generation apex locators. *Minerva Stomatol* 2012;61:183-96.
26. Mancini M, Felici R, Conte G, Costantini M, Cianconi L. Accuracy of three electronic apex locators in anterior and posterior teeth: An *ex vivo* study. *J Endod* 2011;37:684-7.
27. Wu MK, Barkis D, Roris A, Wesselink PR. Does the first file to bind correspond to the diameter of the canal in the apical region? *Int Endod J* 2002;35:264-7.
28. Kastáková A, Wu MK, Wesselink PR. An *in vitro* experiment on the effect of an attempt to create an apical matrix during root canal preparation on coronal leakage and material extrusion. *Oral Surg Oral Med Oral Pathol Oral Radiol Endod* 2001;91:462-7.
29. Usman N, Baumgartner JC, Marshall JG. Influence of instrument size on root canal debridement. *J Endod* 2004;30:110-2.
30. Rollison S, Barnett F, Stevens RH. Efficacy of bacterial removal from instrumented root canals *in vitro* related to instrumentation technique and size. *Oral Surg Oral Med Oral Pathol Oral Radiol Endod* 2002;94:366-71.
31. Shuping GB, Orstavik D, Sigurdsson A, Trope M. Reduction of intracanal bacteria using nickel-titanium rotary instrumentation and various medications. *J Endod* 2000;26:751-5.
32. Dalton BC, Orstavik D, Phillips C, Pettiette M, Trope M. Bacterial reduction with nickel-titanium rotary instrumentation. *J Endod* 1998;24:763-7.
33. Iqbal MK, Ku J. Instrumentation and obturation of the apical third of root canals: Addressing the forgotten dimension. *Compend Contin Educ Dent* 2007;28:314-20.
34. de Oliveira LD, Carvalho CA, Valera MC, Koga-Ito CY, Jorge AO. Diffusion ability of endotoxin through dentinal tubules. *Braz Oral Res* 2005;19:5-10.

Access this article online

Quick Response Code:



Website:
www.eurjdent.com

Source of Support: Nil.
Conflict of Interest: None declared