

Case Report

Endoscopic ultrasound diagnosis of hydatid membranes in nonobstructive biliary system

Sharad Chandra, Urvashi Chandra, Rajesh Puri¹

Department of Gastroenterology, Meghraj Memorial Hospital, Jhansi, Uttar Pradesh, ¹Department of Gastroenterology, Medicity Hospital, Gurgaon, Haryana, India

Abstract

Biliary communication in hepatic hydatid cyst is reported in 1–20% of patients. These patients present with fever (70–90%), right upper quadrant pain (80%), cholangitis (20–37%), acute pancreatitis (rare), liver abscess, and septicemia. Diagnosis of biliary rupture is on abdominal ultrasound, computerized tomography, and/or magnetic resonance imaging demonstration of hydatid membranes. We report a case of rupture hydatid cyst where diagnosis was on endosonographic findings and the patient had normal caliber common bile duct.

Key words

Biliary communication, endoscopic ultrasound, hydatid membranes

Introduction

Hepatic hydatidosis with biliary rupture is an unusual but serious complication of echinococcosis.^[1] We present a case of biliary communication of hydatid cyst liver where hydatid membranes were documented in common bile duct (CBD) on endoscopic ultrasound (EUS). Interestingly, the patient had nonobstructed biliary system and nonspecific liver function test abnormalities.

Case Report

A 50-year-old female presented with 3 days history of upper abdominal pain with recurrent vomiting; there was no associated fever or jaundice. In background, there was history of excision of hepatic hydatid cyst with cholecystectomy 11 years back.

Investigation presently showed serum bilirubin 2.02 mg% with direct 1.12 mg% and indirect 0.90 mg%, serum

glutamic-oxaloacetic transaminase 78.2 IU/L (0–32), serum glutamic pyruvic transaminase 64.63 IU/L (0–33), alk PO₄ 106 IU/L (80–250), serum amylase 37.95 SU/L (<50), and complete blood count was normal. Ultrasound done showed 68 mm × 48 mm × 39 mm cystic mass in right lobe of liver with multiple septation, CBD was normal caliber 7.5 mm (postcholecystectomy), and there was no IHBRD.

The possibility of CBD stone or hydatid biliary rupture was considered. EUS evaluation was done which showed normal caliber CBD with coiled linear echogenic shadows with intervening anechoic area suggestive of membranes [Figure 1 and Supplementary Video 1]. Endoscopic retrograde cholangiopancreatography (ERCP) showed rounded filling defects resembling stones due to coiled membranes in CBD [Figure 2]. Sphincterotomy retrieval of fleshy hydatid membranes [Figure 3] with stent placement was done. No obvious communication with cyst cavity was seen; however, occlusion cholangiogram was not done to avoid the risk of infection in cyst cavity. The patient was started on albendazole her symptoms improved thereafter she was discharged.

Address for correspondence:

Dr. Sharad Chandra, Department of Gastroenterology, Meghraj Memorial Hospital, 95, Civil Line, Jhansi, Uttar Pradesh, India.
E-mail: sharadurvashi@gmail.com

Video Available on: www.jdeonline.in

Access this article online

Website:

www.jdeonline.in

DOI:

10.4103/0976-5042.202822

Quick Response Code



This is an open access article distributed under the terms of the Creative Commons Attribution-NonCommercial-ShareAlike 3.0 License, which allows others to remix, tweak, and build upon the work non-commercially, as long as the author is credited and the new creations are licensed under the identical terms.

For reprints contact: reprints@medknow.com

How to cite this article: Chandra S, Chandra U, Puri R. Endoscopic ultrasound diagnosis of hydatid membranes in nonobstructive biliary system. *J Dig Endosc* 2017;8:44-5.

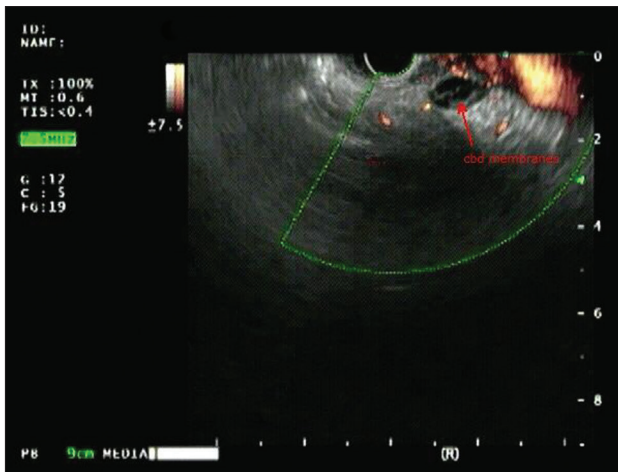


Figure 1: Linear endoscopic ultrasound showing membranes in common bile duct

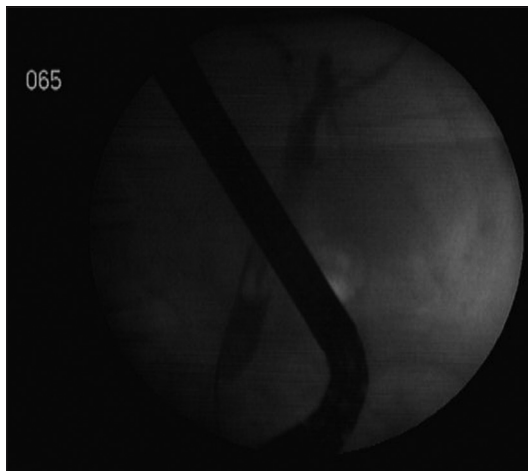


Figure 2: Endoscopic retrograde cholangiopancreatography cholangiogram showing filling defect in common bile duct

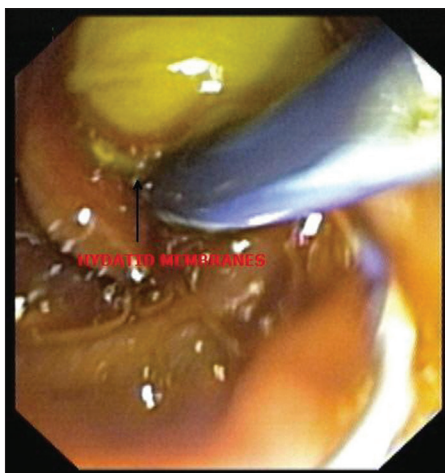


Figure 3: Hydatid membranes extracted from common bile duct

Discussion

Biliary communication is serious complication of echinococcosis.^[1] ERCP with sphincterotomy, membrane clearance, and stent placement has been recommended for managing biliary communication of hepatic hydatid cyst.^[2] ERCP is indicated if the patient has obstructed biliary system or is symptomatic with membranes documented in CBD on ultrasound, computed tomography (CT) or magnetic resonance imaging (MRI).^[2] EUS when available can demonstrate hydatid membranes.^[3-5] Findings reported in bile duct are of echogenic floating membranes, echogenic material with septated appearance or multilayered circular gut wall like image. The present case showed linear echogenic shadows coiled in CBD. In previously reported cases,^[3-5] EUS findings of hydatid membranes were reported where biliary system was dilated and there was definitive indication for therapeutic ERCP even on ultrasound. The present case diagnosis and therapy was based on EUS findings which were done to exclude CBD stone or hydatid membranes. EUS possibly scores over CT scan and MRI, especially in nonobstructive system and is available in emergency in patients presenting with cholangitis can be followed by immediate ERCP.

Interestingly patient despite symptoms had nonobstructed biliary system possibly due to intermittent obstruction. Liver functional abnormalities seen were nonspecific, suggesting lower threshold for evaluation for suspected biliary communication in symptomatic patients with large hydatid cyst liver before life-threatening complications such as cholangitis and pancreatitis develops.

Financial support and sponsorship

Nil.

Conflicts of interest

There are no conflicts of interest.

References

1. Manouras A, Genetzakis M, Antonakis PT, Lagoudianakis E, Pattas M, Papadima A, *et al*. Endoscopic management of a relapsing hepatic hydatid cyst with intrabiliary rupture: A case report and review of the literature. *Can J Gastroenterol* 2007;21:249-53.
2. Simsek H, Ozaslan E, Sayek I, Savas C, Abbasoglu O, Soylu AR, *et al*. Diagnostic and therapeutic ERCP in hepatic hydatid disease. *Gastrointest Endosc* 2003;58:384-9.
3. Sharma M, Somasundaram A, Pathak A, Simon EG, Cloa MM. Endoscopic ultrasound in hepatobiliary hydatid disease. *Endoscopy* 2010;42 Suppl 2:E56-7.
4. Azzolini F, Camellini L, Menozzi G, Sassatelli R. Endoscopic ultrasound image of hydatid membranes in the common bile duct. *Dig Liver Dis* 2012;44:e19.
5. Rana SS, Bhasin DK, Rao C. Unusual cause of biliary obstruction revealed by endoscopic ultrasound and peroral cholangioscopy. *Clin Gastroenterol Hepatol* 2013;11:e58.