

Case Report

Successful closure of chronic, nonhealing tubercular esophagobronchial fistula with an over-the-scope clip

Surinder Singh Rana, Harshal Mandavdhare, Vishal Sharma, Ravi Sharma, Lovneet Dhalaria, Anmol Bhatia, Rajesh Gupta¹, Usha Dutta

Departments of Gastroenterology and ¹Surgery, Post Graduate Institute of Medical Education and Research, Chandigarh, India

Abstract

Esophagobronchial fistula is an uncommon complication of esophageal or mediastinal tuberculosis. A 35-year-old man, a known case of esophageal tuberculosis, who had received 9 months of antitubercular therapy (ATT) presented with persistent cough. He had previously been detected to have an esophagobronchial fistula for which multiple hemoclips had been applied elsewhere, but the fistula persisted. A fistulous communication between the esophagus and the left main bronchus was successfully closed with the help of over-the-scope-clip (OTSC) system. The present case is unique as patient developed fistulous communication during the treatment with ATT and it persisted despite successful treatment of esophageal tuberculosis. Moreover, this refractory fistula could be successfully closed with OTSC.

Key words

Cough, dysphagia, esophagus, fistula, tuberculosis

Introduction

Esophageal tuberculosis is a rare disease accounting for <1% of cases of tuberculosis.^[1,2] Most commonly, it occurs due to secondary extension of disease process from the adjacent mediastinal lymph nodes.^[1-3] Bronchoesophageal fistula (BEF)/mediastinoesophageal fistula is a rare but potentially serious complication of esophageal/mediastinal tuberculosis.^[4-6] Most of the reported cases of BEF/mediastinoesophageal fistula have resolved with antitubercular therapy (ATT) alone. The traditional treatment of BEF has been surgery with few reports of successful closure with conservative management including nasogastric/nasojejunal feeding.^[4-6] Various endoscopic options such as

hemoclips, fully covered metallic stents, and fibrin glue have also been used for refractory BEF.^[7-9] Here, we present a case of posttubercular BEF successfully closed with OTSC after a failed attempt to close it with multiple hemoclips.

Case Report

A 35-year-old male presented with cough of 18 months duration. His cough used to get worsened with ingestion of liquids and had been treated with oral antibiotics multiple times elsewhere. He was treated for esophageal tuberculosis 2 years ago and had taken 9 months of ATT. His cough started during treatment and endoscopy done elsewhere revealed multiple traction diverticulae in mid-esophagus and a fistulous opening in mid-esophagus. His ATT was continued and a nasojejunal tube was placed for enteral feeding. In spite of these measures, the fistula did not heal. Thereafter, multiple hemoclips were applied to close the fistula elsewhere but the fistula persisted. Upper

Address for correspondence:

Dr. Surinder Singh Rana, Department of Gastroenterology, Post Graduate Institute of Medical Education and Research, Chandigarh - 160 012, India.
E-mail: drsurinderrana@yahoo.co.in

Access this article online

Website: www.jdeonline.in	Quick Response Code 
DOI: 10.4103/0976-5042.202820	

This is an open access article distributed under the terms of the Creative Commons Attribution-NonCommercial-ShareAlike 3.0 License, which allows others to remix, tweak, and build upon the work non-commercially, as long as the author is credited and the new creations are licensed under the identical terms.

For reprints contact: reprints@medknow.com

How to cite this article: Rana SS, Mandavdhare H, Sharma V, Sharma R, Dhalaria L, Bhatia A, *et al.* Successful closure of chronic, nonhealing tubercular esophagobronchial fistula with an over-the-scope clip. *J Dig Endosc* 2017;8:33-5.

gastrointestinal endoscopy at our center revealed a fistulous opening in mid-esophagus [Figure 1]. Contrast study of the esophagus revealed the presence of a fistulous communication between the esophagus and left bronchus [Figure 2]. No significant mediastinal lymphadenopathy was observed on contrast-enhanced computed tomography. The epithelial lining of the fistulous opening was denuded using Argon plasma coagulation [Figure 3] and using a twin grasper to approximate the edges and withdrawing them into the cap, the fistula was closed using over-the-scope-clip (OTSC) system (Ovesco Endoscopy AG, Tübingen, Germany) [Figure 4]. Contrast study of the esophagus done a week later revealed the presence of OTSC at the fistulous site with no leakage of the contrast [Figure 5]. Thereafter, the patient has been asymptomatic over 6 weeks of follow-up.

process from adjacent mediastinal lymph nodes. Primary involvement is very rare.^[1-3] The common presenting symptoms are dysphagia with or without constitutional symptoms. Unusual symptoms such as cough on swallowing liquids due to fistulous communication between the esophagus and respiratory tract and hematemesis due to an aorto-esophageal fistula can be occasionally seen.^[1-3]

Fistulous communications with respiratory tract are most commonly due to esophageal malignancy, and benign causes of fistula include tuberculosis, trauma, iatrogenic, corrosive ingestion, poison, and inhalation burns.^[4,7] The traditional treatment of BEF has been surgery with few reports of successful closure with conservative management including nasogastric/nasojejunal feeding.^[4-6] With advancement in endoscopic therapy, various endoscopic management options have been used in treatment of fistulae including self-expanding metallic stents (SEMS), mechanical closure with through the scope hemoclips, sealants, endoscopic ligation with banding devices, and the recent development of OTSC.^[8-12]

Discussion

Esophageal tuberculosis is usually due to secondary involvement of the esophagus from extension of disease

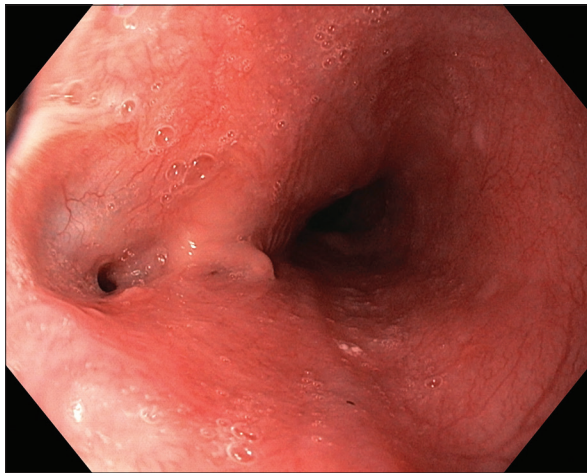


Figure 1: Endoscopy: fistulous opening in mid-esophagus

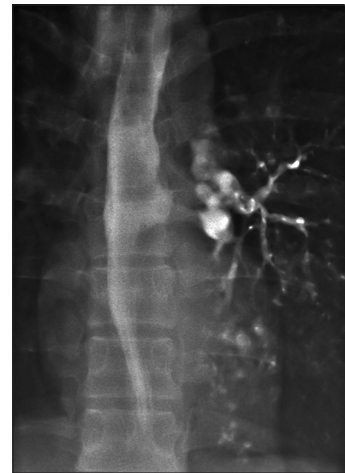

Figure 2: Contrast study reveals fistulous communication between mid-esophagus and left bronchus

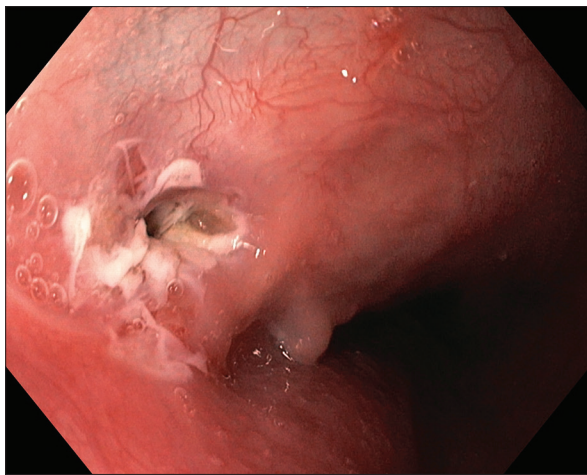


Figure 3: The epithelial lining of the fistulous opening denuded using Argon plasma coagulation

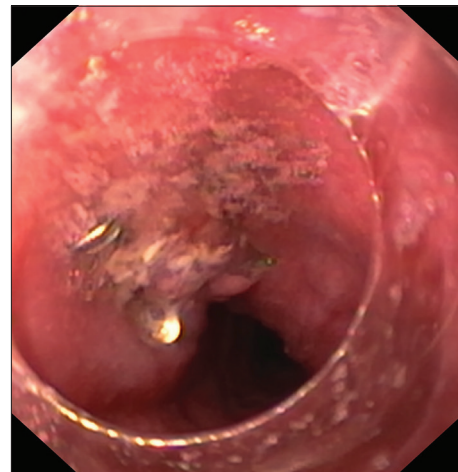


Figure 4: Over-the-scope-clip applied to close the fistula

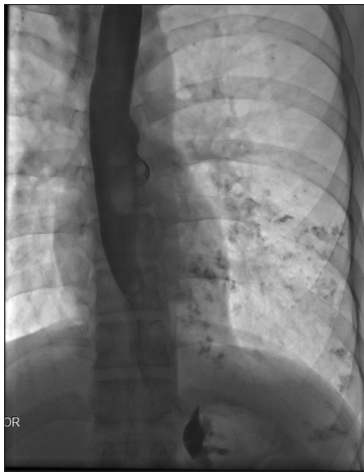

Figure 5: Contrast study reveals closure of the fistula. Over-the-scope-clip is also noted

The OTSC system (Ovesco Endoscopy AG, Tubingen, Germany) is a biocompatible, elastic nitinol endoscopic clip which aims at having better capture of tissue around the leaks/ulcers and therefore has been shown to be effective in management of gastrointestinal perforations, leaks, and bleeding. The present case is unique because it reports the use of a new treatment (OVESCO clip) to close a fistula resulting from tubercular involvement of esophagus which had failed to respond to ATT and placement of hemoclips.

Financial support and sponsorship

Nil.

Conflicts of interest

There are no conflicts of interest.

References

1. Devarbhavi HC, Alvares JF, Radhikadevi M. Esophageal tuberculosis associated with esophagotracheal or esophagomediastinal fistula: Report of 10 cases. *Gastrointest Endosc* 2003;57:588-92.
2. Rana SS, Bhasin DK, Rao C, Srinivasan R, Singh K. Tuberculosis presenting as dysphagia: Clinical, endoscopic, radiological and endosonographic features. *Endosc Ultrasound* 2013;2:92-5.
3. Jain SK, Jain S, Jain M, Yaduvanshi A. Esophageal tuberculosis: Is it so rare? Report of 12 cases and review of the literature. *Am J Gastroenterol* 2002;97:287-91.
4. Patel S, Abraham VJ, Mathur RM, Devgarha S, Yadav A. Acquired spontaneous bronchoesophageal fistula in an adult. *Egypt J Chest Dis Tuberc* 2015;64:209-11.
5. Kim HK, Choi YS, Kim K, Kim J, Shim YM. Long-term results of surgical treatment in benign bronchoesophageal fistula. *J Thorac Cardiovasc Surg* 2007;134:411-4.
6. Lado Lado FL, Golpe Gómez A, Cabarcos Ortíz de Barrón A, Antúnez López JR. Bronchoesophageal fistulae secondary to tuberculosis. *Respiration* 2002;69:362-5.
7. Ahn JY, Jung HY, Choi JY, Kim MY, Lee JH, Choi KS, *et al.* Benign bronchoesophageal fistula in adults: Endoscopic closure as primary treatment. *Gut Liver* 2010;4:508-13.
8. van Boeckel PG, Dua KS, Weusten BL, Schmits RJ, Surapaneni N, Timmer R, *et al.* Fully covered self-expandable metal stents (SEMS), partially covered SEMS and self-expandable plastic stents for the treatment of benign esophageal ruptures and anastomotic leaks. *BMC Gastroenterol* 2012;12:19.
9. Fischer A, Schrag HJ, Goos M, von Dobschuetz E, Hopt UT. Nonoperative treatment of four esophageal perforations with hemostatic clips. *Dis Esophagus* 2007;20:444-8.
10. Voermans RP, van Berge Henegouwen MI, Bemelman WA, Fockens P. Novel over-the-scope-clip system for gastrotomy closure in natural orifice transluminal endoscopic surgery (NOTES): An *ex vivo* comparison study. *Endoscopy* 2009;41:1052-5.
11. Baron TH, Song LM, Ross A, Tokar JL, Irani S, Kozarek RA. Use of an over-the-scope clipping device: Multicenter retrospective results of the first U.S. experience (with videos). *Gastrointest Endosc* 2012;76:202-8.
12. Haito-Chavez Y, Law JK, Kratt T, Arezzo A, Verra M, Morino M, *et al.* International multicenter experience with an over-the-scope clipping device for endoscopic management of GI defects (with video). *Gastrointest Endosc* 2014;80:610-22.